

Triple structural mosaicism of chromosome 18 in a child with MR/MCA syndrome and abnormal skin pigmentation

E Bocian, T Mazurczak, E Buława, H Stańczak, G Rowicka

Abstract

A case of triple mosaicism involving chromosome 18 is described in a girl with abnormal skin pigmentation similar to hypomelanosis of Ito. The karyotype is 46,XX,-18,+del(18)(p11.23→pter)/46,XX,-18,+idic(18)(p11.23)/46,XX,-18,+r(18). The patient displays some clinical features of monosomy 18p and a few signs of trisomy 18q. Our case illustrates a non-random association of chromosomal mosaicism with abnormal skin pigmentation.

(*J Med Genet* 1993;30:614-15)

The most common form of chromosomal mosaicism is aneuploidy arising as a consequence of postzygotic chromosome non-disjunction. Other forms of mosaicism which appear very rarely are those with structural abnormalities and in such cases a normal cell line is usually present. A non-random association has been suggested between a number of mosaic karyotypes and abnormal skin pigmentation.¹⁻³ It has been suggested that evaluation for chromosomal mosaicism or chimerism should be made when anomalous pigmentation is observed, especially when it follows Blaschko's lines, as this will provide useful information regarding the association between the skin fibroblast karyotype and pigmentary abnormalities.

We report an 8 month old girl clinically suspected to have hypomelanosis of Ito (HI), with no normal cell line, but with mosaicism for three abnormal cell lines which may have a common origin.

Case report

The proband, a female infant, born after an uncomplicated pregnancy, is the second child of healthy, unrelated parents, a 26 year old father and a 25 year old mother. The older sister is healthy. Birth weight was 3750 g, length 57 cm, and Apgar scores were 8. Linear and patchy hypopigmentation which followed Blaschko's lines on the trunk and a hyperpigmented patch on the buttocks have been observed since birth (fig 1). Clinical examination at 8 months showed moderate hypotonia and mild microcephaly (head circumference -2 SD). She had many dysmorphic facial features (fig 1) including a round, coarse, asymmetrical face with disproportionate parameters (length -3 SD, width +5 SD), hypotelorism, epicanthus, broad and flattened nasal bridge, low set, dysplastic ears, micrognathia, high arched palate, macrostomia, and short neck. Both hands had simian creases. The left leg was shorter by 5 cm than the right. Psychomotor development was delayed (Burnet-Lesine square 48).

Clinical investigations (electrocardiogram, cranial and abdominal ultrasound) were normal and the kidneys, bladder, liver, spleen, and pancreas showed no anomalies. Radiographic assessment showed no skull, vertebral, pelvic, or thoracic anomalies. EEG was normal. There were no signs of deafness.

Chromosome analysis using routine methods was performed on peripheral blood lymphocytes and fibroblasts from biopsies of light and normal coloured skin areas. Both tissues showed a mosaic karyotype with three different structural abnormalities of chromosome 18: 46,XX,del(18)(p11.23→pter)/46,XX,idic(18)(p11.23)/46,XX,r(18)?(p11.23q23) (fig 2). The percentage distribution of the three lines in the tissues examined are shown in the table. The predominant karyotype was the deletion of 18p. Karyotypes of the proband's parents were normal.

Discussion

The severity of the phenotypic effects of chromosomal mosaicism depends on the nature and extent of the mosaicism. The proportion of cell lines with different structural chromosome abnormalities is also important. In our patient 80% of cells have a deletion of 18p (p11.23→pter) and approximately 10% of cells have isochromosome 18q, effectively making this cell line 18q trisomic. Thus, we would expect the proband to show features typical of monosomy 18p and trisomy 18q. Our patient's

Department of
Genetics, National
Research Institute of
Mother and Child,
Kasprzaka 17A, 01-211
Warsaw, Poland.
E Bocian
T Mazurczak
E Buława
H Stańczak

Department of
Paediatrics, National
Research Institute of
Mother and Child,
Kasprzaka 17A, 01-211
Warsaw, Poland.
G Rowicka

Correspondence to
Dr Bocian.

Received 24 October 1992.
Revised version accepted
27 November 1992.

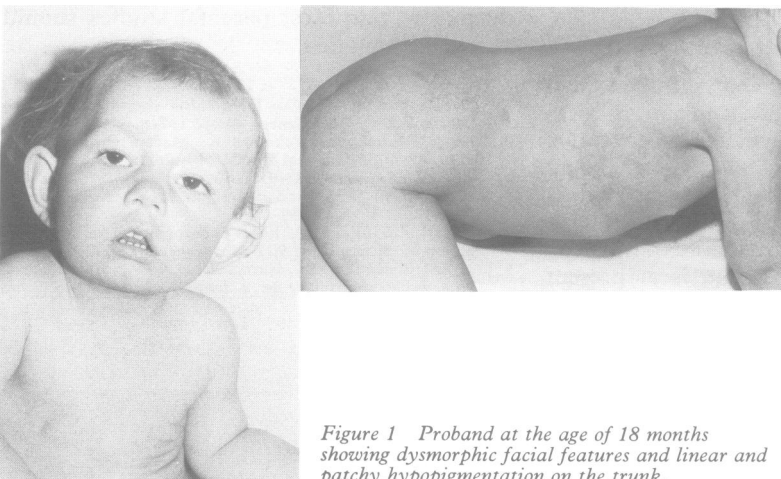


Figure 1 Proband at the age of 18 months showing dysmorphic facial features and linear and patchy hypopigmentation on the trunk.

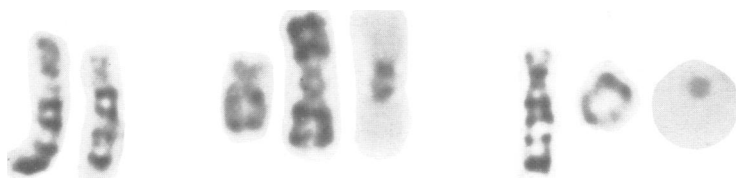


Figure 2 Chromosome 18 structural abnormalities found in three cell lines. From the left: *del(18p)*, *idic(18)*, and *r(18)*. C banding showed two centromeres in the isochromosome. They were both active in some cells but in the majority of cells one centromere was inactivated.

genotype-phenotype correlation is difficult to evaluate. She displays characteristic features of 18p monosomy including depressed nasal bridge, round face, short neck, wide mouth, small head circumference, and micrognathia. We observed no signs of prenatal growth retardation which is common in trisomy 18. Lack of other severe clinical manifestations of trisomy 18q may be related to the fact that the trisomy was present only in 10% of cells.

Abnormal skin pigmentation as a feature of the phenotype in chromosomal mosaicism has been previously reported.³⁻⁵ Donnai *et al*¹ and others²³ have shown that many patients with hypomelanosis of Ito are mosaics for chromosomal abnormalities. Abnormal skin pigmentation following Blaschko's lines and asymmetry in leg length are the only typical features of HI which were observed in our proband. Her other clinical features, which also occur in hypomelanosis of Ito, are typical of chromosomal abnormalities. As HI is a heterogeneous group of disorders with the common factor of mosaicism, clinical manifestation may vary, depending on the nature of the mosaicism, and it is very difficult on clinical grounds to make a precise diagnosis in an individual case.^{6,7}

Biopsies from normally pigmented and light areas of the skin were taken because of indications of differences in the karyotype.⁵ There were no karyotypic differences in the different areas of pigmentation in our case. Similar conclusions were reported by Thomas *et al*.³

To the best of our knowledge no other cases of similar mosaicism for three structural aberrations of chromosome 18 have been reported. All other reported mosaics with structural abnormalities (including isochromosome, ring, or deletion), either for chromosome 18 or for

Percentage distribution of three abnormal cell lines with respect to tissue examined.

Tissue	<i>del(18p)</i>	<i>idic(18)</i>	<i>r(18)</i>
Blood lymphocytes	89	7	4
Light skin	91	5	4
Normal skin	86	10	4

other chromosomes, were cytogenetically different from our case.⁴⁸⁻¹⁰

Technically it was difficult to localise precisely the breakpoints in the isodicentric chromosome 18 and it was not possible to assess the breakpoint in the ring chromosome. It would be reasonable to assume that the three identified abnormalities have the same breakpoints on 18p. However, it is difficult to explain how these aberrations could arise. An explanation of our findings could be that the three cell lines arose as two independent events. In such a case, a three strand break model as proposed by Madan *et al*⁹ explains the origin of isodicentrics and rings from the previously deleted chromosome. The fact that the cell line with 18p deletion predominates is compatible with such an explanation.

The presence of chromosome abnormalities in all tissues examined suggests their common origin. The proportion of the three cell lines could be the result of instability of isodicentric and ring chromosomes and the loss of cells with these abnormalities during development. It is not consistent, however, with the observations of other authors.^{48,9} In the case reported by Madan *et al*⁹ isodicentrics were present in 64% and ring chromosomes in 36% of lymphocytes. Our case is one more example confirming non-random association of chromosomal mosaicism with abnormal skin pigmentation.

We would like to thank Mrs M Ferguson Smith (Addenbrooke's Hospital, Cambridge) and Dr D Donnai (St Mary's Hospital, Manchester) for their comments and helpful advice in preparing this manuscript.

- 1 Donnai D, Read AP, McKeown C, Andrews T. Hypomelanosis of Ito: a manifestation of mosaicism or chimerism. *J Med Genet* 1988;25:809-18.
- 2 Flannery D. Invited editorial comment: pigmentary dysplasia, hypomelanosis of Ito, and genetic mosaicism. *Am J Med Genet* 1990;35:18-21.
- 3 Thomas IT, Frias JL, Cantu ES, Lafer CZ, Flannery DB, Graham JG. Association of pigmentary anomalies with chromosomal and genetic mosaicism and chimerism. *Am J Hum Genet* 1989;45:193-205.
- 4 Cantu E, Thomas I, Frias J. Unusual cytogenetic mosaicism involving chromosome 14 abnormalities in a child with an MR/MCA syndrome and abnormal pigmentation. *Clin Genet* 1989;36:189-95.
- 5 Fujimoto A, Lin M, Korula S, Wilson M. Trisomy 14 mosaicism with t(14;15)(q11;p11) in offspring of a balanced translocation carrier mother. *Am J Hum Genet* 1985;22:333-42.
- 6 Editorial. Hypomelanosis of Ito. *Lancet* 1992;339:651-2.
- 7 Donnai D, Read AP. Hypomelanosis of Ito. *Lancet* 1992;339:819-20.
- 8 Hutchinson-Cole H, Aleck K, Davis JR, Veomett IC, Hanck L. Mosaicism for ring and isopseudodicentric chromosome 13. *Clin Genet* 1986;29:88-91.
- 9 Madan K, Vlasveld L, Barth P. Ring-18 and isopseudodicentric-18 in the same child: a hypothesis to account for common origin. *Ann Genet (Paris)* 1981;24:12-16.
- 10 Sutton S, Ridler M. Prenatal detection of monosomy 18p and trisomy 18q mosaicism with unexpected fetal phenotype. *J Med Genet* 1985;23:258-9.