
Original articles

α thalassaemia/mental retardation syndrome (non-deletional type): report of a family supporting X linked inheritance

T R P Cole, A May, H E Hughes

Abstract

In 1990 the existence of an X linked form of the α thalassaemia/mental retardation syndrome was postulated after the description of six isolated cases who were all cytogenetically male. The segregation pattern in the family described here supports X linked inheritance. The clinical details of our two patients are remarkably similar to the previously delineated phenotype. In addition, renal anomalies were identified in one patient, but their significance will remain uncertain until further cases have been assessed. Affected subjects could be identified by the presence of Hb H inclusions, and were also noted to have abnormalities of several haematological indices. Examination of blood from obligatory carriers in this family suggests that Hb H inclusions are not an invariable finding and that haematological indices appear to be unaffected by the condition in female heterozygotes.

In 1981 Weatherall *et al*¹ described three males with severe mental retardation and haemoglobin H disease. In 1990 Wilkie *et al*² reviewed these three cases and described a further 10 with Hb H or α thalassaemia trait. Five of these subjects exhibited a separate and distinctive phenotype with severe retardation,

Institute of Medical Genetics, University Hospital of Wales, Heath Park, Cardiff CF4 4XN.
T R P Cole, H E Hughes

Department of Haematology, University Hospital of Wales, Heath Park, Cardiff CF4 4XN.
A May

Correspondence to Dr Cole.

Received for publication 5 March 1991.
Revised version accepted for publication 2 July 1991.

characteristic facies, short stature, microcephaly, hypogenitalism, and a 46,XY karyotype without an identifiable molecular deletion in the α globin gene. As all cases were cytogenetically male, X linked inheritance was postulated. Here we report an affected uncle and nephew which supports this mode of inheritance (fig 1).

Case reports

CASE 1

The male proband (IV:2) (fig 2) was born at 37 weeks' gestation by spontaneous vaginal delivery. Birth weight, length, and head circumference (OFC) were 2750 g, 50.8 cm, and 33 cm respectively. Two hours after birth he was transferred to a special care baby unit because of hypothermia and intercostal recession. Unusual facial appearance, patent ductus arteriosus, hypogenitalism, and poor feeding were documented. Full oral feeds and weight gain were only established at 16 days of age. During infancy and childhood severe mental retardation and growth failure were noted. Febrile convulsions secondary to upper respiratory and urinary tract infections occurred during childhood. At the age of 7 years height, weight, and OFC were all less than 3 SD below the mean. At 97 months, all Griffiths developmental subscales were under 14 months. Sitting without support was achieved at 2 years and walking with a frame at 12 years. Neither bladder nor bowel control has been attained. Now at the age of 13 years he can finger feed himself and has some control with a spoon. Rumination and recurrent vomiting is induced by putting his hand down his throat. He has no recognisable vocabulary but can make some physical gestures which are interpretable by family members.

At the age of 12 years the following facial features were noted: unswept frontal hairline, epicanthic

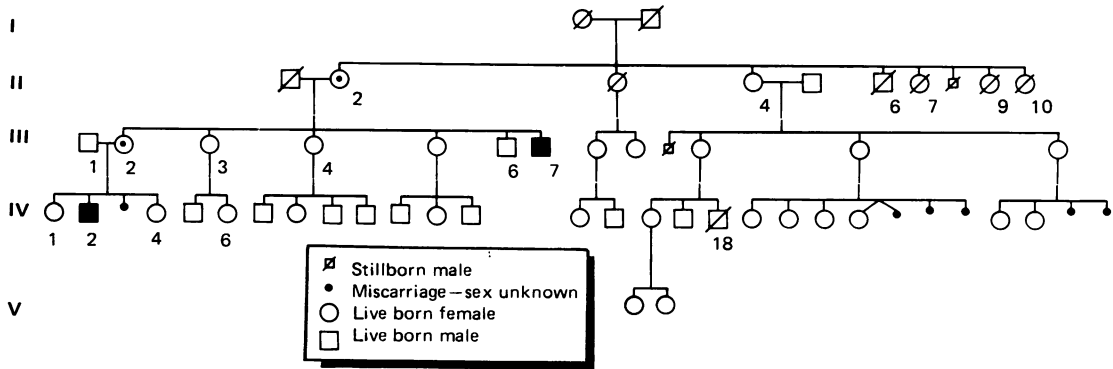


Figure 1 Pedigree. II-6 died at 70 years, II-7 died at 6 months (measles), II-9 and II-10 died in infancy (cause not known), III-18 died at 8 years (congenital heart disease).

folds, broad, depressed nasal bridge, short, triangular nose with anteverted nares, wide mouth with prominent lower lip, and large, widely spaced central incisors. In addition he has bilateral undescended testes and thin hypotonic limbs with absent reflexes in the legs.

The following investigations have all been normal: lymphocyte and fibroblast karyotypes (46,XY), urinary and blood amino acids, urinary mucopolysaccharides, blood ammonia, serum cortisol, and growth hormone levels. His bone age was 4.5 years at 11 years of age. An IVP showed right sided renal agenesis with a left sided hydronephrosis and hydrourter.

Recurrent anaemia, with Hb values as low as 7.6 g/dl, and hypochromic blood films have been

recorded. These values were attributed to iron deficiency and the MCV and MCH were usually reduced, the lowest recorded values being 62 fl (range 77 to 95 fl) and 17.2 pg (25 to 33 pg) respectively.

CASE 2 (FIGS 3 AND 4)

Case 2 (III-7) was identified when a family pedigree was obtained (fig 1). His mental retardation had previously been attributed to cerebral palsy. He was

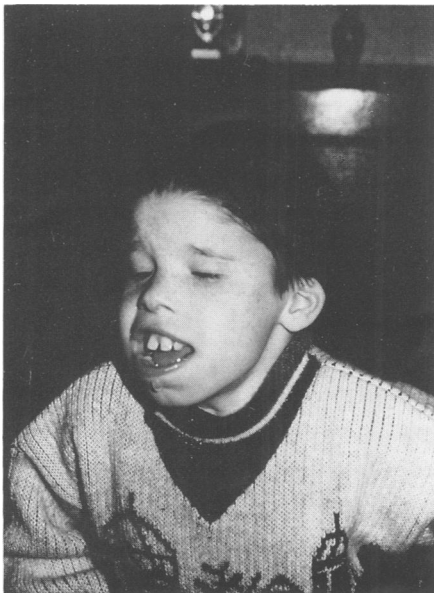


Figure 2 Proband IV-2 aged 13 years.

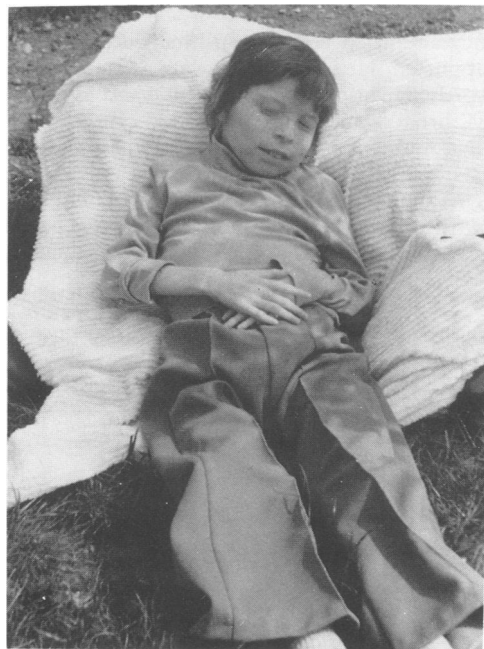

Figure 3 III-7 aged 12 years. Features include microcephaly, triangular shaped nose with anteverted nares, wide mouth with prominent lower lip and large central incisors.

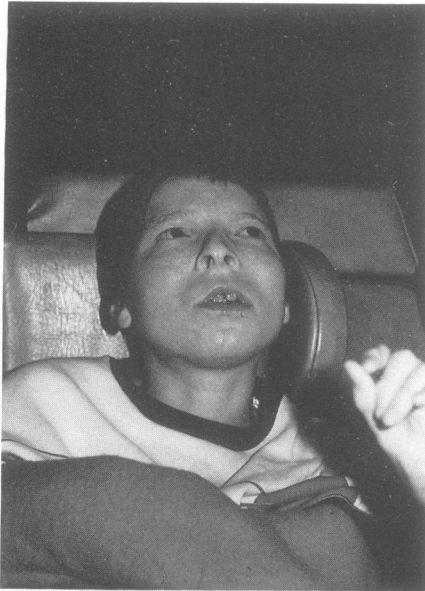

Figure 4 III-7 aged 25 years.

born by spontaneous vaginal delivery but according to parental report "he was stuck" during delivery. His birth weight was 2730 g. At 1 year of age he developed convulsions which have persisted. Severe mental and growth retardation was apparent from infancy and at 25 years he still has difficulty sitting unsupported. He is unable to walk or stand and has no words. He also tends to put his hand to the back of his throat to induce vomiting.

On examination he was short and thin with an OFC of 48.6 cm (-4.4 SD). His penis is small (4.5 cm) and the scrotum underdeveloped with cryptorchidism. Early pubic hair development is present. His muscle bulk is reduced but tone is increased.

Anaemia has been documented in the past and has responded poorly to iron therapy.

FAMILY HISTORY

Neither of the obligatory carriers II-2 or III-2 show any evidence of the above phenotype. However, IV-4 has had recurrent urinary tract infections and persistent renal impairment in the absence of any identifiable renal tract anomaly. She is of normal intelligence and does not exhibit any of the other clinical features described in this condition.

Results

HAEMATOLOGY AND MOLECULAR INVESTIGATIONS

(TABLE)

Hb H inclusions were looked for in all subjects in the table by staining a 2:1 dilution of whole blood with a freshly made solution of 1% new methylene blue in isotonic saline at 37°C for one hour.³ The films were examined by two observers, one of whom had no previous knowledge of the family relationships. Altogether, more than 150 high power fields (HPF, 100 to 250 cells per field) were examined from each specimen and the results from the two observers were in agreement. Around the time of this study, 43 routine haematology service samples from non-iron deficient patients were investigated in a similar fashion (50 HPF). Only two subjects (both of Far Eastern origin and with red cell indices indicative of the most severe form of α thalassaemia trait) were reported as positive. Because of the likelihood of X linked inheritance, the blood samples were also examined for the presence of two populations of red cells, differing in size or haemoglobinisation or both, using techniques that have been successful in the detection of carriers of X linked sideroblastic anaemia.^{4,5}

Haematological results for the various family members.

	Age	Hb	MCV	MCH	Hb H inclusions*	Technicon H1	
						% micro	% hypo
II-2	62	12.4	89	27.7	0	0.5	1.6
III-1	33	15.2	88	27.9	(+)	0.6	0.7
III-2	37	14.5	97	31.2	(+)	0.2	0.2
III-3	>30	14.7	100	31.2	0	0.2	1.4
III-4	>30	14.2	93	30.0	0	0.2	0.2
III-6	>30	15.4	88	29.2	0	0.5	0.3
III-7	26	11.2	79	24.1	++	6.0	9.3
IV-1	16	12.1	84	27.2	0	0.8	0.5
IV-2	13	11.1	78	24.1	++	7.4	6.8
IV-4	11	12.4	79	25.8	(+)	1.9	0.6
IV-6	18	13.1	87	27.5	0	0.4	0.5

*+ = <1 in 1000. ++ = 1 to 2%.

(+) = These results were not confirmed by staff in another laboratory using a different method (see Discussion). Normal ranges for 6 to 12 years are: Hb 11.5–15.5 g/dl, MCV 77–95 fl, MCH 25–33 pg; for 12 to 18 years: Hb = 12.0 (F)/13.0 (M)–16.0 g/dl, MCV = 78–102 (F)/98 (M) fl, MCH = 25–35 pg (Dallman, 1977); for adults: Hb = 11.5–15.5 (F)/13.0–16.5 (M) g/dl, MCV = 80–99 fl, MCH = 27–34 pg, % microcytes \leq 2.5%, % hypochromic cells \leq 2.5% (UHW reference ranges).

Molecular studies on III·7 and IV·2 showed no evidence of deletions in the α globin gene cluster (R Gibbons, D Higgs, personal communication).

Discussion

The fact that the six previously reported cases^{2,6} with non-deletional α thalassaemia/mental retardation are all cytogenetic males and that the phenotypically normal sister of one patient has Hb H inclusions makes X linkage the likely mode of inheritance. The family described in this report further supports X linkage and is the first recorded instance of an uncle and nephew with the proven syndrome. However, the phenotype of our two cases and that of the five cases reported by Wilkie *et al.*² is similar to the X linked mental retardation syndrome published by Chudley *et al.*,⁷ raising the question of whether this family also has the non-deletion α thalassaemia/mental retardation syndrome.

Although the red cells of the two affected family members could be identified by measurement of cell size, haemoglobin content (table), and cell size distribution width (not shown), none of these measurements was successful in detecting more than one red cell population in any of the female family members tested, including the obligatory carriers. β thalassaemia trait was excluded as a cause of microcytosis in both patients and iron deficiency was excluded in the proband. The ferritin level in III·7 was 10 $\mu\text{g/l}$ (range 15 to 300 $\mu\text{g/l}$). Cells with Hb H inclusions are identified by their characteristic 'golf ball' appearance when stained with methylene blue. The percentages of these cells in our patients (IV·2 1·3%, III·7 1·0%) appear to be lower than in the cases previously reported by Wilkie *et al.*² This low frequency probably accounts for the failure to detect Hb H on electrophoresis.

The reliability of Hb H inclusions in identifying carriers still has to be assessed. Using the conditions described above, routine investigation for Hb H inclusions found none in one of the obligatory carriers (II·2), but very low levels in the other obligatory carrier (III·2), as well as in one of the sisters (IV·4) and in the father of the proband. The finding of such rare positive cells in the father (III·1), who is unaffected by the syndrome and who has a normal male karyotype, casts doubt on the association between rare positive cells seen in the two women (III·2 and IV·4) and carrier status for this syndrome. The fact that III·1 has a full complement of α globin genes and normal red cell indices suggests that these cells may either exist in some normal subjects or be an occasional artefact of the method.

Blood samples from these same family members were studied for Hb H inclusions elsewhere by incubation in a 1:1 mixture of whole blood and 1%

brilliant cresyl blue in isotonic saline at room temperature for four hours or overnight. This test is sensitive enough to detect rare Hb H cells in some obligatory carriers of this syndrome and has not yet been known to give a false positive result. Under these conditions, after scoring more than 250 HPF, Hb H cells were found only in the two affected family members (IV·2 1·4%, III·7 0·8%) (R Gibbons, D Higgs, personal communication). These results would be consistent with artefactual production of the rare (< 1 in 1000) Hb H cells seen in this study and suggest the new methylene dye or incubation at 37°C or both to be the cause. Clearly more methodological studies are required and the finding of the rare Hb H cell should be interpreted with caution, particularly when the test is carried out as detailed here.

The significance of renal impairment in both IV·2 and IV·4 will remain unclear until renal function is assessed in further affected cases.

Previous reports of this syndrome have identified only sporadic cases which might suggest an increased incidence of fetal loss of affected males. It may be of relevance in our family that of the 20 descendants of II·4, who is at risk of being a gene carrier, there are 12 liveborn females and only two liveborn males. However, with increasing clinical recognition of this new X linked syndrome, it is probable that more familial cases will be identified.

We are very grateful to Drs B Ll Griffiths and S Wallace for allowing us to report the details of their patients, to Gwyn Bennett for preparing and examining the slides for Hb H inclusions, to Drs R Gibbons and D R Higgs of the Institute of Molecular Medicine, John Radcliffe Hospital, Oxford, for their data on the α globin gene clusters and Hb H inclusions in this family and for valuable discussions regarding methodology, and to Dr A Fryer and Mrs E France for obtaining additional clinical data.

- 1 Weatherall J, Higgs DR, Bunch C, *et al.* Hemoglobin H disease and mental retardation - a new syndrome or a remarkable coincidence? *N Engl J Med* 1981;305:607-12.
- 2 Wilkie AOM, Zeitlin HC, Lindenbaum RH, *et al.* Clinical features and molecular analysis of the α thalassaemia/mental retardation syndromes. II. Cases without detectable abnormality of the α globin complex. *Am J Hum Genet* 1990;46:1127-40.
- 3 Dacie JV, Lewis SM. *Practical haematology*. 6th ed. Edinburgh: Churchill Livingstone, 1984:186.
- 4 Peto TEA, Pippard MJ, Weatherall DJ. Iron overload in mild sideroblastic anaemias. *Lancet* 1983;i:375-8.
- 5 Holmes J, May A, Geddes D, Jacobs A. A study of congenital X linked sideroblastic anaemia. *J Med Genet* 1990;27:26-8.
- 6 Harvey MP, Kearney A, Smith A, *et al.* Occurrence of the α thalassaemia-mental retardation syndrome (non-deletional type) in an Australian male. *J Med Genet* 1990;27:577-81.
- 7 Chudley AE, Lowry RB, Hoar DI. Mental retardation, distinct facial changes, short stature, obesity, and hypogonadism: a new X linked mental retardation syndrome. *Am J Med Genet* 1988;31:741-51.