

PERICARDIAL COELOMIC CYSTS

BY

B. T. LE ROUX

From the Department of Surgery, Edinburgh University

(RECEIVED FOR PUBLICATION NOVEMBER 5, 1958)

Thin-walled cysts containing clear liquid are occasionally found in the anterior cardiophrenic angle. They are believed to develop in conjunction with the pericardium and are now generally called pericardial coelomic cysts. In this paper 20 cases of such cysts are described (Table I) and the relevant literature is discussed.

Of these 20 patients, 12 were men and eight were women. The youngest patient was 17 years and the oldest 69. Thirteen of the cysts were in the right cardiophrenic angle and six in the left. In one patient the opacity was visible on both sides of the cardiac shadow, but was larger on the right and was approached for removal through a right thoracotomy.

TABLE I
CLINICAL FINDINGS IN PRESENT SERIES

Case No.	Age	Sex	Side	Occasion for Radiographic Examination	Abnormal Clinical Findings	Special Investigations	Unusual Operative Findings	Size of Cyst	No. of Loculi	Biochemistry of Liquid
1	28	M	R	Respiratory infection	Impaired percussion note and breath sounds	Screening; A.P. induction and thoracoscopy	—	8 cm.	1	—
2	40	F	R	Pregnancy	Nil	Screening	—	10 "	1	—
3	43	M	R	M.M.R.	Nil	Screening and pneumoperitoneum	—	7 "	1	Protein, 195 mg.%
4	37	M	L	"	"	Screening	—	7 "	4	Protein, 400 " Chloride, 690 " Urea N., 28 "
5	35	M	L	"	"	Screening; A.P. induction; thoracoscopy	—	7½ "	1	—
6	64	F	L	Dysphagia	Impaired percussion note and breath sounds	Screening; A.P. induction; thoracoscopy	Oesophageal carcinoma	16 "	1	—
7	50	M	L	M.M.R.	Nil	Screening, pneumoperitoneum	Pleural calcification	10 "	1	—
8	46	F	R	"	"	" "	Tubular communication with pericardial sac	8 "	1	Protein, 225 mg. % Chloride, 616 "
9	41	F	R	"	"	Screening with reduction in size on deep inspiration, pneumoperitoneum	Tubular communication with pericardial sac and obliterated pleural space	5 "	1	Protein, 390 "
10	69	M	Bilateral	Respiratory infection	"	Screening	Cyst extended across mediastinum	12 "	1	—
11	50	M	R	M.M.R.	"	Screening and pneumoperitoneum	—	8 "	3	Protein, 290 mg. % Chloride, 620 "
12	65	M	R	"	"	Screening	Cyst densely adherent over 2 cm. to pericardium	6 "	1	—
13	40	M	R	Contact with case of pulmonary tuberculosis	"	Screening and pneumoperitoneum	—	8 "	3	Protein, 310 mg. % Chloride, 626 "
14	25	M	R	M.M.R.	"	" "	—	10 "	1	—
15	38	F	L	"	"	Screening	—	10 "	1	—
16	24	F	R	"	"	Screening with reduction in size on deep inspiration	Grape-like cluster of cysts communicating with pericardial sac	8 "	15	—
17	17	M	R	"	"	Screening	—	6 "	1	—
18	29	M	R	"	"	"	—	8 "	1	—
19	37	F	L	"	Impaired percussion note and breath sounds	"	—	12 "	1	—
20	42	F	R	"	Nil	"	—	6 "	1	Protein, 290 mg. % Chloride, 640 "

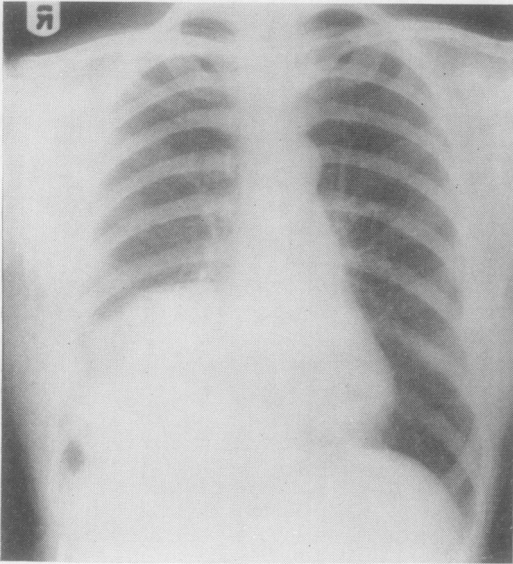


FIG. 1.—Posterior-anterior view of a right pericardial coelomic cyst.

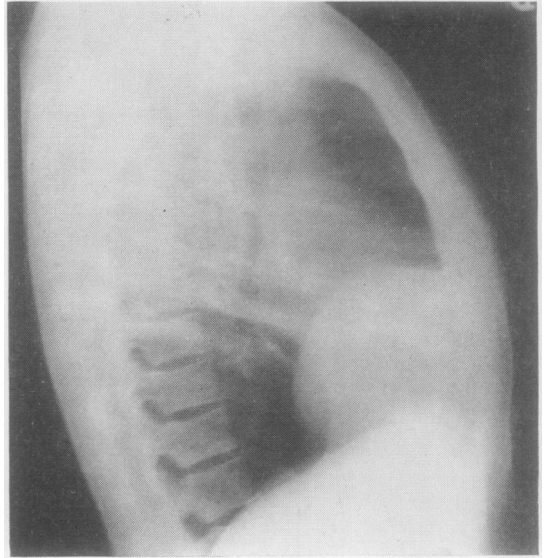


FIG. 2.—Lateral view of cyst shown in Fig. 1.

Fifteen patients were picked up during mass radiographic surveys. Two were radiographed because of a recent mild isolated respiratory infection, one because of recent contact with a case of pulmonary tuberculosis, one during the course of a normal pregnancy, and one because of dysphagia, found to be due to an oesophageal carcinoma which was later resected. No patient

was radiographed because of symptoms which could be related to the cyst, and all the cysts were detected directly as a result of a radiograph. Where the cyst was large, dullness of percussion and diminished air entry were the only clinical abnormalities. Smaller cysts were not associated with any abnormal clinical signs. Resection of the cyst in no way altered the sense of well-being

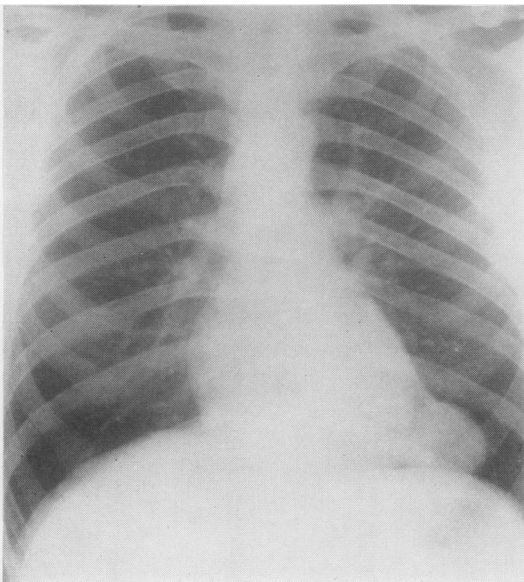


FIG. 3.—Postero-anterior view of left pericardial coelomic cyst.

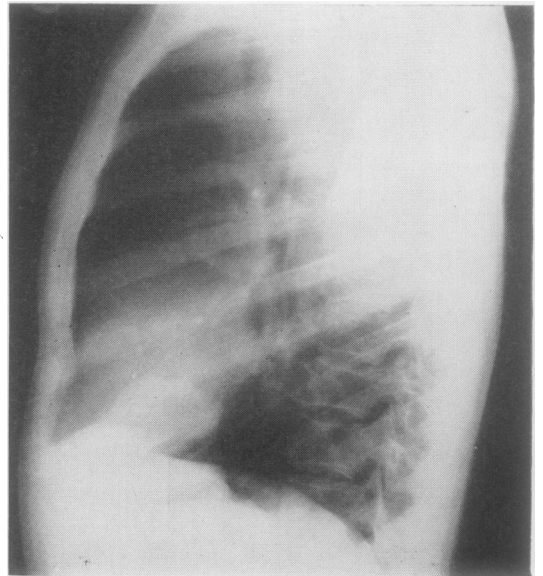


FIG. 4.—Lateral view of the cyst in Fig. 3.

of any patient, and there was no post-operative morbidity or mortality. Thoracotomy was undertaken in all but one of these patients because a firm pre-operative diagnosis was not made, and because of collateral experience of the less benign lesions which may mimic these cysts radiographically.

Postero-anterior and lateral films of the chest were made for each patient. The radiographs of a right and of a left cyst are illustrated (Figs. 1-4). In five the lateral film did not clearly show the opacity, and lateral tomograms were made to demonstrate that the opacity was in fact anterior. Bronchoscopically all had normal bronchi. Bronchograms were not made. No significant organisms were found in the sputa examined. A pneumoperitoneum was induced in seven patients with the object of excluding a Morgagni hernia. In all seven patients in whom the subphrenic spaces were seen, the opacity was shown to lie above the diaphragm and not to admit air from the peritoneal cavity. In three patients a pneumothorax was induced as a preliminary to thoracoscopy. One cyst was seen thoracoscopically but was not more confidently recognized as a cyst than on the plain film. One cyst was obscured by pleural adhesions. In the patient with the oesophageal carcinoma a very large left-sided cyst was seen both from without and from within, establishing that the opacity was not an extension of the oesophageal tumour.

All 20 patients were examined behind the x-ray

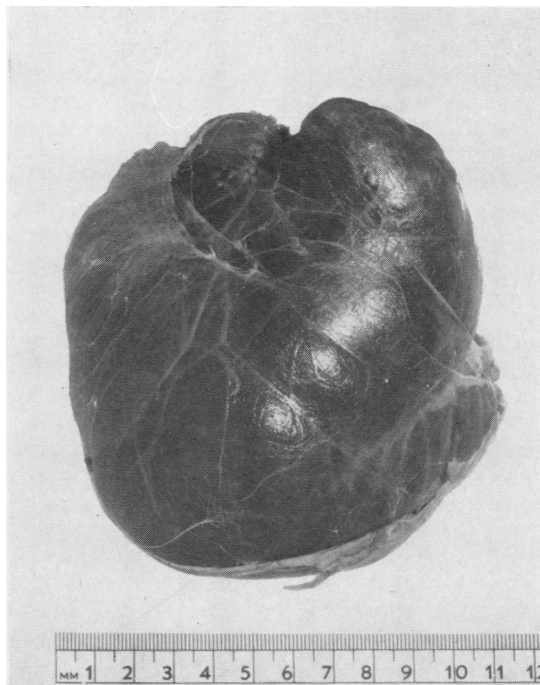


FIG. 5.—Resected specimen from the patient whose radiographs are illustrated in Figs. 1 and 2. This cyst was unilocular.

screen. No cyst was seen to bounce or wobble when the patient jumped or was shaken. Two cysts diminished in size when the patient inspired deeply, and both these cysts were found at thoracotomy to communicate freely with the pericardial cavity through a tube 3 mm. in diameter and 1 cm. long. A third cyst communicated similarly with the pericardium, but change in size at radioscopy was not observed.

The cysts ranged in size from 5 to 16 cm. in diameter. The three cysts that communicated with the pericardial cavity were half empty when first exposed and the contents could easily be displaced into the pericardial cavity and back again into the cyst. All the cysts were subpleural, and no vessel required ligation during the enucleation of any cyst. All lay in the angle between the pericardium and the diaphragm. Two were set back 1-2 cm. from the anterior chest wall and the others were in contact with the anterior chest wall. All but four were unilocular. Three had smooth outer surfaces but were multilocular on sectioning; one, that communicated with the pericardial sac, looked like a bunch of grapes, with loculi intercommunicating and all

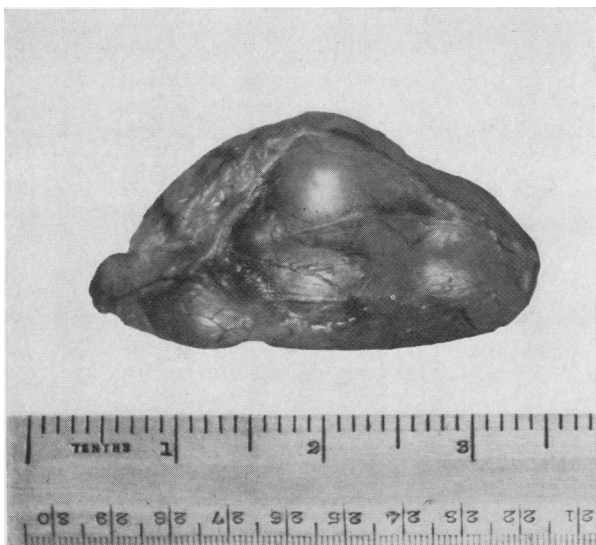

FIG. 6.—Resected specimen from the patient whose radiographs are illustrated in Figs. 3 and 4. This cyst was multilocular.

emptying easily into the pericardial cavity. A unilocular and a multilocular cyst are illustrated (Figs. 5 and 6). In 15 the liquid contained within the cyst was crystal clear; in five it was faintly yellow. Where the liquid was further examined it had the characteristics of a transudate.

The cyst wall was examined histologically in all cases and essentially the histological reports are the same, a single layer of flattened endothelial cells set upon laminated relatively acellular fibrous tissue of varying thickness (Figs. 7 and 8); the endothelium was shed in some places, and in some cysts the endothelial cells were more cuboidal than in others, and had more deeply staining nuclei.

In four of the 20 patients the diagnosis of pericardial coelomic cyst had been discarded pre-operatively. In one (Case 10) the radiographic opacity was bilateral (Fig. 9), and a dermoid cyst seemed the most likely diagnosis. At thoracotomy the cyst lay in front of the pericardium and extended across the mediastinum. A similar case has been described by Gerbasi (1954). The second patient thought not to have a cyst (Case 12) was a 65-year-old man who had a normal radiograph four years before he presented with a 6 cm. spherical opacity in the right anterior cardiophrenic angle (Figs. 10 and 11). There is no previous report of a cyst appearing while a patient has been under observation, or of a cyst increasing in size. A diagnosis of carcinoma was made, although the man was asymptomatic. A unilocular cyst densely adherent to but not

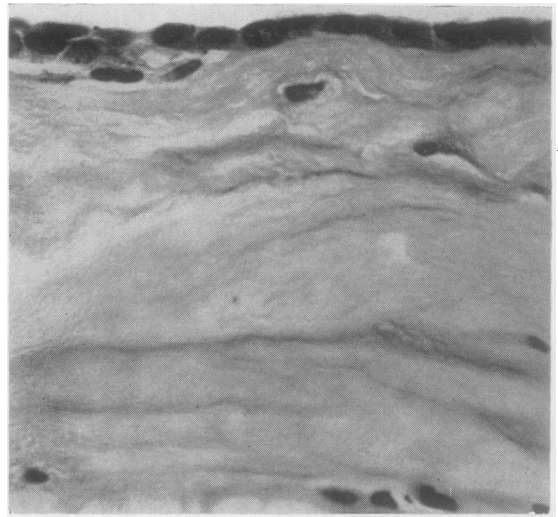


FIG. 7.—High-power photomicrograph showing a single layer of flattened endothelium set upon acellular fibrous tissue.

communicating with the pericardium was found at thoracotomy. A third patient (Case 5) presented with radiographs made over an interval of 10 years, showing the left-sided opacity to have doubled in size. This cyst was also unilocular and did not communicate with the pericardial sac. The fourth patient (Case 7) was thought not to have a cyst because pleural calcification was seen radiographically in relation to the left-sided opacity. An old emphyema was thought to be the most likely diagnosis. There is no known relationship between calcification of the pleura and pericardial coelomic cysts.

In the period during which the 20 cysts were resected 14 other patients were submitted to thoracotomy for spherical opacities in an anterior cardiophrenic angle. By the induction of a pneumoperitoneum three of these were established pre-operatively as herniae through the right foramen of Morgagni. Five were herniae of extraperitoneal fat through the right foramen of Morgagni. Two were dermoid cysts. One was a thymic cyst, one an aneurysm of the right ventricle, one an unusual projection of liver, and one a metastasis from a uterine carcinoma. All except the three peritoneal herniae through the foramen of Morgagni before thoracotomy were thought likely to be pericardial

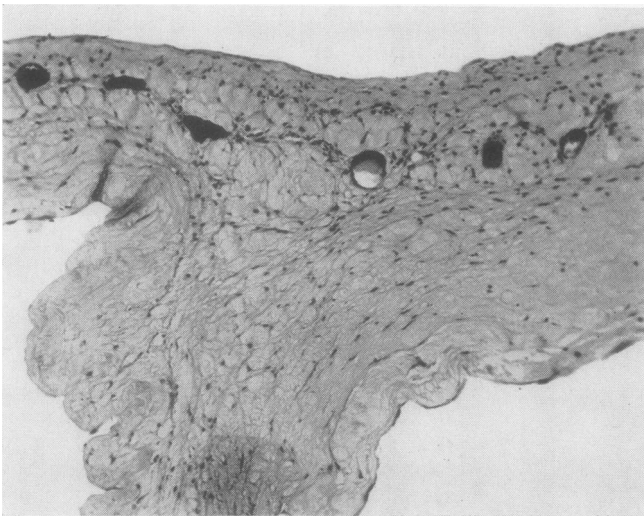


FIG. 8.—Low-power view of multilocular cyst showing one of the septa.

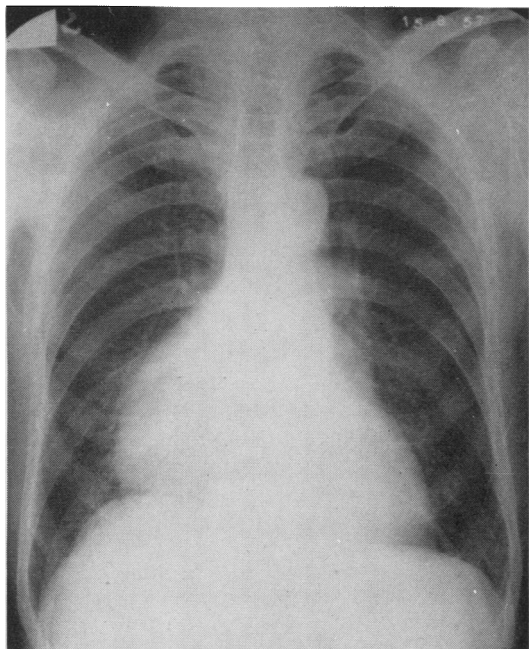


FIG. 9.—Postero-anterior view of a pericardial coelomic cyst which extended across the anterior mediastinum.

coelomic cysts. These cases are discussed in detail elsewhere (le Roux, 1959). Cooley (1958) has resected a left ventricular aneurysm that on the plain film looked like a pericardial coelomic cyst but, on screening, showed paradoxical expansion during ventricular systole. Brown and Robbins (1944) describe a left anterior cardiophrenic angle cyst lined by ciliated columnar epithelium—a bronchial cyst. Bates and Leaver (1951) record two malignant tumours resembling pericardial coelomic cysts, a papillary adenocarcinoma and a spindle cell endothelioma. Hydatid cysts and lipomas are included in the differential diagnosis of other authors who do not quote examples.

INCIDENCE

One in 3,400 admissions to Johns Hopkins Hospital over an eight-year period was for a primary tumour or cyst of the mediastinum (Sabiston and Scott, 1952). During this period 101 such tumours and cysts were recognized, and two of these were pericardial coelomic cysts. Three out of 300,000 people radiographed in a mass x-ray campaign in Edinburgh in 1958 were found to have pericardial coelomic cysts. From these figures it may be calculated that about one in every 100,000 of the population at large may have such a cyst.

REVIEW OF THE LITERATURE

Pickhardt (1934) was the first to describe the thorascopic appearances and later the resection of a pericardial coelomic cyst. Before this report cysts which were probably pericardial coelomic cysts were occasionally recorded as chance findings at necropsy (Edwards, 1927; Dufour and Mourrut, 1929) and were usually called lymphatic cysts. Kienböck (1927) described the radiographic appearances of what may have been a pericardial coelomic cyst. Freedman and Simon (1936), D'Abreu (1937), and Churchill and Mallory (1937) described cysts in patients with symptoms, and Yater (1931) described a multilocular cyst. Later authors (Barrett and Barnard, 1945; Greenfield, Steinberg, and Touroff, 1943) credit Churchill with the term "spring-water cyst," although in the original report the resected specimen is described as a hydrocele of the mediastinum. In 1940 Lambert reviewed the literature, added three further cysts, and suggested a pathogenesis. His was the first attempt at differentiation between thin-walled cysts of the mediastinum that had previously all been described as "probably of lymphatic origin."

Addey (1940), Curreri and Gale (1941), Greenfield and others (1943), Brown and Robbins (1944), and Barrett and Barnard (1945) described individual cysts, and Blades (1946) reported 10 cysts in army recruits, all chance radiographic

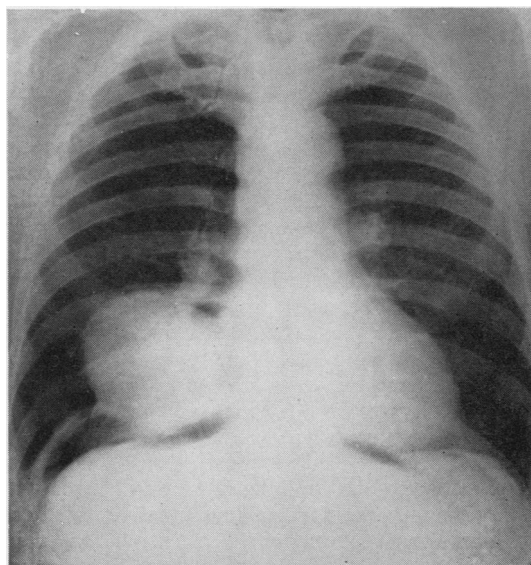


FIG. 10.—This patient had a normal radiograph four years before and was found to have a pericardial coelomic cyst at thoracotomy.

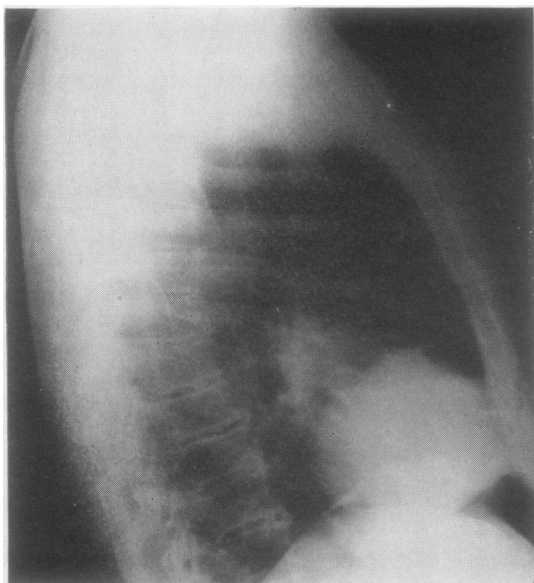


FIG. 11.—Lateral view of the cyst shown in Fig. 10.

findings in symptomless men. Lam (1947), Leahy and Culver (1947), Schein (1949), Buyers and Emery (1950), and Craddock (1950) reported cases, and Bradford, Mahon, and Grow (1947) added eight cases, Drash and Hyer (1950) five, and Lillie, McDonald, and Clagett (1950) 12 cases. In one of Bradford's cases and in a case of Kisner and Reganis (1950) the cyst was multilocular. Sabiston and Scott (1952), Forsee and Blake (1952), Loehr (1952), Davis, Dorsey, and Scanlon (1953), Yelin and Abraham (1953), Weig and Fuge (1954), and Ware and Conrad (1954) all reported series of cases, and Ware and Conrad, reviewing the literature, were able to collect 98 cases, adding two of their own. Including the present series there are now at least 120 cases on record, and of these 12 are of multilocular cysts.

Men have been more commonly affected than women in the proportion of 3:2. Cysts have been reported at all ages, from early adolescence to advanced age. Nearly twice as many cysts were right-sided as were left-sided. One-quarter of the reported cases have been said to have symptoms; three-quarters were asymptomatic, and were detected because of a radiograph made as a routine for unrelated reasons. Chest discomfort was the commonest complaint amongst those with symptoms—discomfort variously called tightness, a sensation of pressure, an ache, or pain. Dyspnoea was a less common complaint, cough still less common, and two patients had had

haemoptysis. Fatigue, weakness, palpitations, abdominal pain, indigestion, epigastric pain, dysphagia, and paroxysmal tachycardia were other complaints. Many patients had multiple complaints, and, reading the case reports, the impression has been gained that in these patients the chest was radiographed as a routine part of their investigation, and not in the belief that an intrathoracic lesion was the cause of their symptoms.

Four patients with large cysts are recorded as having been relieved of symptoms by resection of the cysts, two with dysphagia (Churchill and Mallory, 1937; Forsee and Blake, 1952), one with recurrent paroxysmal tachycardia (Forsee and Blake, 1952), and one with angina (Lam, 1947). With the exception of these four cases, there is little evidence in the literature of relief of symptoms by removal of the cyst, and little relationship between symptoms and cyst size. There is, however, a relationship between age and symptoms; the older patients more frequently had symptoms, and most of the symptoms mentioned are common in the elderly.

Clinical signs have been found only when the cyst was large. Only in rare instances did pre-operative investigations contribute to the making of a diagnosis. Lam (1947) records a case in which marked change in the contour of the opacity was observed with the phases of respiration when the patient was screened. In some instances the induction of a pneumothorax had demonstrated that the opacity was not parenchymal. Translucency of the cyst has very rarely been observed thoroscopically.

The difficulty of making a firm diagnosis without recourse to thoracotomy is emphasized throughout the literature. Alexander (1942) had made axiomatic the reasons for operating on cases such as these, namely, most circumscribed intrathoracic opacities arise within the lung, almost all are malignant, and many of these arising outside the lung are also malignant. Resection of these cysts presents no technical difficulty. No patient is recorded as having come to harm from resection, and there are rare, well-established instances of relief of symptoms by resection. If an irrefutable diagnosis could be made without thoracotomy, there is probably no justification for the resection of these cysts in the asymptomatic.

The histological features of the reported cysts are the same as those in the present series. Tubular communication between cyst and pericardium is recorded (Bradford and others,

1947; Schein, 1949; Buyers and Emery, 1950; Drash and Hyer, 1950; Bates and Leaver, 1951; Forsee and Blake, 1952) and was found in three of the present series. Lillie and others (1950) adduce this as evidence of the common origin of cyst and pericardium. Biochemical analysis of the liquid contained within the cysts shows this to be a transudate rather than lymph or an exudate (Lillie and others, 1950).

COMPARISON WITH CYSTIC HYGROMAS

The distinction between coelomic cysts and cystic hygromas has exercised many authors. Multilocularity of some of the reported cysts has been suggested as evidence of their lymphatic origin. Typical hygromas intimately incorporate surrounding structures and receive a recognizable blood supply from all sides, in contradistinction to the facility with which coelomic cysts are shelled out without the need for the ligation of vessels. Goetsch (1938) maintains that hygromas enlarge by a process of endothelial sproutings, which insinuate themselves between and around related structures. Gross and Hurwitt (1948) suggest that in the mediastinum this method of proliferation may not occur. Harley and Drew (1950) review eight cystic hygromas of the mediastinum, and emphasize their lack of definition and the difficulty experienced in their resection. Three hygromas were in patients under 10 years of age, seven lay in the anterior mediastinum, two communicated with swellings in the neck, and one patient had symptoms (Skinner and Hobbs, 1936).

It is generally accepted that the unilocular cyst, shelling out with great ease, is a different pathological entity from the multilocular cyst, adherent to and incorporating in its walls surrounding structures, although section of their walls may be histologically indistinguishable. What of multilocular cysts shelling out with ease, are they hygromas or coelomic cysts? The question is largely academic, but, if communication with the pericardial cavity is accepted as evidence of origin along with the pericardial coelom, then, on the basis of the multilocular cyst so communicating, reported in this series, multilocularity must be accepted as an aberration of some coelomic cysts.

EMBRYOLOGY AND PATHOGENESIS

Three different aberrations of development of the pericardial and pleural cavities are inculpated as possible causes of the development of

pericardial coelomic cysts. The possibility that some of the cysts are of lymphatic origin cannot be ignored.

(1) The horseshoe-shaped intra-embryonic coelom results from the confluence of initially isolated cavities in the lateral plate mesoderm. These appear very early in the life of the embryo, even before any differentiation has occurred which indicates the site of the heart. They are irregularly situated and are in no sense metameric, that is, they are not limited in their distribution and have no somatic relationship. These lacunae persist for a time as independent spaces, then enlarge, merge, and coalesce to form the intra-embryonic coelom.

Lambert (1940) believes that an irregularity in the rate of development of one of these lacunae may result in the formation of a congenital diverticulum of the pericardium. Failure of one of these lacunae to merge with the others, its persistence and development into an independent cavity, may, he thinks, be the pathogenesis of the cyst to which he gave the name "pericardial coelomic cysts." Against this it must be remembered that these lacunae are the forerunners of the whole of the intra-embryonic coelom and no explanation is thereby offered for the occurrence of these cysts in a cardiophrenic angle.

Drash and Hyer (1950) consider that these primitive lacunae are too early and too delicate to contribute to the formation of such a cyst.

(2) In his original description of the formation of the pericardium and other body cavities, His (1881) distinguished two pairs of recesses in the pericardial coelom. These he called the dorsal and ventral parietal recesses of the pericardial coelom. The dorsal parietal recesses are the pericardio-peritoneal canals, which play an important role in the formation of the pleural cavity. The significance of the ventral parietal recesses has remained obscure and they are not well defined in all embryos. Their presence was shown in the rabbit by Elliott (1931) and in the human embryo by Mall (1910) and Davis (1923).

Lillie and others (1950) were impressed by the location of most cysts in the cardiophrenic angle and the communication between occasional cysts and the pericardial sac, and they were struck by the similarity of structure of endothelial-lined cysts of the mediastinum with that of congenital diverticuli of the pericardium. They postulate that persistence of the blindly ending ventral parietal recess in varying degree is responsible for these pathological states: (a) Where the recess

persists intact, there results a wide-based diverticulum of the pericardium. (b) Where the proximal portion of the recess is constricted, the resulting pericardial diverticulum has a narrow base. (c) Where the proximal portion is constricted and attenuated, there results a pericardial coelomic cyst with a pedicle extending to the pericardium. (d) Where the recess is completely pinched off, the resulting cyst lies free in the cardiophrenic angle. (e) Where the recess is completely pinched off, and left cephalad as the septum transversum descends caudally, there results a mesothelial-lined cyst in the mediastinum higher than the cardiophrenic angle.

If this theory is true, a relationship is established between pericardial coelomic cysts and the rare diverticula of the pericardium which are of developmental and not inflammatory origin. The advantages of this theory are that it is based upon the existence of a definite embryological structure at a fairly advanced stage of development, and it explains the occurrence of the cysts in the cardiophrenic angle.

(3) Kindred (quoted by Drash and Hyer), discussing the growth of the pleural cavities, draws attention to the so-called secondary pleural cavity which grows at the expense of the split lateral body wall, and in so doing meets opposition, unlike that part of the pleural cavity which develops from the pericardio-peritoneal canal. Because of the resistance offered to the growth of the secondary pleural cavity he believes that the areas of enlargement may be unequal and folds may be present in the wall of the advancing pleural cavities. Such folds may be obliterated with later growth, others may enlarge at the same rate as the growing pleural cavities, and when the latter occurs it is possible that such folds may be cut off and form cystic sacs around which connected tissue can be laid down in the same manner as the lamina propria of the pleura. Such cystic spaces would occur in any region of the pleura which has been derived from secondary invasion of the body wall.

DISCUSSION

The arguments of Lillie and others (1950) for the origin of those cysts that lie in the cardiophrenic angle are convincing, and it seems justifiable to call those cysts "pericardial coelomic cysts." As Drash and Hyer point out, they are mesothelial cysts, aberrations in the development of a coelomic cavity, and it seems that some could represent aberrations of pericardial development

and others—perhaps those situated in the mediastinum, away from the cardiophrenic angles—aberrations in the development of a pleural sac. The common mesothelial origin of the cysts and of the lymphatic system makes it impossible to exclude, on embryological grounds, development of some cysts from lymphatic structures.

NOMENCLATURE.—A host of terms has been used to describe these cysts. Those encountered in the literature are listed. Most are descriptive of the site, the contents, or the histology of the cysts, but others, introduced by Drash and Lambert, imply a conception of pathogenesis. "Pericardial coelomic cysts," at least for those in the cardiophrenic angle, seems the most desirable term. These are hydrocele of the mediastinum, simple cyst of the mediastinum, serosal cyst, spring-water cyst, para-pericardial cyst, pleuro-pericardial cyst, pleural cyst, mesothelial mediastinal cyst, (Drash and Hyer, 1950), and pericardial coelomic cysts (Lambert, 1940).

SUMMARY

Twenty new cases of pericardial coelomic cyst are reported.

The literature is reviewed.

Features distinguishing pericardial coelomic cysts from cystic hygromas (cystic lymphangiomas) of the mediastinum are discussed.

The theories of origin of these cysts are presented and discussed.

REFERENCES

- Addey, W. (1940). *Brit. J. Radiol.*, **13**, 180.
 Alexander, J. (1942). *J. Amer. med. Ass.*, **119**, 395.
 Barrett, N. R., and Barnard, W. G. (1945). *Brit. J. Surg.*, **32**, 447.
 Bates, J. C., and Leaver, F. Y. (1951). *Radiology*, **57**, 330.
 Blades, B. (1946). *Ann. Surg.*, **123**, 749.
 Bradford, M. L., Mahon, H. W., and Grow, J. B. (1947). *Surg. Gynec. Obstet.*, **85**, 467.
 Brown, R. K., and Robbins, L. L. (1944). *J. thorac. Surg.*, **13**, 84.
 Buyers, R. A., and Emery, F. B. (1950). *Arch. Surg. (Chicago)*, **60**, 1002.
 Churchill, E. D., and Mallory, T. B., Cabot case 23492 (1937). *New Engl. J. Med.*, **217**, 958.
 Cooley, D. A. (1958). Personal communication.
 Craddock, W. L. (1950). *Amer. Heart J.*, **40**, 619.
 Curreri, A. R., and Gale, J. W. (1941). *Ann. Surg.*, **113**, 1086.
 D'Abreu, A. L. (1937). *Brit. J. Surg.*, **25**, 317.
 Davis, C., Dorsey, J., and Scanlon, E. (1953). *A.M.A. Arch. Surg.*, **67**, 110.
 Davis, C. L. (1923). *Contrib. Embryol. Carnegie Instn*, **15**, No. 72.
 Drash, E. C., and Hyer, H. J. (1950). *J. thorac. Surg.*, **19**, 755.
 Dufour, H., and Mourrut (1929). *Bull. Soc. med. Hop. Paris*, **2**, 1482.
 Edwards, A. T. (1927). *Brit. J. Surg.*, **14**, 607.
 Elliott, R. (1931). *Amer. J. Anat.*, **48**, 355.
 Forsee, J. H., and Blake, H. A. (1952). *Surgery*, **31**, 753.
 Freedman, E., and Simon, M. A. (1936). *Amer. J. Roentgenol.*, **35**, 53.
 Gerbasi, F. S. (1954). *Ann. intern. Med.*, **41**, 828.
 Goetsch, E. (1938). *Arch. Surg. (Chicago)*, **36**, 394.

- Greenfield, I., Steinberg, I., and Touroff, A. S. W. (1943). *J. thorac. Surg.*, **12**, 495.
- Gross, R. E., and Hurwitt, E. S. (1948). *Surg. Gynec. Obstet.*, **87**, 599.
- Harley, H. R. S., and Drew, C. E. (1950). *Thorax*, **5**, 105.
- His, W. (1881). *Arch. Anat. (Lpz.)*. (Anat. Abt.), p. 303. Quoted by Lillie, McDonald, and Clagett (1950).
- Kienböck, R. (1927). *Brit. J. Radiol.*, **32**, 352.
- Kindred. Personal communication. Quoted by Drash and Hyer (1950).
- Kisner, W. H., and Reganis, J. C. (1950). *J. thorac. Surg.*, **19**, 779.
- Lam, C. R. (1947). *Radiology*, **48**, 239.
- Lambert, A. V. S. (1940). *J. thorac. Surg.*, **10**, 1.
- Leahy, L. J., and Culver, G. J. (1947). *J. thorac. Surg.*, **16**, 695.
- le Roux, B. T. (1959). Awaiting publication.
- Lillie, W. I., McDonald, J. R., and Clagett, O. T. (1950). *Ibid.*, **20**, 494.
- Loehr, W. M. (1952). *Amer. J. Roentgenol.*, **68**, 584.
- Mall, F. P. (1910). In *Manual of Human Embryology*, ed. F. Keibel and F. P. Mall, Vol. 1, p. 523. Lippincott, Philadelphia.
- Pickhardt, O. C. (1934). *Ann. Surg.*, **99**, 814.
- Sabiston, D. C., and Scott, H. W. (1952). *Ibid.*, **136**, 777.
- Schein, C. J. (1949). *Amer. J. Surg.*, **78**, 411.
- Skinner, G. F., and Hobbs, M. E. (1936). *J. thorac. Surg.*, **6**, 98.
- Ware, G. W., and Conrad, H. A. (1954). *Amer. J. Surg.*, **88**, 272.
- Weig, C. G., and Fugt, W. W. (1954). *Dis. Chest*, **26**, 110.
- Yater, W. M. (1931). *Amer. Heart J.*, **6**, 710.
- Yelin, G., and Abraham, A. (1953). *Dis. Chest*, **23**, 285.