

Cyclophosphamide in the management of advanced bronchial carcinoma

R. D. W. McLEAN¹

From the Thoracic Surgical Unit, Forster Green Hospital, Belfast, Northern Ireland

Patients with the distressing symptoms of advanced bronchial carcinoma present a difficulty in management. As the incidence of this disease is expected to rise, and as 60% of cases are inoperable when first seen (Grenville-Mathers and Trenchard, 1964), it is a problem that is likely to increase. Present methods are aimed at producing temporary regression of the tumour by the use of radiotherapy or cytotoxic drugs. Both have been far from satisfactory, since any benefit obtained is often limited by a high incidence of toxic effects on normal tissues. Any cytotoxic drug which may have a higher therapeutic index is worth investigation. This is a report of our experience with cyclophosphamide in advanced bronchial carcinoma.

Cyclophosphamide (Endoxan; Endoxana; Cytoxan) is a nitrogen mustard phosphoramidate synthesized in 1958 by Arnold and Bourseaux (Arnold and Bourseaux, 1958; Arnold, Bourseaux, and Brock, 1958). It has been found to have a similar carcinotoxic effect to that of other alkylating agents (Papac, Petrakis, Amini, and Wood, 1960; Foye, Chapman, Willett, and Adams, 1960), but with a significantly higher therapeutic index (Brock and Wilmanns, 1958).

Since it was introduced to clinical use (Gross and Lambers, 1958) there have been a large number of published reports of its use in a wide variety of malignant conditions (Dick and Phillips, 1961). These have included cases of bronchial carcinoma. The results have been variable. Table I summarizes the results of some of the published series that have included more than 10 cases of bronchial carcinoma. The number showing an objective response and the total number treated are recorded.

The results are not comparable, since the dosage varied, and in some it would now be regarded as inadequate. The duration of response was not always stated, but, where given, it averaged two to three months.

TABLE I

Series	Objective Response	Total No. of Cases of Bronchial Carcinoma
Eckhardt, Sellei, and Hartai (1959)	12	22
Gerhartz, Algenstaedt, and Kessel (1960)	10	47
Shnider, Gold, Hall, Dederick, Nevinny, Potee, Lasagna, Owens, Hreschysyn, Selawry, Holland, Jones, Colsky, Franzino, Zubrad, Frei, and Brindley (1960)	3	30
Dittrich (1961)	3	20
Wieland and Wieland (1961)	6	26
Hessen (1960)	0	14
Anders and Kemp (1961)	8	27
Bergsagel and Levin (1960)	1	11
Reeve (1961)	18	48
Aronovitch, Meakins, and Groszman (1960)	10	16

In this trial of cyclophosphamide we were particularly interested in two aspects of its use: first, to see whether results could be improved by employing the highest dosage possible and, if the initial response was good, by a further intravenous course when relapses occurred; secondly, to verify our clinical impression that oat-cell carcinoma responded more favourably than the other histological types.

METHOD

There were no strict criteria for selection. All patients had advanced bronchial carcinoma with metastases. All had symptoms of sufficient severity to prevent their leading a comfortable life. There were no limits set to the amount of cyclophosphamide given, since experience with previous cases had suggested that to obtain full therapeutic benefit it was necessary to give the maximum amount possible to each patient, the total dosage being governed by the onset of side-effects. In order to bring the tumour under rapid control and to hasten symptomatic relief, all patients were admitted to hospital and given the drug intravenously. Doses of 400 mg. daily were used. Though this is double the recommended dose we have found it to be the most satisfactory. With small doses the therapeutic effect is reduced; with larger doses nausea and anorexia become much more marked.

¹Present address: Royal Victoria Hospital, Belfast

Daily intravenous therapy was continued until the white-cell count fell to 2,000 per c.mm. and then it was stopped. The white-cell count usually continued to fall over the succeeding three to five days and then rapidly recovered. When the white-cell count had risen to 2,500 per c.mm. treatment with oral cyclophosphamide was continued indefinitely. The oral dosage was of the order of 100 to 200 mg. daily, the amount again depending on individual tolerance. While in hospital, ancillary treatment, such as correction of anaemia by transfusion, antibiotics, physiotherapy, etc., was given where indicated. When the white-cell count was depressed below 3,000 per c.mm. we considered it advisable to give antibiotic cover.

After discharge, patients were seen at fortnightly intervals for blood count and examination. The oral dosage was then adjusted accordingly, the aim being to give as much as possible without depressing the white-cell count below 2,500 per c.mm. If there was evidence of relapse, or if new lesions were discovered, and if the initial response had been good, then these patients were admitted for a further intravenous course. The procedure was the same as in the first admission.

SIDE-EFFECTS

Leucopenia Leucopenia occurred in all patients and was the main factor limiting the amount of cyclophosphamide given. As stated, 400 mg. intravenously daily was given until the white-cell count fell to 2,000 per c.mm. This occurred remarkably constantly when the total dosage reached between 4 and 5 g. and appeared to be independent of the initial white-cell count. In the early stages the white-cell count usually rose, and a fall was not apparent until a total of about 2.5 g. had been given. Thus, apart from a white-cell count at the beginning of treatment, we have found little necessity to do further counts until the end of the first week. When cyclophosphamide was stopped the white-cell count usually continued to fall for three to five days. Recovery was always rapid. Figure 1 shows the behaviour of 16 white-cell counts during and after intravenous treatment on this regime, and the relation to total dosage.

There were no adverse effects in those patients in whom the white-cell count was depressed below 1,000

per c.mm. Those in whom a second or subsequent intravenous course had been given became more tolerant to the drug and received a higher dosage before the white-cell count fell below 2,000 per c.mm. Most of those on oral maintenance therapy could tolerate 200 mg. daily. With careful management we have not found leucopenia to be a serious hazard.

Platelets and erythrocytes In no patient was the platelet or erythrocyte count significantly reduced, even in those in whom the white-cell count fell below 700 per c.mm. This is an advantage of cyclophosphamide over other cytotoxic drugs.

Nausea This occurred in a few patients in the early stages of treatment and tended to ease after a few days. It was never of sufficient severity to necessitate stopping treatment.

Alopecia This occurred to some degree in about 70% of patients. Most developed a diffuse thinning of the hair, but total loss occurred in three, and patchy loss in two. Women appeared to be more affected than men. The hair tended to regrow after three to five months and not to be affected by continuing treatment. Regrowth was meagre in the older age groups. None of our patients appeared to be unduly upset by this unfortunate complication, but it is advisable to warn patients of it before starting treatment.

Local effect The complete freedom of cyclophosphamide from any sclerosing action on veins is another advantage. One patient was given two intravenous courses, totalling 14 g., via the same site in his only accessible vein.

Two unusual side-effects, which have been reported previously, were seen. One patient developed a painful, smooth, red tongue and angular stomatitis, which responded to vitamin-B complex (Healy, 1964), and another complained of an unpleasant metallic taste after injection (Dick and Phillips, 1961). Cystitis (Coggins, Ravdin, and Eisman, 1959) and skin reactions (Healy, 1964) have been reported by others, but no examples were seen in this series.

RESULTS

The results obtained are summarized in Table II. It is impracticable to discuss all aspects of individual cases, but some will be discussed more fully below. In classifying the histological type of the tumour, we have distinguished between anaplastic and oat-cell carcinoma, since we believe the latter to be a specific tumour type in origin, symptoms, and clinical course (see discussion Watson and Berg, 1962; Levine and Weisberger, 1955). A histological diagnosis was obtained in all cases. Each patient was seen by an independent observer.

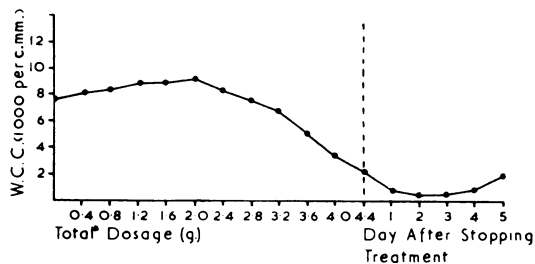


FIG. 1. Shows the relation between white-cell count and total dosage of cyclophosphamide.

TABLE II

SUMMARY OF RESULTS AND ASSESSMENT OF RESPONSE

Cell Type	No. of Cases	Subjective Improvement			Objective Improvement		
		+	++	+++	+	++	+++
Squamous	13	8	1	0	1	0	0
Anaplastic	6	3	3	0	3	0	0
Oat-cell	21	1	3	17	4	7	10

The response was assessed both subjectively and objectively.

Improvement in general well-being and relief of pain, dyspnoea, etc., were recorded as subjective improvement. An attempt was made to grade this response, +++ indicating that the patient felt as well as before the onset of symptoms, ++ indicating marked improvement, and + a slight but definite improvement.

Radiological regression of the primary, reduction in size of visible or palpable metastases, or in the effects of these (e.g., superior vena caval obstruction), were recorded as objective improvement and were graded as very good +++, good ++, or fair +.

COMMENT AND DISCUSSION

Most patients experienced some subjective improvement. Part of this was almost certainly due to hospital care and any other treatment given. There was, however, a difference in subjective response, both in degree and pattern, between the histological types. In squamous-cell tumours any subjective improvement was always gradual in onset, seldom significant, and short in duration. We felt that these patients derived no benefit from the drug. Anaplastic-cell cases did rather better and appeared to obtain slight benefit from cyclophosphamide, but the duration of this response was disappointing. Patients with oat-cell carcinoma behaved differently. Improvement occurred in all, often quite dramatically, within the first week of treatment. This was noted even in those patients who had been admitted for several days' investigations, etc., and had had the benefit of any ancillary treatment necessary. An increased feeling of well-being was the first evidence of response and was a good prognostic sign. This took place so consistently in oat-cell cases as to be of diagnostic value.

An objective improvement was seen in 40% of patients. A similar difference in response was noted between the histological types. Only one out of 12 patients with squamous carcinoma showed

any objective improvement; this lasted for one month. Of the six patients who had anaplastic carcinoma, slight objective improvement was noted in three. The duration was short (averaging one month) and we considered that in this type of tumour the course of the disease was not significantly affected. All who had oat-cell carcinoma showed an objective response, graded ++ or better in 17 out of 21 patients. The average duration of this initial response was six months (ranging from one to 18 months). In this type the results were particularly good in superior vena caval obstruction, where complete resolution of neck engorgement took place in all patients. Regression of lymph node and abdominal metastases was often striking. The drug appeared to have a less marked effect on the primary than on metastases; the site of the latter did not appear significant.

Despite high oral maintenance therapy, relapse or the development of new lesions took place eventually in all patients. The effect of a further intravenous course on such patients as these has not, as far as we can find, been studied. Ten of our patients, who showed a good initial response, were re-admitted for this; eight had oat-cell and two anaplastic-cell tumours. The two with anaplastic-cell growths showed no further response and continued to deteriorate. Seven of the eight oat-cell lesions responded well with symptomatic relief and further regression of objective signs. The one failure had massive hepatic metastases and was moribund on admission. As mentioned earlier, a higher total dosage was necessary to obtain a therapeutic effect, but fortunately the leucoblastic tissues appear more tolerant, and such doses can be given without undue white-cell count depression. The duration of response is shorter than that following the initial intravenous course (averaging two months).

Four of the above 10 patients who developed severe symptoms on further relapse were again re-admitted for a third intravenous course. One (no. 13) showed no further response and died. Another (no. 2) responded well and remained comfortable on oral cyclophosphamide with booster intravenous doses for a further three months. The other two patients (nos 10 and 28) felt some subjective improvement, and although there was no improvement in objective signs, the progression of the disease appeared to be temporarily halted. Three of these histories will be described in more detail.

CASE 2 M., aged 40, was first seen in October 1963 with signs of superior vena caval obstruction of

two weeks' duration and a four-month history of increasing dyspnoea and right shoulder pain. Radiography showed an irregular mass in the right upper lobe extending to the upper mediastinum. On bronchoscopy the right upper lobe orifice was blocked by an oat-cell carcinoma. He was given a total of 4.4 g. cyclophosphamide intravenously. This produced complete resolution of neck signs, relief of all symptoms, and some radiological regression. He returned to work and remained well on 50 mg. b.d. In March 1964 he was re-admitted as an emergency in great distress and with gross recurrence. A further course, totalling 6.4 g. intravenously, was given, again with complete regression of the neck signs. He was discharged on 50 mg. t.i.d., and remained well until May 1964. He then developed a rapid recurrence over 48 hours and was sent to hospital as a terminal case. In view of the severity of his symptoms we thought there was little to lose by giving massive doses. He was given 800 mg. daily, up to a total of 10.4 g. This depressed his white-cell count to the region of 200 to 400 per c.mm. for a period of 10 days. There was partial, though definite, reduction in signs and considerable relief of symptoms. He remained reasonably comfortable on 200 mg. orally daily with thrice-weekly 'booster' intravenous doses of 400 mg. for a further two months. He died nine months after starting treatment with cyclophosphamide. Necropsy showed extensive infiltration of the mediastinal and neck tissues by an oat-cell carcinoma.

CASE 10 F., aged 58, was first seen in April 1964 with signs of superior vena caval obstruction, supraclavicular lymph node metastases, and an oat-cell carcinoma infiltrating the left main bronchus. She was given a total of 4.4 g. cyclophosphamide intravenously. This produced almost complete radiological regression (Figs 2 and 3), disappearance of neck node metastases, and resolution of the neck signs. She developed total alopecia but remained well for five months. She was re-admitted with a two-week history of neck pain and recurrence of the lymph node metastases. By this time her hair had almost completely regrown. A further total of 5.4 g. cyclophosphamide was given with 80% reduction in node size and relief of symptoms. Her hair was not affected by the second course. She remained well for a further two months and was then re-admitted with a recurrence. A third course of 5 g. was given. There was some symptomatic benefit but no objective improvement. Her condition has since deteriorated.

CASE 13 M., aged 64, had a right pneumonectomy in January 1963 for an oat-cell carcinoma. He was seen in May 1964 with a six-week history of epigastric pain. A large mass was palpable in the upper abdomen, and there was a large lymph node metastasis in the neck. A total of 5 g. cyclophosphamide was given intravenously. Thereafter both metastases were no longer palpable. He was discharged on 50 mg. b.d. and remained well for six

months. He was re-admitted in December 1964 with a rapidly developing right hemiplegia and dysphasia. At this time there was no clinical evidence of recurrence in the neck or abdomen. A further total of 6 g. was given intravenously. This produced a dramatic improvement in the hemiplegia. There was only minimal weakness clinically and he was able to walk unaided. He remained well for three weeks before the return of hemiparesis could be detected. A week later he was re-admitted and a third course was started without effect. Necropsy showed metastases from an oat-cell carcinoma in the left adrenal, transverse mesocolon, and lymph nodes of the neck, and multiple cerebral metastases, including the left internal capsule.

CASE 1 This case is worth recording because of the long duration of response. M., aged 44, had a left thoracotomy in September 1963. An oat-cell carcinoma was found in the left upper lobe with infiltration of the aorta, the mediastinum, and the chest wall. No resection was possible. Because of severe chest pain following operation he was treated with cyclophosphamide. There was complete relief of symptoms and almost total radiological regression of the tumour (Figs 4 and 5). This regression has now been maintained for a period of 18 months. He has been having cyclophosphamide, 50 mg. b.d. orally. A hepatic metastasis was found recently and is responding well to a second intravenous course (February 1965).

The favourable response by oat-cell tumours to nitrogen mustards and the poor response by other types has been noted previously (Watson and Berg, 1962; Levine and Weisberger, 1955). We have found a similar relationship with cyclophosphamide and agree with others who reported that in bronchial carcinoma the response depends on the histological type of the tumour (Gerhartz, 1959). The effect of cyclophosphamide on squamous and anaplastic types is negligible. Only in oat-cell carcinoma is a significant and lasting response obtained, and only with this type is intensive cyclophosphamide therapy worthwhile. Such a regime requires a considerable amount of time and organization and involves two or more periods of hospital admission. Selection of patients is therefore desirable. Although we have admitted patients for intravenous courses, the earlier stages of these could be given on an out-patient basis in view of the constant relationship between leucopenia and total dosage; admission is only necessary during white blood cell depression. Bed occupancy could thus be decreased. There were no cases of adenocarcinoma in this series, but others have found the drug to be of no value in this type of case (Gerhartz, Algenstaedt, and Kessel, 1960).

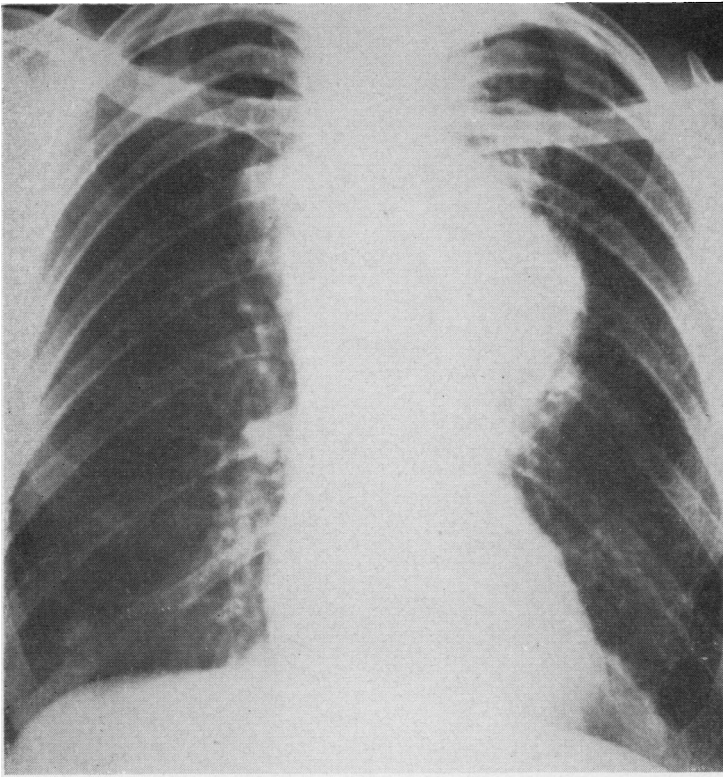


FIG. 2. *Case 10. Radiograph taken 16 April 1964, before the start of treatment. There is a large mass in the left upper lobe infiltrating the left upper mediastinum with contralateral mediastinal lymph node metastases.*

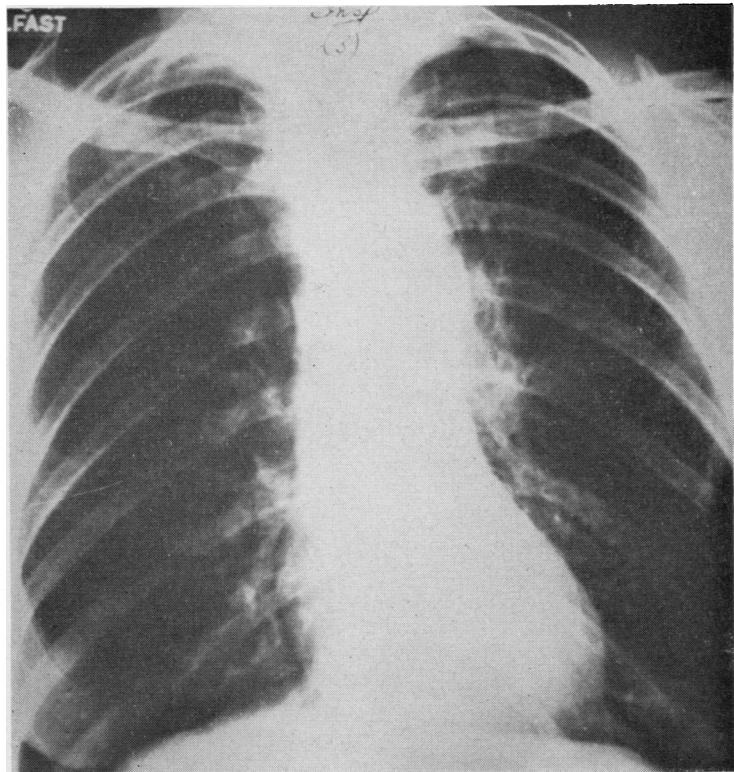


FIG. 3. *Case 10. Radiograph taken 27 April 1964 after the administration of 4.4 g. cyclophosphamide. There has been almost complete radiological regression.*

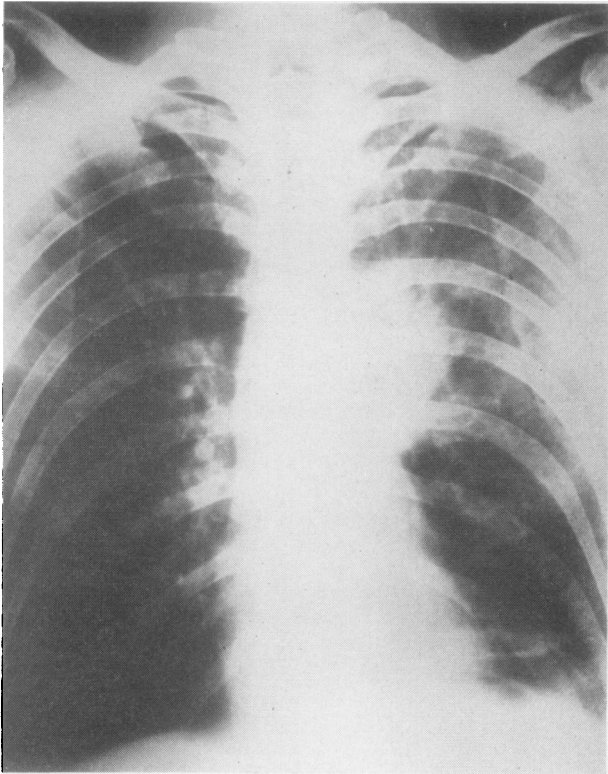


FIG. 4. *Case 1. Radiograph taken 7 September 1963 before the start of treatment shows a mass at the left hilum with contralateral mediastinal metastases.*

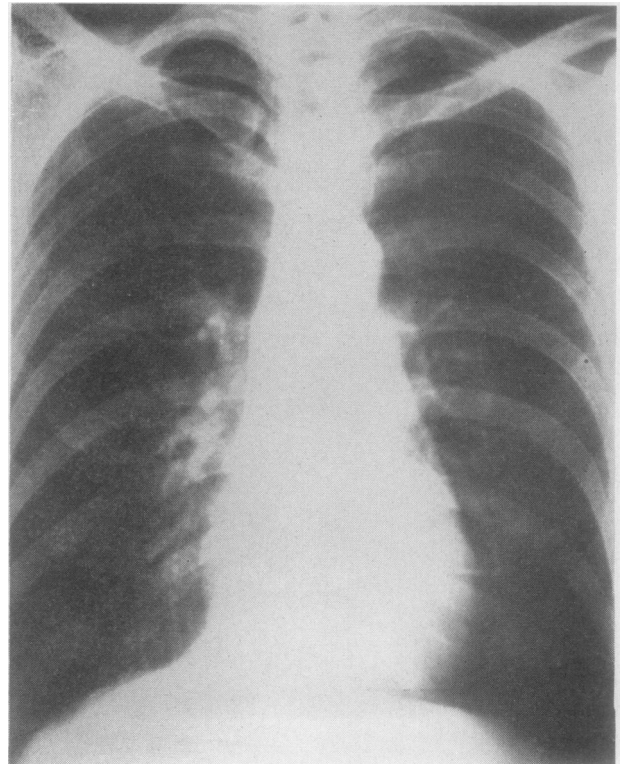


FIG. 5. *Case 1. Radiograph taken 14 November 1964 shows that complete radiological regression is still maintained 14 months later.*

The results in oat-cell carcinoma compare favourably with those obtained by radiotherapy or other cytotoxic drugs. Cyclophosphamide has definite advantages over these in low toxicity, ease of administration, rapidity of response, effectiveness of oral maintenance therapy, and the fact that it can be used in very ill patients. We consider that cyclophosphamide is the treatment of choice in oat-cell carcinoma where resection is impossible.

The duration of response to cyclophosphamide is limited, but, as shown above, oat-cell tumours will respond to higher dosage, and a further intravenous course on relapse appears to give good symptomatic relief. Eventually total resistance will take place. A notable feature is the rapidity of clinical deterioration once this happens. Post-mortem examination of such cases shows a histological picture of rapid growth with no evidence of necrosis or arrested mitoses despite high circulatory levels of cyclophosphamide at the time of death. Another significant finding is the presence of active tumour tissue at those sites where there had been apparent complete regression clinically. It appears that with cyclophosphamide it is not possible to bring about complete tumour destruction, but that a small percentage of tumour cells will remain and produce recurrence.

CONCLUSIONS

We conclude that cyclophosphamide provides useful palliation in oat-cell carcinoma of the bronchus but is without value in other histological types. The ease of administration of this drug and freedom from serious side-effects make it the method of choice. Since the duration of efficacy of cyclophosphamide is limited, we believe that only patients who have significant symptoms should be treated. Once begun, however, treatment should be continued indefinitely, and further intravenous courses given as required.

SUMMARY

Forty patients suffering from advanced bronchial carcinoma who were treated with cyclophosphamide are reviewed. The selective effect of the drug in tumours of the oat-cell type is noted. It is suggested that relapses which occur while the patient is on oral maintenance therapy may be controlled by a further intravenous course of cyclophosphamide.

Full clinical and statistical details of all the patients referred to in this paper are available on application to the author.

I am indebted to Mr. H. M. Stevenson, F.R.C.S., and to Mr. T. B. Smiley, F.R.C.S., under whose care all the patients were admitted, for encouragement and advice in the preparation of this paper.

I also thank Miss M. Martin for the photographic plates and Mrs. B. Coulter for secretarial assistance.

REFERENCES

- Anders, C. J., and Kemp, N. H. (1961). Cyclophosphamide in treatment of disseminated malignant disease. *Brit. med. J.*, **2**, 1516.
- Arnold, H., and Bourseaux, F. (1958). Synthese und Abbau cyto-statisch wirksamer cyclischer N-Phosphamidester des Bis-(β -chloräthyl)-amins. *Angew. Chem.*, **70**, 539.
- and Brock, N. (1958). Chemotherapeutic action of a cyclic nitrogen mustard phosphamide ester (B518-ASTA) in experimental tumours of the rat. *Nature (Lond.)*, **181**, 931.
- Aronovitch, M., Meakins, J. F., and Groszman, M. (1960). Use of cyclophosphamide in advanced malignancies. *Canad. med. Ass. J.*, **83**, 997.
- Bergsagel, D. E., and Levin, W. C. (1960). A preclusive clinical trial of cyclophosphamide. *Cancer Chemother. Rep.*, No. 8, p. 120.
- Brock, N., and Wilmanns, H. (1958). Wirkung eines zyklischen N-Lost-Phosphamidesters auf experimentell erzeugte Tumoren der Ratte. *Disch. med. Wschr.*, **83**, 453.
- Coggins, P. R., Ravidin, G. R., and Eisman, S. H. (1959). Clinical pharmacology and preliminary evaluation of Cytosan (cyclophosphamide). *Cancer Chemother. Rep.* No. 3, p. 9.
- Dick, D. A. L., and Phillips, A. F. (1961). Clinical experience with cyclophosphamide in malignant disease. *Canad. med. Ass. J.*, **85**, 974.
- Dittrich, H. (1961). Klinische Erfahrungen mit dem Cytostatic um Endoxan. *Arzneimittel-Forsch.*, **11**, 207.
- Eckhardt, S., Sellei, C., and Hartai, F. (1959). Klinische Erfahrungen mit Endoxan. *Müch. med. Wschr.*, **101**, 2273.
- Foye, L. V., Chapman, C. G., Willett, F. M., and Adams, W. S. (1960). Cyclophosphamide, a preliminary study of a new alkylating agent. *Cancer Chemother. Rep.*, No. 6, p. 39.
- Gerhartz, H. (1959). Die Chemotherapie des Bronchialkrebses. In *Krebsforschung und Krebsbekämpfung*, Vol. 3, ed. H. Martius and H. Hartl, p. 116 (Sonderband zur *Strahlentherapie*, **41**). Urban and Schwarzenberg, Munich and Berlin.
- Algenstaedt, D., and Kessel, I. (1960). Grundlagen zur Chemotherapie mit Endoxan. *Internist (Berl.)*, **1**, 278.
- Grenville-Mathers, R., and Trenchard, H. J. (1964). Cytotoxic drugs in bronchial carcinoma. *Lancet*, **2**, 1200.
- Gross, R., and Lambers, K. (1958). Erste Erfahrungen in der Behandlung maligner Tumoren mit einem neuen N-Lost-Phosphamid-ester. *Disch. med. Wschr.*, **83**, 458.
- Healy, J. B. (1964). Cyclophosphamide in malignant disease. *Lancet*, **1**, 77.
- Hessen, H. (1960). The treatment of malignant tumours and haemoblastoses with a new phosphamide ester of nitrogen mustard. Inaugural thesis, Düsseldorf.
- Levine, B., and Weisberger, A. S. (1955). The response of various types of bronchogenic carcinoma to nitrogen mustard. *Ann. intern. Med.*, **42**, 1089.
- Papac, R., Petrakis, N. L., Amini, F., and Wood, D. A. (1960). Comparative clinical evaluation of two alkylating agents, mannitol mustard and cyclophosphamide (Cytosan). *J. Amer. med. Ass.*, **172**, 1387.
- Reeve, T. S. (1961). Treatment of malignant disease with an alkylating agent: review of 100 patients treated with 'Endoxan'. *Med. J. Aust.*, **1**, 686.
- Shnider, B. I., Gold, G., Hall, T., Dederick, M., Nevinny, H. B., Potee, K. G., Lasagna, L., Owens, A. H., Hreschyshyn, H., Selawry, D., Holland, J. F., Jones, R., Colsky, J., Franzino, A., Zubrad, C. G., Frei, E., and Brindley, C. (1960). Preliminary studies with cyclophosphamide. *Cancer Chemother. Rep.*, No. 8, p. 106.
- Watson, W. L., and Berg, J. W. (1962). Oat cell lung cancer. *Cancer (Philad.)*, **15**, 759.
- Wieland, C., and Wieland, S. (1961). Erfahrungen mit Endoxan-Behandlung. *Müch. med. Wschr.*, **103**, 2160.