

Pyopneumothorax in rheumatoid lung disease

DEWI DAVIES

From Ransom Hospital, Mansfield, Notts

Rheumatoid nodules in the lung, in the absence of exposure to mineral dust, are uncommon. Noonan, Taylor, and Engleman (1963) stated that up to that time only 13 microscopically proved cases had been reported. They added one of their own, and since then other proved cases have been added by Dumas, Gregory, and Ozer (1963), Yates (1963), Mattingly (1964, two cases), and Hindle and Yates (1965). These figures underestimate considerably the frequency of such nodules because thoracotomy or post-mortem examination are often not done. Locke (1963), for example, reported six cases, all without histological proof.

Necrosis is a regular feature of such nodules, and it is not surprising that they cavitate at times. Such cases have been recorded by Sieniewicz, Martin, Moore, and Miller (1962), Dumas *et al.* (1963), Locke (1963), Thomson (1963), Yates (1963), and Mattingly (1964). It is also recognized that nodules may disappear from lung radiographs (Sieniewicz *et al.*, 1962). This may be due to seepage of virtually all the material in the nodule into the bronchial tree and its elimination in this way.

These nodules usually lie subpleurally, and there is some doubt as to whether they arise in the pleura or from the underlying parenchyma. Because of their location it is not surprising that they are sometimes accompanied by pleural changes. The classical serous effusion of rheumatoid disease, which usually occurs in the absence of parenchymal shadowing, may be expected as an occasional complication. Such a case was recorded by Sieniewicz *et al.* (1962). In their other case they noted a localized pleural reaction over the nodule. At thoracotomy this was found to be a pleural exudate which peeled off easily to reveal an opening into a necrotic nodule. It was evident that the nodule had ruptured through the visceral pleura but had become sealed off by the exudate. A related complication may have occurred in a case described by Thomson (1963) in which nodular lung lesions, one of which was cavitated, were accompanied by a chyloform effusion. A

full description of the fluid was not given, and it was postulated that the effusion was due to lymphatic obstruction. However, as the fluid was not chyle, this is not a reasonable explanation: it seems more likely that the effusion was formed by the leakage of necrotic material from one or more nodules into the pleura.

From this evidence on the way the nodules behave, the next complication to be expected is that a freer communication should become established between the bronchial tree and the pleura through a cavitated necrotic nodule. Such a case with a sterile pyopneumothorax was described by Hindle and Yates (1965), and another is now added.

CASE REPORT

CASE 1 This patient, born in 1929, was a housewife and secretary and had not been exposed to mineral dust. In September 1961 she developed arthritis involving the hands, wrists, knees, and feet. A radiograph of the chest in October 1961 showed no abnormality. After a few months, treatment with prednisolone was started and has been continued since in variable dosage. Troublesome symptoms continued and she was admitted to hospital in November 1962.

She had active polyarthritis but no subcutaneous nodules. She was also found to have an extensive pleural rub over the left chest. The radiograph showed pleural shadowing over the periphery of the lower half of the left lung, denser at the base (Fig. 1). The erythrocyte sedimentation rate was 20 mm. in one hour (Westergren) and the serum differential agglutination test was negative on two occasions and doubtfully positive on one. The Mantoux test was positive at a dilution of 1 in 10,000.

Chloroquine was added to the treatment and continued for several months. Her general condition and arthritis improved slowly, and this improvement has been maintained since. The pleural rub persisted. In February 1963 aspiration produced a small quantity of thick pus from the pleural cavity. It contained a few pus cells, but tubercle bacilli and other organisms were not seen or grown. A needle biopsy of the parietal pleura showed fibrous tissue infiltrated with

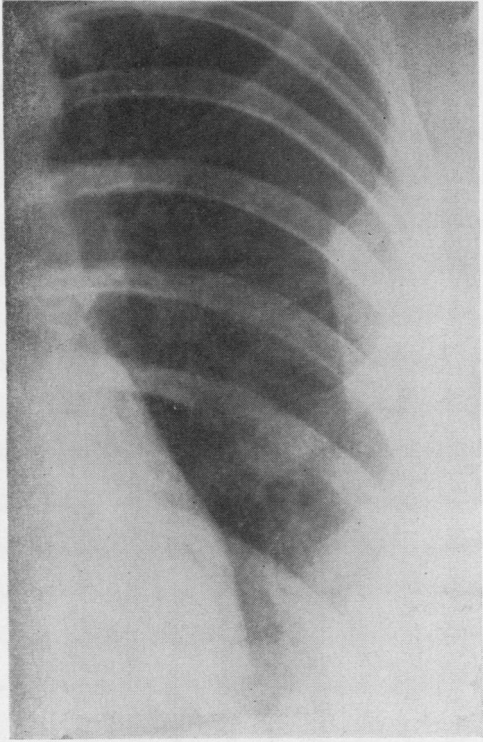
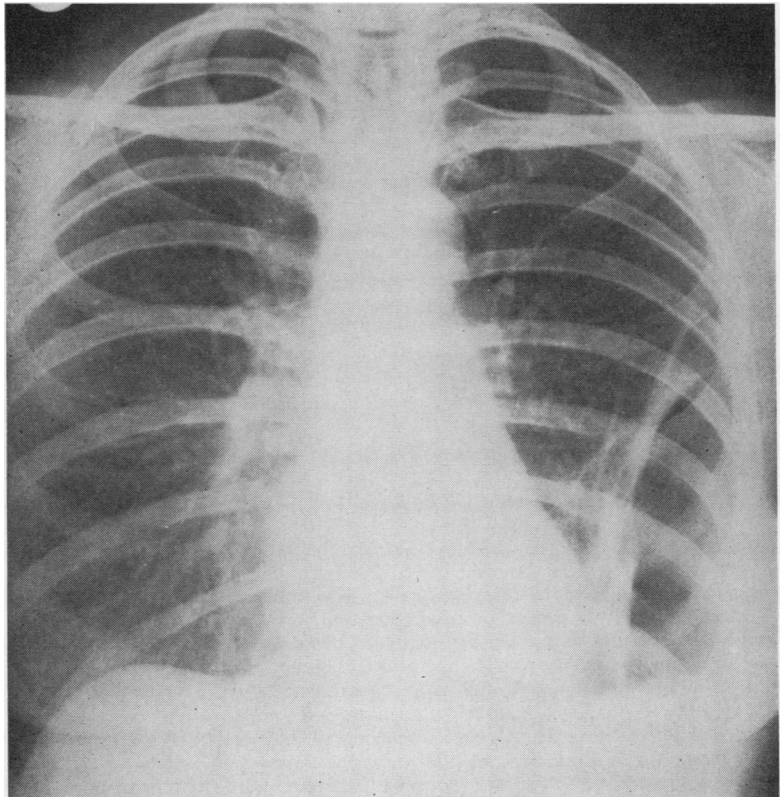


FIG. 1. *Case 1. Chest radiograph, November 1962, shows pleural shadowing over the periphery of the lower half of the left lung.*

FIG. 2. *Case 1. Chest radiograph, January 1965, shows a collection of air and fluid in the lower and lateral part of the left pleural cavity; the upper part of the lung is adherent.*



chronic inflammatory cells, without specific features. The pleural rub persisted until June 1963.

She was kept under observation and there was no significant clinical or radiological change until January 1965. The radiograph then showed a collection of air and fluid in the lower and lateral part of the left pleural cavity, the upper part of the lung being adherent (Fig. 2). She felt quite well, had a mild cough and scanty mucopurulent sputum, and had noticed slight pain in the left chest a month earlier. The arthritis was under good control and she was taking prednisolone, 7.5 mg. daily. When admitted to hospital she had low-grade fever. The haemoglobin was 10.4 g. per 100 ml., the white blood count normal, and the erythrocyte sedimentation rate 50 mm. in one hour (Westergren). The serum gave positive latex fixation and differential agglutination tests. The vital capacity was 2.4 l. and the F.E.V._{1.0} 2.2 litres. The electrocardiogram was normal.

An intercostal tube was inserted into the left pleural cavity and connected to an underwater seal. The material draining from the pleura was collected in an intermediate bottle. This was thick pus, and about 100 ml. collected in the first day. It contained polymorphs, but no organisms or fungi were found in it. Its glucose content was 13 mg./100 ml. A needle biopsy of the parietal pleura showed muscle and thickened pleura with no active inflammation.

The fluid in the tube dipping into the underwater seal bottle continued to swing, and a little pus continued to drain. Suction caused the fluid in the tube to stop swinging, but produced no continued leak of air. When suction was discontinued, swinging reappeared in a few hours. It was evident that a small leak was continuing from the lung and that the pleura would not obliterate. The intercostal tube was removed after 10 days, and the pleural air pocket then grew almost to its previous size.

It was then possible to suggest what had been happening. At some time after October 1961 she had developed a probable rheumatoid lung nodule which by November 1962 became necrotic and leaked sterile pus into the pleural cavity. The development of a pyopneumothorax about January 1965 was due either to the rupture of the nodule into the bronchial tree as well or to the establishment of a freer communication between the bronchial tree and the pleural cavity through the necrotic nodule. Tomograms confirmed the presence of a nodule underlying the thickened visceral pleura, and this contained a small cavity (Fig. 3).

At thoracotomy in March 1965 an extrapleural strip was done and the empyema cavity was opened. It contained a little straw-coloured fluid and purulent debris. When the latter was rubbed off the visceral pleura a small air leak was visible, and the underlying lung in the area was nodular and granular. The empyema was excised together with a wedge of underlying adherent lung from the lower lobe. The lung was oversewn and the chest closed with tube drainage. Her progress since then has been satisfactory.

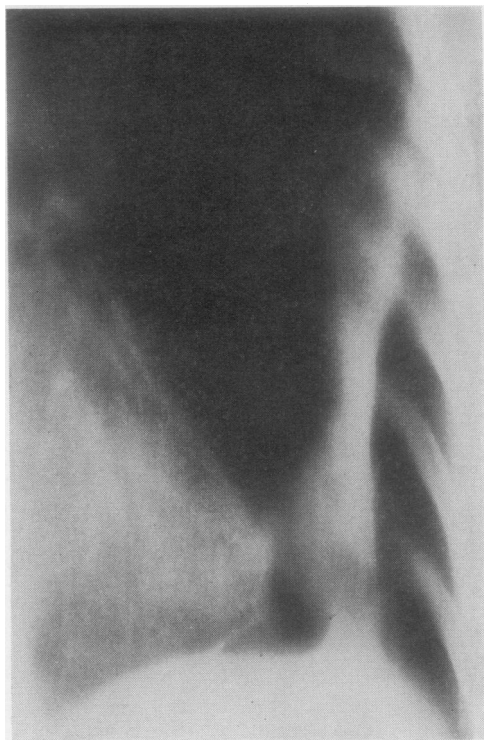


FIG. 3. Case 1. Tomogram showing a nodule underlying the thickened visceral pleura.

The resected specimen was reported on as follows: The specimen consists of a piece of pleura, both visceral and parietal layers, 10 cm. in diameter, with a wedge of lung tissue, 4 × 3 cm., adherent to it. The pleura is thickened and near the lung tissue it shows infiltration by pale yellow material. The lung contains a necrotic nodule, 2 cm. in diameter, which has ruptured into the pleura. Microscopically the sections show a typical rheumatoid nodule situated in the lung tissue, which has ruptured into the pleural cavity. The surrounding lung tissue shows chronic collapse and fibrosis with two small rheumatoid nodules outside and separate from the large nodule. These small nodules appear to be originating in the walls of bronchioles.

RHEUMATOID PNEUMOCONIOSIS

In contrast to the rarity of the type of rheumatoid lung nodules discussed above, rheumatoid pneumoconiosis is common in people exposed to mineral dust, especially coal-miners. Caplan (quoted by Mattingly, 1964) has recorded about 600 cases, and I have recognized over 70 cases in hospitals serving, in the main, a population of

about 200,000 in a coal-mining area. In most of these the radiographic evidence of dust accumulation in the lungs is slight or absent, in contrast to the findings in the ordinary form of progressive massive fibrosis. Even so, exposure to dust has a marked synergistic effect on the development of the lung nodules, and it often makes the lungs more vulnerable to the manifestations of the rheumatoid process than the joints. Only about 50% of my patients with rheumatoid pneumoconiosis suffered from or developed arthritis during observation. It is now commonplace to diagnose this condition in the absence of arthritis on the basis of the radiographic appearance of the nodules, and support is often (but not always) given by positive tests for rheumatoid factor in the serum. On the other hand, rheumatoid lung nodules of the first type described above are not being recognized in the absence of arthritis, but pleural effusions are (Ward, 1961). The presence of rheumatoid factor in the serum of people with diffuse interstitial pulmonary fibrosis without arthritis is also becoming increasingly recognized (Turner-Warwick and Doniach, 1965).

Serous pleural effusions do occur in patients

with rheumatoid pneumoconiosis (Ward, 1961; Caplan, Payne, and Withey, 1962). Cavitation of the nodules is common. Other nodules wax and wane in size, probably due to intermittent seepage of their contents into the bronchial tree. The establishment of a bronchopleural fistula through a necrotic nodule has not so far been recorded, but a case in which this appears to have happened is now described.

CASE REPORT

CASE 2 This patient, born in 1903, was a coal-miner from 1918 until 1945, when he developed pain in the right chest and was found to have clinical and radiological evidence of a right pleural effusion. Apart from sputum tests for tubercle bacilli (which were negative), no other investigations were done. The pleural shadowing decreased, but after nine months pleural thickening was still considered to be present. He was then discharged from observation. The radiographs have not been preserved.

He remained well until he developed rheumatoid arthritis in 1953, the wrists and fingers being mainly involved. The arthritis has remained active since that time, but he has not developed any subcutaneous nodules.

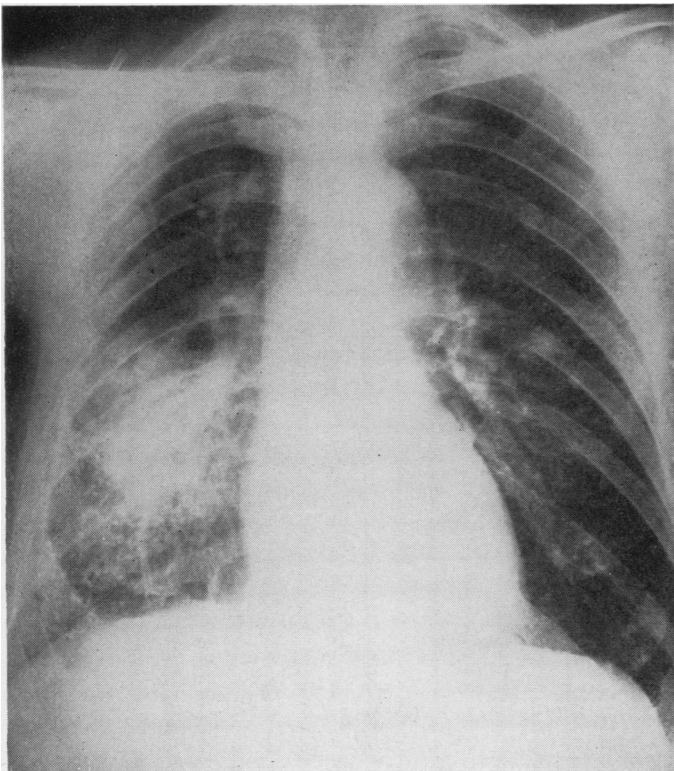


FIG. 4. *Case 2. Chest radiograph shows nodular lesions in both lungs, with more extensive shadowing and pleural calcification in the lower half of the right lung.*

When first seen in 1958 the chest radiograph (Fig. 4) showed category 1 simple pneumoconiosis. There were five fairly discrete round lesions in the right upper lobe, the largest 2.5 cm. in diameter. In the lower half of the right lung there was more extensive parenchymal shadowing with scattered pleural calcification in the lower third. There was also thickening of the pleura laterally and in the lesser fissure. Lateral films and tomograms showed that the opacity in the lower half was due to lobulated nodules in the anterior basal segment and a discrete nodule 2 cm. in diameter in the apical segment of the shrunken lower lobe. All the pleural calcification was in the region of the middle lobe, which did not contain any obvious nodules (Fig. 5). The left lung contained four nodules, the largest 1 cm. in diameter.

A film taken in 1954 was traced. It differed in that the nodules on the left were smaller and those in the right upper lobe were fewer and vaguer in outline. There was rather less pleural calcification.

He was kept under occasional observation and his sputum was repeatedly examined for tubercle bacilli. The nodules in the left lung became a little larger and those on the right tended to vary in size and to agglomerate. A little further increase in calcification occurred at the right base (Fig. 6).

In April 1963, when there was little change in his general condition, he stated that he had been coughing up a little blood on occasion for some months. The chest radiograph showed the development of a fairly

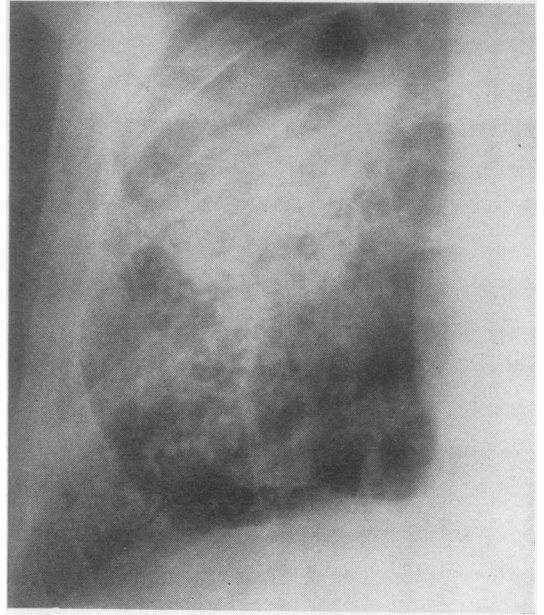


FIG. 6. Case 2. Chest radiograph shows increased pleural calcification at right base.

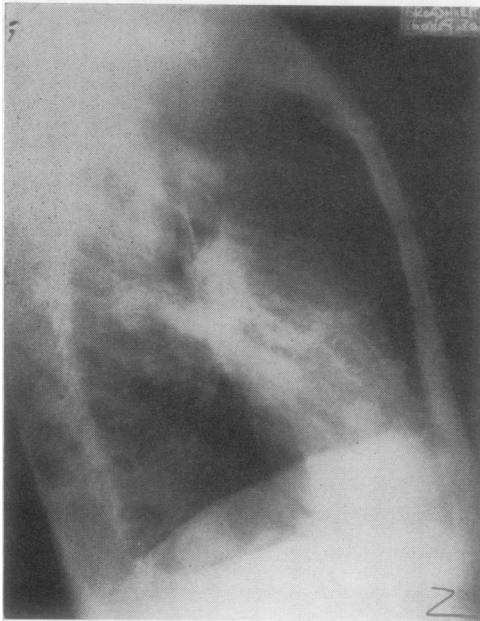


FIG. 5. Case 2. Right lateral radiograph shows nodular opacities in upper lobe, apical segment, and anterior basal segment of lower lobe. The pleural calcification lies over the middle lobe area.

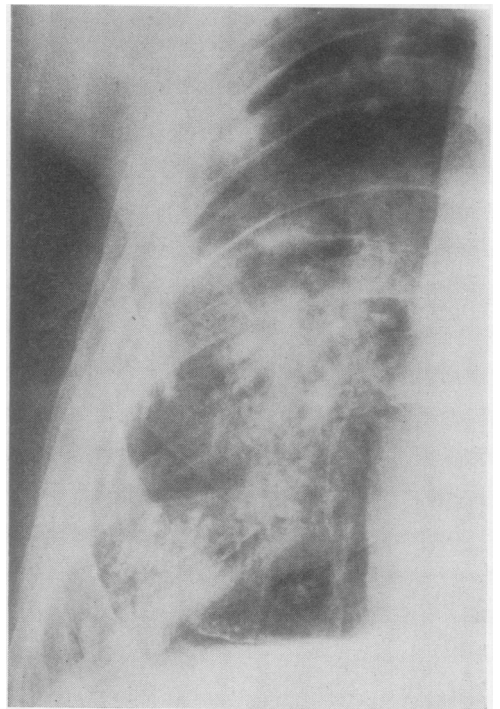


FIG. 7. Case 2. Chest radiograph shows an irregular cavity with fluid level at the right base and a redistribution of the pleural calcification.

large irregular cavity at the right base, approximately 5 cm. in diameter and containing a fluid level (Fig. 7). The other striking feature was the redistribution and agglomeration of the pleural calcification. The lateral film showed that the round lesions in the right lower lobe, which had previously increased in size, were much smaller. The fluid level, however, was anterior and the calcified pleura had become displaced backwards from behind the sternal shadow. These findings were supported by tomography, which also failed to demonstrate cavitation in the parenchyma. It was concluded that he had developed a localized pyopneumothorax over the surface of the right middle lobe, and it seemed probable that this was caused by softening and rupture of a nodule from the anterior basal segment of the lower lobe into the bronchial tree and pleura. The striking shift in the pleural calcification demonstrated clearly that the cavity was in the pleura and not in the lung.

Tubercle bacilli were grown from one sputum specimen taken at this time. The organism was sensitive to streptomycin, para-aminosalicylic acid, and isoniazid. The tuberculin skin test and the serum latex fixation test were positive. He was treated with antituberculosis drugs. Bleeding soon ceased and tubercle bacilli were not again found in the sputum. By November 1963 the radiograph no longer showed cavitation and the calcification was returning towards its former distribution. His progress since has been satisfactory.

DISCUSSION

This man's pleural effusion, which developed in 1945 and resulted in considerable pleural calcification, could have been tuberculous or rheumatoid in origin. That it developed eight years before the appearance of arthritis is against a rheumatoid aetiology. If it were tuberculous, the finding of tubercle bacilli in the sputum after the development of a bronchopleural fistula could well be explained by a release of organisms from the old pleural caseous debris. There is good evidence that viable bacilli can remain in such situations for many years. The alternative explanation is that the rheumatoid nodules had become infected by the tubercle bacillus. There is good pathological evidence that this does occur (Gough,

Rivers, and Seal, 1955), though clinically this is an uncommon complication.

SUMMARY

The behaviour of nodular lung lesions in people with rheumatoid arthritis without exposure to mineral dust is reviewed. Such nodules often cavitate and occasionally disappear. Pleural complications also occur. A patient who developed a sterile pyopneumothorax due to softening and rupture of a rheumatoid nodule is described.

Rheumatoid pneumoconiotic lung nodules are fairly common in coal-miners even in the absence of arthritis. Cavitation is a frequent feature. The case of a patient in whom such lesions were complicated by a localized pyopneumothorax is recorded.

Case 1 was originally under the care of Dr. F. W. A. Turnbull and Dr. J. Sharp. I am indebted to them for referring her and for much information. I am also indebted to Mr. J. S. A. Linton for the findings at operation and to Dr. A. MacFarlane for histological reports.

REFERENCES

- Caplan, A., Payne, R. B., and Withey, J. L. (1962). A broader concept of Caplan's syndrome related to rheumatoid factors. *Thorax*, **17**, 205.
- Dumas, L. W., Gregory, R. L., and Ozer, F. L. (1963). Case of rheumatoid lung with cavity formation. *Brit. med. J.*, **1**, 383.
- Gough, J., Rivers, D., and Seal, R. M. E. (1955). Pathological studies of modified pneumoconiosis in coal-miners with rheumatoid arthritis (Caplan's syndrome). *Thorax*, **10**, 9.
- Hindle, W., and Yates, D. A. H. (1965). Pyopneumothorax complicating rheumatoid lung disease. *Ann. rheum. Dis.*, **24**, 57.
- Locke, G. B. (1963). Rheumatoid lung. *Clin. Radiol.*, **14**, 43.
- Mattingly, S. (1964). Review article: The lungs and rheumatoid arthritis. *Ann. phys. Med.*, **7**, 185.
- Noonan, C. D., Taylor, F. B., and Engleman, E. P. (1963). Nodular rheumatoid disease of the lung with cavitation. *Arthr. and Rheum.* **6**, 232.
- Sieniewicz, D. J., Martin, J. R., Moore, S., and Miller, A. (1962). Rheumatoid nodules in the lung. *J. Canad. Ass. Radiol.*, **13**, 73.
- Thomson, W. N. (1963). Pulmonary changes in collagen diseases. *Clin. Radiol.*, **14**, 451.
- Turner-Warwick, M., and Doniach, D. (1965). Auto-antibody studies in interstitial pulmonary fibrosis. *Brit. med. J.*, **1**, 886.
- Ward, R. (1961). Pleural effusion and rheumatoid disease. *Lancet*, **2**, 1336.
- Yates, D. A. H. (1963). Clinical report: Cavitation of a rheumatoid lung nodule. *Ann. phys. Med.*, **7**, 105.