

sloughing of necrotic cells into the ductular lumen (Figure 2). This presents a necrotizing cholangiolitis of a severity not previously recognized. Only one previous case showed some evidence of cholangiolitis but to a much lesser extent.⁵

The mechanism of action of nitrofurantoin in inducing acute or chronic liver cell injury is still debated. The presence of a variety of immunologic epiphenomena, an association with HLA-B8 in chronic hepatitis¹² and the pronounced eosinophilic infiltrate in acute hepatotoxic reaction³ led to the postulate of an immune, possibly genetically mediated injury. The rarity of hepatocellular injury has also been taken as evidence of a hypersensitivity reaction.¹⁹ The evidence for this has been critically reviewed and certainly is not conclusive.¹⁴ Formation of reactive intermediates such as superoxide radicals has been found in several systems.^{20,21} Furane derivatives have been found to be hepatotoxic in mice.²² The relevance of these recent findings to toxic effects in humans is unknown.

Identifying the cause of a toxic reaction in the absence of a history of exposure can be a frustrating endeavor but, as illustrated by this case, is not necessarily a hopeless one. Cow's milk most likely served as the unsuspected vehicle for transmission of nitrofurantoin, producing a severe cholestatic hepatitis in a host of uncharacteristic age and sex for this particular drug reaction.

REFERENCES

1. Koch-Weser J, Sidel VW, Dexter M, et al: Adverse reactions to sulfisoxazole, sulfamethoxazole, and nitrofurantoin—Manifestations and specific reaction rates during 2,118 courses of therapy. *Arch Intern Med* 1971 Sep; 128:399-404
2. Holmberg L, Boman G, Boettinger LE, et al: Adverse reactions to nitrofurantoin—Analysis of 921 reports. *Am J Med* 1980 Nov; 69:733-738
3. Ernaelsteen D, Williams R: Jaundice due to nitrofurantoin. *Gastroenterology* 1961 Dec; 41:590-593
4. Cook GC, Sherlock S: Jaundice and its relationship to therapeutic agents. *Lancet* 1965 Jan 23; 1:175-179
5. Jokela S: Liver disease due to nitrofurantoin. *Gastroenterology* 1967 Aug; 53:306-311
6. Jowers LV, Shannon SR: Jaundice due to nitrofurantoin. *JSC Med Assoc* 1967 May; 63:357-358
7. Wasowska T, Krus S: Jaundice induced by nitrofurantoin treatment: Case description. *Pol Med J* 1968; 7:322-327
8. Bhagwat AG, Warren RE: Hepatic reaction to nitrofurantoin. *Lancet* 1969 Dec 20; 2:1369
9. Engel JJ, Vogt TR, Wilson DE: Cholestatic hepatitis after administration of furan derivatives. *Arch Intern Med* 1975 May; 135:733-735
10. Murphy KJ, Innis MD: Hepatic disorder and severe bleeding diathesis following nitrofurantoin ingestion. *JAMA* 1968 Apr 29; 204:396-397
11. Goldstein LI, Ishak KG, Burns W: Hepatic injury associated with nitrofurantoin therapy. *Dig Dis* 1974 Nov; 19:987-998
12. Black M, Rabin L, Schatz N: Nitrofurantoin-induced chronic active hepatitis. *Ann Intern Med* 1980 Jan; 92:62-64
13. Sharp JR, Ishak KG, Zimmerman HJ: Chronic active hepatitis and severe hepatic necrosis associated with nitrofurantoin. *Ann Intern Med* 1980 Jan; 92:14-19
14. Tolman KG: Nitrofurantoin and chronic active hepatitis (Editorial). *Ann Intern Med* 1980 Jan; 92:119-120
15. Sippel PJ, Agger WA: Nitrofurantoin-induced granulomatous hepatitis. *Urology* 1981 Aug; 18:177-178
16. Wilson JT, Brown RD, Cherek DR, et al: Drug excretion in human breast milk—Principles, pharmacokinetics, and projected consequences. *Clin Pharmacokin* 1980 Jan; 5:1-66
17. Varsano I, Fischl J, Shochet S: The excretion of orally ingested nitrofurantoin in human milk (Letter). *J Pediatr* 1973 May; 83:886-887
18. Black WD, Mackay AL, Doig PA, et al: A study of drug residues in milk following intrauterine infusion of antibacterial drugs in lactating cows. *Can Vet J* 1979 Mar; 20:354-357
19. Zimmerman HJ: Hepatotoxicity. New York, Appleton-Century-Crofts, 1978
20. Sasame HA, Boyd MR: Superoxide and hydrogen peroxide production and NADPH oxidation stimulated by nitrofurantoin in lung microsomes: Possible implications for toxicity. *Life Sci* 1979 Mar 19; 24:1091-1096
21. Jones HG: Reductive and oxidative metabolism of nitrofurantoin in rat liver. *Naunyn-Schmiedeberg's Arch Pharmacol* 1980 Dec; 315:167-175
22. Horiuchi T, Ohtsubo K, Saito M: Furfurylamide-induced hepatic necrosis in mice and its modification by phenobarbital. *Jap J Exp Med* 1976 Apr; 46:111-121

Pancreatic Involvement in Hippiel-Lindau Disease

STEPHEN BICKLER
ALAN G. WILE, MD
MARTIN MELICHAREK, MD
LOUIS RECHER, MD
Orange, California

HIPPEL-LINDAU DISEASE is an uncommon autosomal dominant disease characterized by hemangioblastomas of the retina and the central nervous system. A variety of other cystic and neoplastic lesions can be found widely dispersed throughout the body, including cysts of the abdomen and neoplasms of the kidney, adrenals and sympathetic chains. Although many clinicians are aware that retinal and cerebellar lesions occur as part of the disease, the potential for multiorgan involvement is not generally appreciated. Visceral involvement, though often clinically silent, may be present.

We describe a case of Hippiel-Lindau disease in which there was extensive pancreatic involvement in addition to lesions of the central nervous system.

Report of a Case

A 21-year-old Vietnamese man known to have retinal angiomas came to the University of California Irvine Medical Center because he had had headache, nausea, vomiting and dizziness for three weeks. He had had no weakness or sensory changes. On examination his left eye showed papilledema and increased vascularity, consistent with angioma. The patient had been observed since 1980 and had received periodic laser coagulation for preservation of his vision. He had previously undergone enucleation of the right eye because of an extensive angioma.

A computed tomographic (CT) scan of the head showed acute hydrocephalus and a large right cerebellar cyst. An angiogram showed two right-sided cerebellar hemangiomas. We excised the hemangiomas by a right suboccipital craniectomy. During the operation the surgeon found a 3-cm cyst in the posterior fossa anterior to the cerebellar hemangioma. The patient recovered from the neurosurgical procedure and his preoperative symptoms resolved.

To discover whether there was visceral involvement, an intravenous pyelogram and a CT scan of the abdomen were done. The pyelogram showed no abnormalities. A very large retroperitoneal mass could be seen on the CT scan (Figure 1). To assure that a heman-

(Bickler S, Wile AG, Melicharek M, et al: Pancreatic involvement in Hippiel-Lindau disease. *West J Med* 1984 Feb; 140:280-282.)

From the Departments of Surgery (Bickler, Wile and Melicharek) and Pathology (Recher), University of California Irvine Medical Center, Orange.

Submitted April 18, 1983.

Dr Wile was recipient of a Junior Faculty Fellowship from the American Cancer Society.

Reprint requests to Alan G. Wile, MD, Department of Surgery, University of California Irvine Medical Center, 101 City Drive South, Orange, CA 92668.

gioma was not present in this region we did an angiogram, which showed no vascular abnormalities in the retroperitoneum. The patient had no abdominal pain and results of blood chemistry studies were normal.

Because of the possibility of a malignancy, an exploratory laparotomy was done, which showed a multicystic pancreas with cysts involving the entire organ. The cystic changes were confined to the pancreas. There was no inflammatory reaction. A frozen section during the procedure showed benign polycystic disease of the pancreas. Permanent tissue sections showed normal pancreatic parenchyma interspersed with irregularly shaped cystic spaces lined by low cuboidal type epithelium (Figure 2).

Comment

The earliest observations of Hippel-Lindau disease predate by more than half a century the description of the syndrome as it is now recognized.¹ Von Hippel² is usually credited with the first clinical description of the retinal lesions, while Lindau³ recognized the association of the retinal and cerebellar lesions with the visceral components of this disease complex.

The first description of pancreatic involvement in Hippel-Lindau disease was probably in 1884 when Pye-Smith⁴ described cystic disease of the cerebellum in combination with cysts of the pancreas. Since that time lesions in virtually all other visceral organs have been described,⁴ though the kidney and pancreas are the most commonly affected visceral organs.

A variety of pancreatic lesions have been reported in the literature including cysts (both simple and multilocular), hemangioblastomas, adenomas and islet cell tumors. Cysts are the most frequently occurring pancreatic lesions. Horton and colleagues reported in 1976 that 72% of the patients they studied who had this disease had pancreatic cysts at autopsy.⁵ The cysts, which are usually multiple, may range in size from microscopic to large cavities. Despite the frequency of pancreatic involvement in Hippel-Lindau disease, the vast majority of such lesions have no clinical manifestations. In one study of 50 affected members in 9 families, only 2 of 23 patients who had pancreatic lesions diagnosed at autopsy had had clinical pancreatic involvement.⁶

Pancreatic disease in Hippel-Lindau disease may be manifested by exocrine or endocrine insufficiency. Bird and Krynauw⁶ described a case of a patient who had glucosuria and brittle diabetes. At autopsy the pancreas was found to be completely replaced by cystic tissue. A case of a patient with steatorrhea and insulin-dependent diabetes was reported by Fishman and Bartholomew.⁷ They described a slow-growing vascular tumor involving the entire pancreas and many other abdominal organs, which they concluded had led to exocrine and probably endocrine pancreatic insufficiency. Hull and co-workers⁸ reported two cases in which islet cell tumors associated with Hippel-Lindau disease were found at autopsy, though there had been no symptoms

indicating their presence during the lives of the patients.

Pancreatic disease may precede central nervous system manifestations in patients with Hippel-Lindau disease, as reported by Walter and Nygaard.⁹ Lindau³ believed that the finding of pancreatic cysts was almost pathognomonic of central nervous system lesions. When a clinician finds cystic or vascular tumors of the pancreas, it is appropriate to evaluate whether or not a patient has Hippel-Lindau disease.

Hippel-Lindau disease may involve many organs. The greatest morbidity and mortality are associated with retinal, cerebellar, spinal and medullary hemangioblastomas, pheochromocytomas and renal cell car-

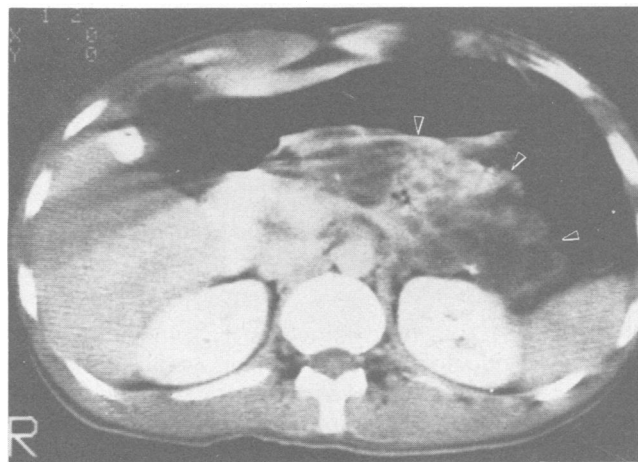


Figure 1.—Computerized tomographic scan of abdomen showing a large soft tissue mass of mixed attenuation levels (arrows). The mass extended from the upper abdomen in the retrogastric region through the retroperitoneum down to the region of the pelvic inlet. Normal pancreatic tissue was not seen. There was no evidence of any intrarenal masses or intrahepatic lesions.

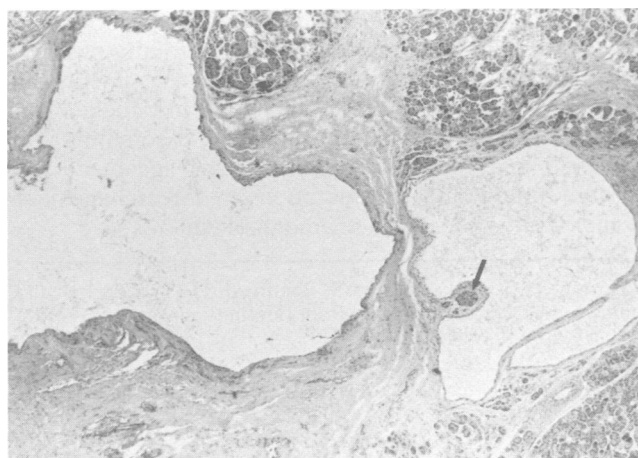


Figure 2.—Microscopic tissue section of pancreas showing irregular cystic structures containing a proteinaceous fluid. The cysts are lined by a low cuboidal epithelium. There is pericyclic fibrosis. Partially atrophic lobules of pancreatic parenchyma are present adjacent to the cysts. The arrow shows a solitary islet of Langerhans. (Reduced from magnification $\times 17$.)

cinoma. The vast majority of other lesions are usually diagnosed during a surgical procedure or at autopsy. With the advent of more sophisticated diagnostic tools, many of the visceral manifestations of Hippel-Lindau disease that previously would only be found surgically may now be detected by noninvasive methods such as CT scanning.

REFERENCES

1. Melmon KL, Rosen SW: Lindau's disease: Review of the literature and study of a large kindred. *Am J Med* 1964; 36:595-617
 2. von Hippel E: Über eine sehr seltene Erkrankung der Vetzhaut. *Von Groefes Arch Ophthalmol* 1904; 59:83

3. Lindau A: Studien über Kleinhirncysten. Bau, Pathogenese und Beziehungen für angiomatosis retinae. *Acta Pathol Microbiol Scand (Suppl 1)* 1926, pp 1-128
 4. Pye-Smith PH: Cyst of the cerebellum with numerous small cysts in the pancreas and the kidneys. *Trans R Pathol Soc [London]* 1884; 36: 17-21
 5. Horton WA, Wong V, Eldridge R: Von Hippel-Lindau disease: Clinical and pathological manifestations in nine families with 50 affected members. *Arch Intern Med* 1976; 136:769-777
 6. Bird AV, Krynauw RA: Lindau's disease in a South African family. *Br J Surg* 1953; 40:433-437
 7. Fishman RS, Bartholomew LG: Severe pancreatic involvement in three generations in von Hippel-Lindau disease. *Mayo Clin Proc* 1979 May; 54:329-331
 8. Hull MT, Warfel KA, Muller J, et al: Familial islet cell tumors in von Hippel-Lindau's disease. *Cancer* 1979; 44:1523-1526
 9. Nygaard KK, Walters W: Polycystic disease of the pancreas (dyontogenic cysts)—Report of a case with partial pancreatectomy. *Ann Surg* 1937; 106:49-53

Chemically Induced Methemoglobinemia From Aniline Poisoning

THOMAS E. KEARNEY, PharmD
 ANTHONY S. MANOQUERRA, PharmD
 JAMES V. DUNFORD, Jr, MD
 San Diego

ANILINE HAS LONG been known to be capable of producing methemoglobinemia and a Heinz-body hemolytic anemia.¹⁻⁶ Despite decades of experience, the guidelines for therapy for aniline poisoning are not well defined and are somewhat controversial.

Chemically induced methemoglobinemia may be a life-threatening condition, requiring immediate definitive management. Yet, many substances are capable of producing methemoglobin, with varied clinical courses.⁷ Similarly, the physiologic state of a patient influences both the symptoms and response to treatment of chemically induced methemoglobinemia.^{2,3,8,9}

To manage chemically induced methemoglobinemia properly, a clinician must be aware of its pathophysiology, be adept with the use of reducing agents such as methylene blue, and understand specific physiochemical properties of the toxin. The following case shows the toxicity of one methemoglobin-inducing agent and the possible pitfalls and considerations in the management of chemically induced methemoglobinemia.

(Kearney TE, Manoguerra AS, Dunford JV Jr: Chemically induced methemoglobinemia from aniline poisoning. *West J Med* 1984 Feb; 140:282-286.)

From the Division of Clinical Pharmacy, School of Pharmacy, University of California, San Francisco, San Diego Program (Dr Manoguerra); the Regional Poison Center, University of California Medical Center, San Diego (Drs Kearney and Manoguerra), and the Division of Emergency Medical Services, Department of Medicine, University of California Medical Center, San Diego (Dr Dunford). Dr Kearney is a recipient of the 1981-83 McNeil Consumer Products Company Fellowship Award in Clinical Toxicology.

Presented at the 1982 International Congress of Toxicology, the Second World Meeting of Clinical Toxicology, August 8-13, 1982, Snowmass, Colorado.

Submitted, revised, May 19, 1983.

Reprint requests to Anthony S. Manoguerra, PharmD, Director of Professional Services, Regional Poison Center, UCSD Medical Center, 225 Dickinson Street, San Diego, CA 92103-9981.

Report of a Case

The patient, a 32-year-old Mexican-American man, arrived at a San Diego emergency room, sweating, apneic and without a pulse after accidentally ingesting 0.3 to 0.6 dl (1 to 2 oz) of Moroso gasoline octane booster. The substance was in a 7-Up container when he mistakenly drank it. He ingested the product about an hour before arriving in the emergency room. The patient had attempted to induce emesis with sea water, but was unsuccessful.

The patient was extremely cyanotic; cardiopulmonary resuscitation instituted immediately upon his arrival successfully revived him and oxygen, naloxone and dextrose were administered. The San Diego Regional Poison Control Center was notified and the toxic component of Moroso was confirmed as 100% aniline. Arterial blood gas studies done while the patient was breathing 100% oxygen from an oxygen mask showed a partial arterial oxygen pressure (Pao₂) of 173 mm of mercury, a partial arterial carbon dioxide pressure (Paco₂) of 30 mm of mercury and a pH of 7.39, with an oxygen saturation of 28%. (All oxygen saturation determinations were by direct measurement with an IL 282 Co-oximeter.) A methemoglobin level determination was pending at this time. Because the patient was cyanotic and unresponsive to adequate ventilatory support, and because of the history of aniline ingestion, the diagnosis of methemoglobinemia was assumed.

A 200-mg dose of methylene blue and 500 mg of ascorbic acid were intravenously administered to the patient. Ten minutes later his color improved, he became more lucid and responsive and was able to recall the accident. The initial methemoglobin level determined just before the administration of methylene blue was greater than 70%. (Quantitative methemoglobin was determined by the method of Evelyn and Malloy^{10,11} as modified by Henry¹² using a visible spectrophotometer.) One hour after the administration of methylene blue, repeat arterial blood gas analysis showed a Pao₂ of 205 mm of mercury, a Paco₂ of 37 mm of mercury, a pH of 7.4 with an oxygen saturation of 63% and a methemoglobin level of 34%.