

Supplementary Information

Efficacy of Closed cell Self expandable Metallic Stent for Peripheral Arterial Disease in the Porcine Iliac Artery

Authors: Dae Sung Ryu^{1†}, Dong-Sung Won^{1†}, Ji Won Kim¹, Yubeen Park¹, Song Hee Kim¹, Jeon Min Kang¹, Chu Hui Zeng¹, Dohyung Lim², Hyun Choi^{2*}, Jung-Hoon Park^{1*}

Affiliations:

¹Biomedical Engineering Research Center, Asan Institute for Life Sciences, Asan Medical Center, 88 Olympic-ro 43-gil, Songpa-gu, Seoul, 05505, Republic of Korea

²Department of Mechanical Engineering, Sejong University, 209, Neungdong-ro, Gwangjin-gu, Seoul, 05006, Republic of Korea

[†]D.S.R., and D.-S.W. contributed equally to this work and are co-first authors.

^{*}H.C., and J.-H.P. contributed equally to this work and are co-corresponding authors.

Correspondence: Jung-Hoon Park, Ph.D.¹, Hyun Choi²

¹Biomedical Engineering Research Center, Asan Institute for Life Sciences, Asan Medical Center, 88 Olympic-ro 43-gil, Songpa-gu, Seoul, 05505, Republic of Korea

Tel: +82-2-3010-4123

Fax: +82-2-476-0090

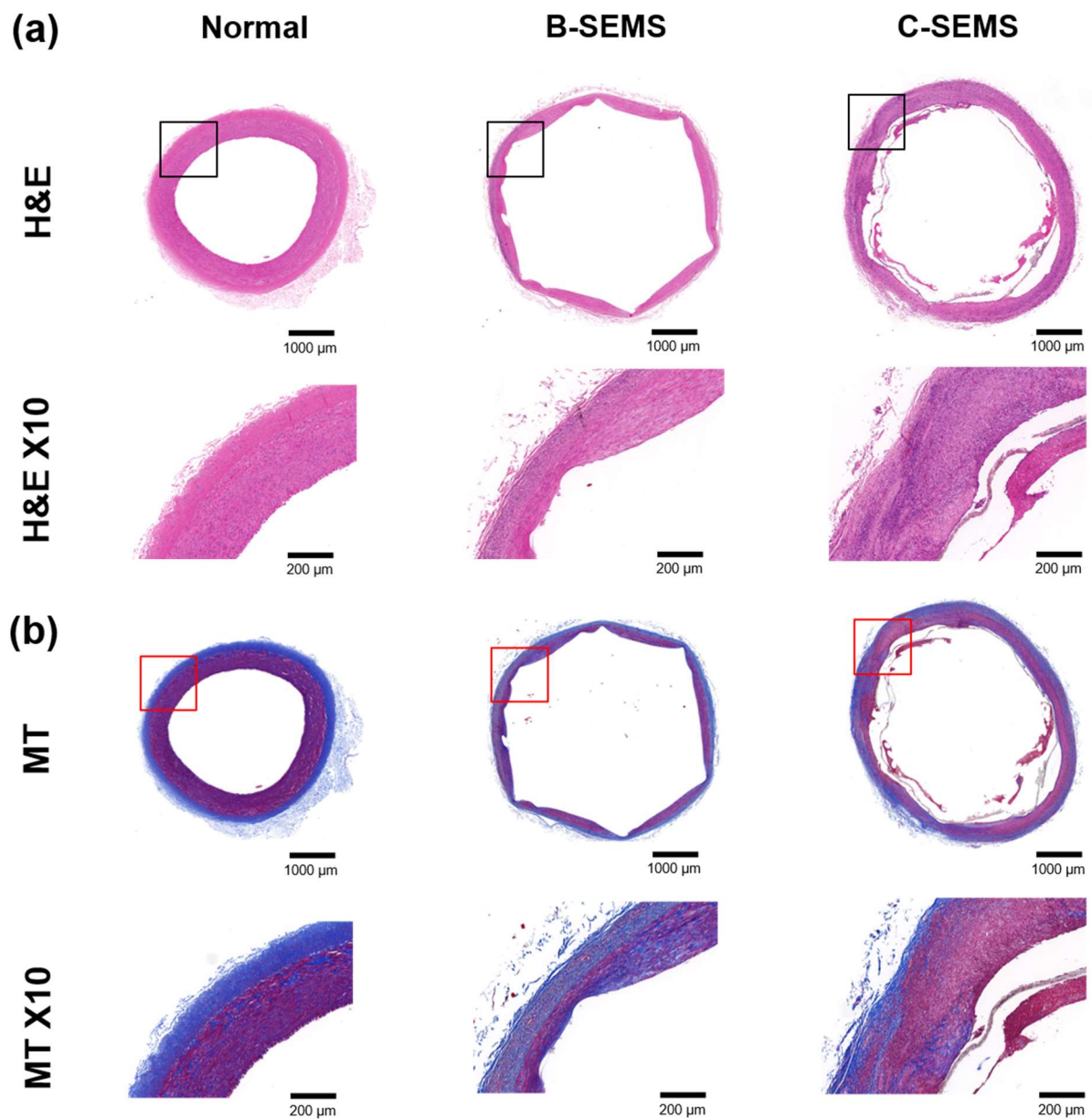
E-mail: jhparkz@amc.seoul.kr

²Department of Mechanical Engineering, Sejong University, 209, Neungdong-ro, Gwangjin-gu, Seoul, 05006, Republic of Korea

Tel: +82-2-3408-3672

Fax: +82-2-3408-4333

E-mail: godsknight96@hanmail.net



Supplementary Figure 1. Representative images showing serial histological changes in normal iliac artery, B-SEMS, and C-SEMS. (a) H&E staining with X 2 and X 10 magnifications. X 10 images indicate locations for the higher magnification (*black boxes*). (b) MT staining with X 2 and X 10 magnifications. X 10 images indicate locations for the higher magnification (*red boxes*). Note. B-SEMS: bare closed-cell self-expandable metallic stent, C-SEMS: covered closed-cell self-expandable metallic stent, H&E: hematoxylin and eosin, MT: Masson trichrome