

Posttraumatic Syringomyelia

PAUL A. LA HAYE, MD, Santa Rosa, California, and ULRICH BATZDORF, MD, Los Angeles

Posttraumatic syringomyelia is becoming increasingly recognized as a sequel to major and minor spinal cord injury, paralleling the development and widespread availability of magnetic resonance imaging as a diagnostic modality for evaluating possible spinal pathologic lesions. Delayed, subacute, or progressive neurologic deterioration in victims of traumatic spinal injury with "fixed deficits" should raise the suspicion of posttraumatic syringomyelia. Alternatively, it may present as sensory or motor complaints occurring on a delayed basis after minor spinal trauma causing no initial neurologic impairment. At our institution, we have treated six of eight patients with this condition by shunting fluid from the intramedullary cyst to the peritoneal cavity by means of a simple valveless shunt, resulting in sustained neurologic improvement in five patients.

(LaHaye PA, Batzdorf U: Posttraumatic syringomyelia. West J Med 1988 Jun; 148:657-663)

Delayed formation of an intramedullary cavity as a sequel to spinal cord trauma has been recognized in the literature since the 19th century.¹ Protean in its clinical manifestations and presentation, posttraumatic syringomyelia may produce neurologic symptoms months to years after minor spinal trauma causing no initial neurologic impairment.² Alternatively, posttraumatic syringomyelia may represent the substrate for ascending³ or anatomically remote⁴ neurologic dysfunction in victims of traumatic paraplegia, occurring months to years after the onset of a "fixed neurologic deficit" consequent to the initial injury.

In a 1966 analysis of 591 patients with posttraumatic paraplegia,⁵ a diagnosis of posttraumatic cavitation (syringomyelia) was made in 8 patients, representing an incidence of 1%. In 1981 alone, 24 new cases of posttraumatic syringomyelia were reported in the English language literature.^{1,3,6} Three separate reports in 1983 and 1984 added a total of 61 cases to the literature.⁷⁻⁹ Although no data are available to validly estimate the incidence of this condition, the longer survival of patients with severe spinal injury³ coupled with new diagnostic modalities for evaluating possible spinal cord lesions can account for the greatly increased recognition of posttraumatic syringomyelia in recent years. The improved diagnostic capabilities of computed tomography (CT) and magnetic resonance imaging (MRI) of the spinal canal and its contents have greatly facilitated the follow-up of patients with spinal cord injury and the diagnosis of syringomyelia. In this report we call attention to the importance of considering this diagnosis in patients with a history of spinal injury and to some of the clinical features of this condition. We will discuss current concepts of the diagnosis and management of this disorder.

There are several situations in which spinal cord cavitation or syringomyelia may develop; excellent comprehensive reviews of this subject are available.¹⁰ We have chosen to limit the present discussion to the posttraumatic situation, realizing that many of the concepts can be extrapolated to the larger problem of syringomyelia in general.

Patients and Methods

Eight cases of posttraumatic spinal cord cavitation have been drawn from a larger group of patients that included syringomyelia due to other causes. Six of the cases were managed with cyst-to-peritoneal shunting. An additional two patients with posttraumatic syringomyelia have been managed nonoperatively (to this point in time).

Diagnostic Measures

Patients were studied with a variety of techniques, including conventional myelography using metrizamide, metrizamide-enhanced CT, endomyelography, and MRI in the axial and sagittal planes. The evaluation was tailored for each patient, and no one patient was studied with all of these diagnostic modalities.

Operative Technique

All patients underwent the same surgical procedure. A two-level laminectomy was done with the patient in a full left lateral position (Figure 1). The laminectomy was centered at the most caudal point of the cystic cavity as shown radiographically but cephalad to the attenuated brushlike termination of the cyst, when such was present. A midline dural opening was made. A midline myelotomy of the distended cord was carried out over a distance of about 3 mm. A catheter was inserted in a cephalad direction for a distance of about 2 cm. The dura was reapproximated and the catheter secured (Figure 2). The peritoneal cavity was entered through a standard muscle-splitting incision in the right upper quadrant to allow placement of a peritoneal catheter. A subcutaneous tunnel was then fashioned between the two incisions, and the catheter within the cyst was attached to the peritoneal catheter. Flow-restricting valves were not used. Wound closures were standard. All patients had an uneventful postoperative course.

Follow-up

The follow-up time has ranged from 12 to 60 months in all

ABBREVIATIONS USED IN TEXT

CT = computed tomography
MRI = magnetic resonance imaging

patients. In some instances, postoperative radiographic or MRI studies have aided in this longitudinal assessment.

Results

An accurate clinical assessment of the results of treating posttraumatic syringomyelia is as difficult as in patients with other forms of syringomyelia. The length of time between cord injury and treatment, the duration of symptoms attributable to the cavity rather than to the original injury, and the severity and type of neurologic deficit at the time of the operation all have a bearing on the overall outcome.

All patients showed evidence of neurologic improvement following the cyst-to-peritoneal shunting. One patient (case 3) showed dramatic albeit transient abatement of disabling autonomic dysreflexia that recurred later due to a visceral triggering mechanism. The other patients have shown sustained improvement in their neurologic condition as a result of the surgical procedure. Table 1 provides a summary of the clinical data regarding this group of patients. The following case reports illustrate the spectrum of clinical presentation, diagnostic evaluation, and outcome of treatment.

Reports of Cases

Case 1. In 1964, at age 23, this patient sustained a neck injury while diving into a pool. He experienced no motor or sensory deficit, but felt electric-shocklike sensations throughout his body for several hours. Radiographs were not taken, and he was treated with cervical traction. Persistent interscapular pain without neurologic deficit led to a T1-T2 posterior fusion in 1970. He began having neurologic problems in 1974 with clumsiness and atrophy of the right hand. A minor auto accident in 1979 was followed by the develop-

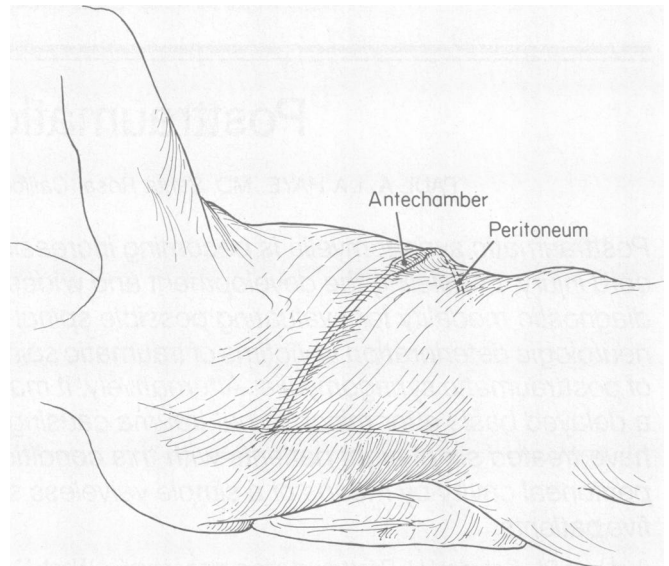


Figure 1.—The position of patient on an operating table shows the location of the antechamber over the lateral thoracic wall. This in-line antechamber allows access to the percutaneous system postoperatively.

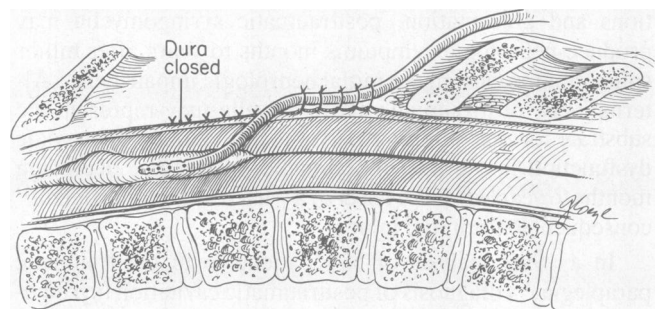


Figure 2.—The drawing shows the technique of securing shunt tubing to the dura for placing the cyst-to-peritoneal shunt.

TABLE 1.—Clinical Summary of 8 Cases of Posttraumatic Syringomyelia

Patient	Age, yr	Sex	Injury/Deficit	Interval to Onset of Symptoms	Neurologic Presentation	Diagnostic Studies (Year)	Treatment	Follow-up, yr	Outcome
1	41	♂	Diving injury/none	10 yr	Hand atrophy; weakness; spasticity; neurogenic bladder	MTZ myelogram/CT, endomyelogram (1982)	Cyst-to-peritoneal shunt	5	Improved strength, gait; spasticity unchanged
2	27	♂	Gunshot/L-1 paraplegia	12 yr	Hand weakness; sensory loss right face, arm, trunk	MTZ myelogram/CT (1982)	Cyst-to-peritoneal shunt	5	Improved strength; sensation unchanged
3	39	♂	Diving injury/C-4 quadriplegia	10 yr	Autonomic dysreflexia; muscle spasms	MTZ myelogram/CT (1982)	Cyst-to-peritoneal shunt	5	Resolution of symptoms
4	30	♂	Fall from moving vehicle/none	14 yr	Right leg pain; motor, sensory deficits; neurogenic bladder	MTZ myelogram/CT (1984)	Cyst-to-peritoneal shunt	3	All deficits lessened
5	67	♀	Auto accident/none	3 mo	Lower extremity weakness; sensory loss; neurogenic bladder	MTZ myelogram/CT (1984)	Cyst-to-peritoneal shunt	3	Improved strength; decreased sensory deficit; neurogenic bladder
6	55	♀	Fall from ladder/transient left leg weakness	10 yr	Right arm weakness; Charcot joint, right shoulder	MRI (1985)	Operation declined	1	Unchanged
7	17	♀	Auto accident/C-5 quadriplegia	6 mo	Progressive spasticity; episodic upper, lower extremity spasms	MRI (1985)	C-5 vertebratomy and fusion	1	Increasing spasticity
8	53	♀	Fall/none	2 yr	Right arm weakness and sensory deficit; mild spasticity	MRI (1986)	Cyst-to-peritoneal shunt	1	Improved strength and sensation; spasticity unchanged

CT = computed tomography, MRI = magnetic resonance imaging, MTZ = metrizamide

ment of paresthesias and weakness of the left hand. He had progressive gait deterioration with increased tone in the lower extremities beginning in 1980, along with troubling episodic spasms in the midthoracic region that gradually progressed caudally. Difficulty in initiating micturition developed, and the patient had several episodes of both urinary and fecal incontinence.

Two CT scans of the cervical and thoracic region were initially interpreted as inconclusive and as showing some degree of spondylosis in the cervical region. A third CT scan done in conjunction with a metrizamide myelogram revealed a cystic cavity within the cervical cord (Figure 3). A cyst puncture was then carried out with instillation of metrizamide, outlining the syrinx with its caudal tip at T-6 (Figure 4). A cyst-to-peritoneal shunting was done with subsequent improvement in left leg function and gait. The other neurologic deficits, including leg spasticity, have remained the same.

Case 2. In 1970, this patient sustained a gunshot wound of the spine at the T12-L1 level. He had immediate partial sensory and complete motor deficits at the L-1 level. He underwent a decompressive laminectomy and, with rehabilitation, became ambulatory with the aid of long-leg braces. He developed automatic bladder function. His neurologic condition remained stable until May 1982, when he noted numbness and a sensation of cold on the right side of the face, the right upper extremity, and the right side of the trunk. By June 1982, he noted difficulty with the use of his right hand for writing and other activities of daily living.

Myelography showed an enlarged cervical cord with widening present to the T-6 level consistent with an intramedullary cyst. A CT scan was confirmatory. The cord was not widened directly above the level of the original missile injury.

A cyst-to-peritoneal shunting was done in August 1982. His postoperative course was uneventful, and he has shown sustained improvement in the strength of his right upper extremity and is now able to write. Sensation has remained unchanged.

Case 3. In 1963, this 15-year-old boy sustained a C3-C4 fracture dislocation in a diving accident with resultant quad-

riplegia. His neurologic deficit was stable for the next decade.

In 1973, an autonomic dysreflexia began to develop, initially manifested as rigors and wide blood pressure fluctuations. His symptoms progressed over the next six years with the development of headache, facial flushing and hyperhidrosis, and truncal or lower extremity spasms triggered by simple tactile stimuli.

Metrizamide myelography and CT in 1982 revealed an extensive syrinx from C-4 to T-10. A cyst-to-peritoneal shunting afforded dramatic relief of symptoms.

In 1985 the patient had recurrent symptoms of autonomic dysreflexia. MR imaging, not available at the time of the first operation, showed that a septated portion of the syrinx had not been drained, and the shunt was modified accordingly. A subsequent recurrence of dysreflexia was attributed to cholelithiasis. Following cholecystectomy and splanchnicectomy as well as psychological support, his blood pressures stabilized, and he remains gainfully employed.

Case 4. This patient presented at age 30 with complaints of right lower extremity weakness and sensory loss. As an adolescent, he had fallen from a vehicle moving at 45 miles per hour, landing on the right side of his trunk with no resultant deficit. His symptoms began in 1980 with painful sensory loss in the right medial thigh aggravated with ac-

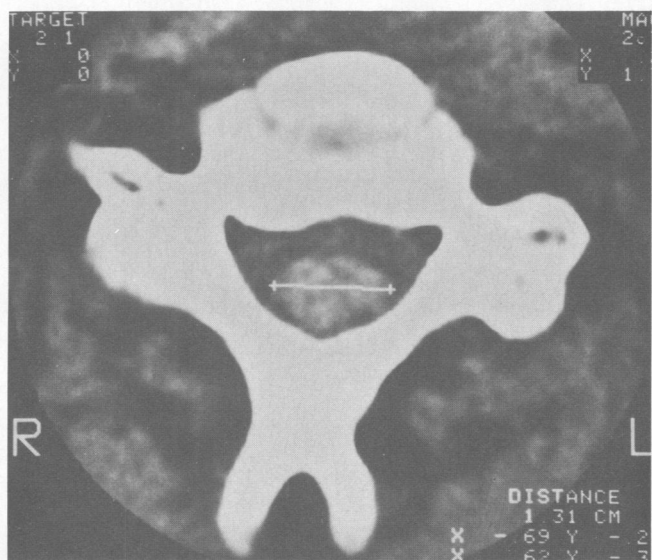


Figure 3.—Case 1: A 6-hour delayed computed tomographic scan shows accumulation of metrizamide within the cord.

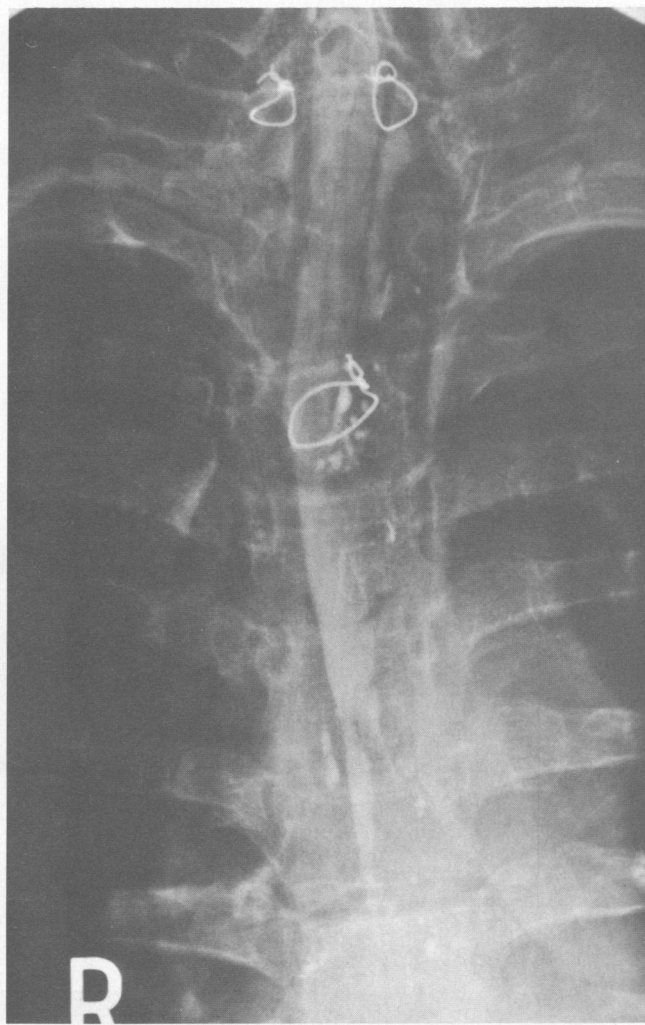


Figure 4.—Case 1: An endomyelogram following the instillation of metrizamide shows narrowing at the caudal tip of the cyst.

tivity. Attendant weakness, atrophy, and sensory loss in that extremity led to myelography in 1982 that revealed total block at T-6. Surgical exploration showed "scar tissue," and his condition was unchanged after the procedure. Progressive motor and sensory deficits with new bladder, bowel, and sexual dysfunction led to his presentation to UCLA in 1984.

On neurologic examination he had both upper and lower motor neuron deficits in the right lower extremity and bilateral extensor plantar responses. A dissociated sensory loss below T-4 was demonstrable on the right side. Metrizamide myelography revealed a block at T-6 with widening of the cord caudally. On delayed CT scanning there was a syrinx from T-6 to T-10. Cyst-to-peritoneal shunting was done with improvement in micturition and lessened motor and sensory deficits in the right lower extremity.

Case 5. This 67-year-old woman was involved in a head-on auto accident in 1982. She suffered no immediate neurologic deficit but complained of neck and thoracolumbar pain from the date of injury. Within three months of the injury, paresthesias of both lower extremities developed, followed by right lower extremity weakness and bladder dysfunction. She remained ambulatory with the aid of a walker. The patient had a history of "trivial" episodes of trauma in another accident in 1974 and a fall in 1980.

On neurologic examination in 1984 she had weakness of both lower extremities, much more so on the right than the left. Plantar response was flexor bilaterally. A dissociated sensory loss was detected below the lower thoracic level. Metrizamide myelography and CT showed a syrinx with its caudal extent at T-11. A cyst-to-peritoneal shunting resulted in dramatic improvement in strength, lessened sensory impairment, and no change in bladder dysfunction.

Case 6. This 55-year-old woman presented with complaints of weakness and numbness of the right upper extremity and decreased range of motion at the right shoulder. Ten years before this evaluation, she had fallen from a ladder with transient left lower extremity weakness that resolved over weeks.

In 1982, the patient had a posterior dislocation of the right shoulder with relatively minor mechanical stress. In 1984, she began to note a "popping" sensation in the right shoulder and a painful numbness in the right upper extremity, with the subsequent development of atrophy and weakness in

the right hand. She also noted numbness in the left lower extremity.

A neurologic examination revealed weakness and atrophy in the intrinsic musculature of the right hand. There was mild weakness in dorsiflexion and plantar flexion of the left foot. A dissociated sensory loss to pain and temperature was found on the right from C-6 to T-12 and below L-1 on the left. The right shoulder had a decreased passive range of motion.

Radiographs of the right shoulder revealed a Charcot joint, and MRI showed a cervicothoracic syrinx. Her major complaint on presentation to our service centered around the mechanical problems involving the right shoulder. Informed that such neuropathic changes would not be reversed by treatment of the syrinx and that her other deficits would remain stable or improve, she declined a shunting procedure. Her deficits have remained stable in 12 months of follow-up.

Case 7. This 17-year-old girl was involved in an auto accident in 1984, sustaining a burst fracture of C-5 with the immediate onset of quadriplegia. She was treated nonoperatively. Several months after injury, she had increasing spasticity and severe, painful spasms of the extensor musculature of the upper extremities and the flexor musculature of the lower extremities.

MRI seven months after injury revealed spinal cord compression at the C-5 level from a bony fragment of the fifth cervical vertebra. A low signal from the central region of the compressed cord was interpreted as myelomalacia or early cystic change.

In hopes of alleviating the disabling spasms, a C-5 vertebrectomy and fusion were done in 1985 but did not result in an improvement in neurologic signs or symptoms. On subsequent clinical follow-up she had a progressive increase in spasticity. Further MRI studies (Figure 5) have shown progressive cystic change within the spinal cord at this level. A surgical intervention has not been carried out to date. Her spasticity has been treated with a peripheral rhizotomy.

Case 8. This 53-year-old woman had a fall in 1980 with resultant neck pain but no neurologic deficit. Persistent cervical discomfort led to a brief series of chiropractic manipulations, halted because of exacerbation of pain. The pain resolved over the next several months without specific treatment. She had no further complaints until 1982, when she had painless "tingling" and numbness in the distal aspect of

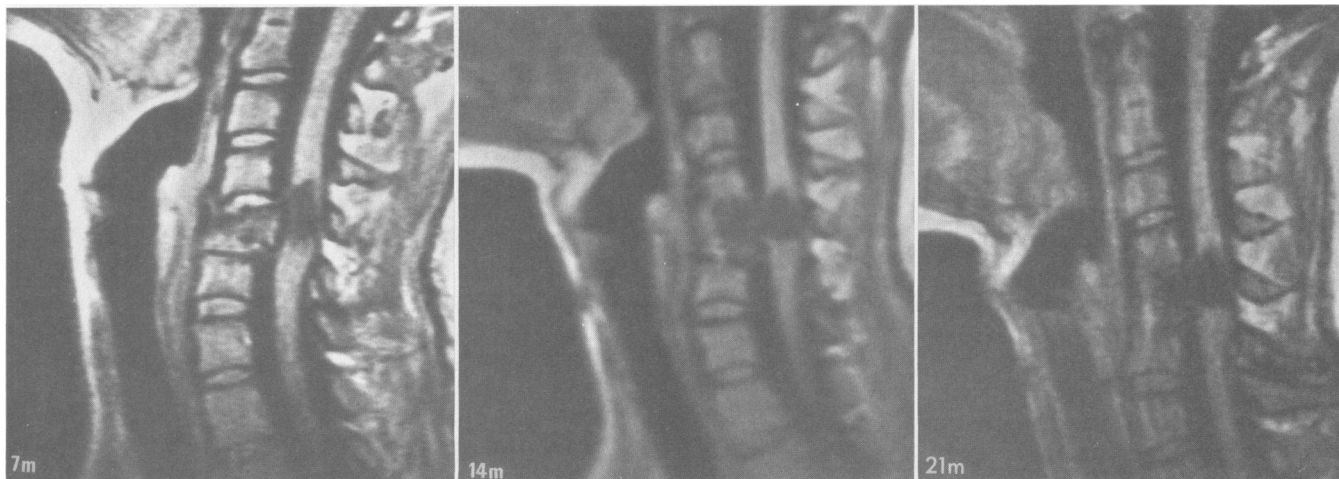


Figure 5.—Case 7: Serial magnetic resonance imaging scans dated 7 months (left), 14 months (middle), and 21 months (right) after a cervical flexion injury. The anatomic evolution of this posttraumatic spinal cord cavity is clearly delineated.

the right upper extremity. This sensation slowly advanced proximally and by 1985 was accompanied by weakness and clumsiness in the same extremity.

On neurologic examination in 1986, she had right upper extremity weakness and mild bilateral lower extremity spasticity. A dissociated sensory loss was detected on the right from C-7 to T-8. MRI revealed a syrinx from the high cervical to the upper thoracic region. A cyst-to-peritoneal shunting was done, which decreased the motor and sensory deficits, but there was no change in spasticity. The neurologic improvement has been sustained in her relatively brief follow-up.

Discussion

Attempts have been made to correlate the development of posttraumatic syringomyelia with the severity of the initial spinal trauma. Posttraumatic syringomyelia has been reported in patients with complete³ as well as partial cord lesions.^{1,11} Of interest, only three of our eight patients showed a neurologic deficit at the time of injury. There does not appear to be a consistent relationship between the severity of the original injury and the subsequent development of an intramedullary cyst. A long interval—months to years—between spinal trauma and the appearance of neurologic symptoms is also characteristic of the condition and is amply documented in other case reports.^{1,2,12}

In patients with a "fixed neurologic deficit" consequent to spinal cord injury, a posttraumatic syringomyelia manifests months to years later as exacerbation of existing motor and sensory deficits or ascending neurologic dysfunction. A long-term neurologic follow-up with detailed recording of the neurologic status will aid in the early detection of subtle deterioration and allow an early diagnostic evaluation and therapeutic intervention.

While neurologic deterioration that begins some months to years after injury of the spinal cord should raise concern about the possibility of posttraumatic syringomyelia, other pathologic processes can be responsible for the clinical changes observed. Instability of the spine at the site of injury, vascular thrombosis, arachnoid scarring, and the development of unrelated pathologic processes such as spondylosis, neoplasia, or a degenerative disorder of the nervous system must be included in the differential diagnosis.

In evaluating patients with new neurologic complaints indicative of spinal cord dysfunction and no preexisting deficit, it is important to seek a history of a blunt spinal trauma even months to years before the onset of symptoms. While relatively uncommon, posttraumatic syringomyelia must be included in the differential diagnosis, with a heightened level of suspicion in the presence of mixed upper and lower motor neuron deficits, dissociated sensory loss, and a neurogenic bladder. An insidious, progressive course seems characteristic of the condition.

Though a detailed discussion of the pathophysiology of posttraumatic syringomyelia is beyond the scope of this article and is reviewed elsewhere,¹³ a few comments regarding the probable mechanisms of cyst formation are warranted. It has been suggested that cysts develop in areas of previous liquefaction necrosis or intraparenchymal hematomas.^{3,12,14,15} While this is a likely operative mechanism of posttraumatic syringomyelia in some cases of severe spinal cord trauma, more subtle cord injuries—with some element of petechial hemorrhage or microinfarction—could set the

stage for central myelomalacia and subsequent cavity formation. Enlargement of this cavity through the hydrostatic stresses of vigorous exercise, coughing, or sneezing can eventually lead to neurologic symptoms. Additionally, the tethering effect of local posttraumatic arachnoid scarring in limiting normal cord mobility and enhancing intramedullary stresses with the extremes of axial movement has been cited as a contributing factor in the extension and enlargement of these posttraumatic cavities.¹³

In most cases reported to date, the site of spinal trauma has been thoracic or upper lumbar, with the cyst extending cephalad from the level of injury. It is also apparent, however, that cysts may extend in either direction from the site of spinal injury, that they may be septated, and that separate cysts—one above and the other below the site of trauma—may occur. This latter condition may result from septa, adhesions, or canal stenosis at the level of injury.

While conventional myelography—by showing unusual

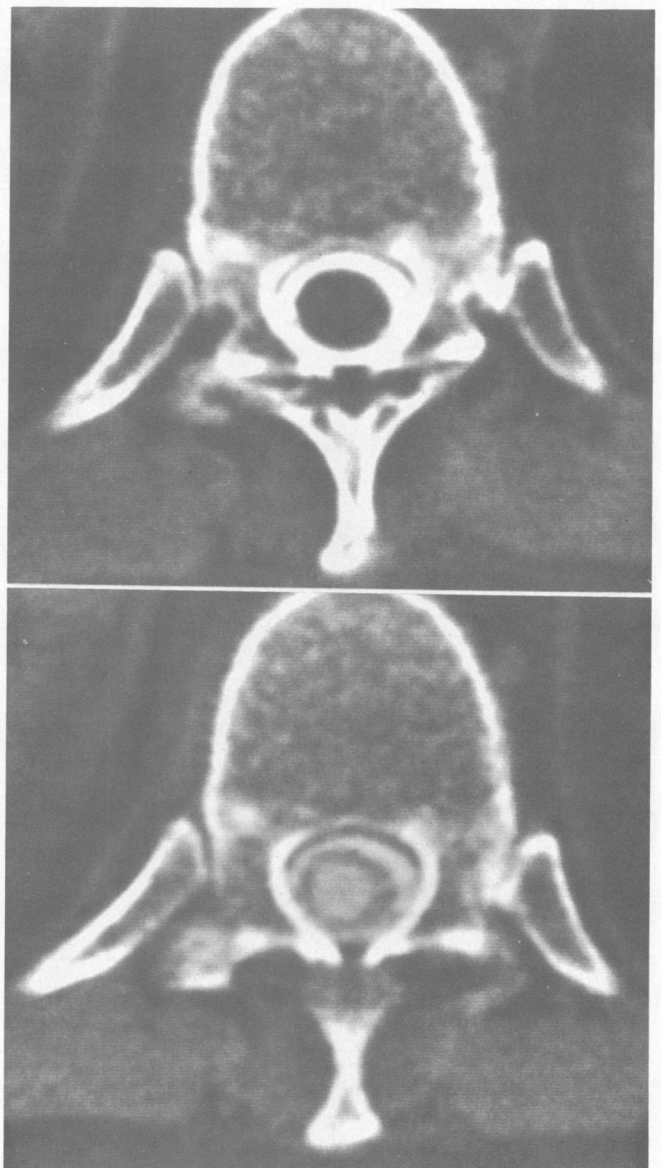


Figure 6.—Case 5: A computed tomographic (CT) scan after metrizamide myelography shows (top) an enlarged thoracic cord. A delayed CT scan (bottom) shows uptake of contrast within the intramedullary cyst.

widening of the spinal cord—may lead to the diagnosis, newer imaging techniques help to establish the precise cause of delayed neurologic deterioration. Metrizamide myelography in combination with CT scanning, including delayed views, offers an excellent means of demonstrating a cyst within the spinal cord (Figure 6). Delineating the lowest extent of the lesion is important to permit surgical drainage from the most caudal point of the cyst. When the precise anatomic outlines of the cyst are not satisfactorily delineated by CT scanning or MRI, direct cord puncture and instilling contrast material provide an excellent method of outlining the cyst.¹⁶ The use of a water-soluble contrast medium offers a distinct improvement in so-called endomyelography.¹⁷ The capability of sagittal and coronal imaging in addition to axial planes makes MRI especially appealing for studying posttraumatic syringomyelia (Figure 7). The noninvasive nature of magnetic resonance imaging also facilitates the longitudinal follow-up of patients with spinal cord injuries (Figure 5), as well as revealing collapse of the syrinx postoperatively (Figure 8).

It is apparent that with its present availability and sophistication, coupled with its noninvasive nature, MRI scanning is the diagnostic study of choice. Endomyelography is an invaluable adjunct for the evaluation of complex, septated lesions.

Because posttraumatic spinal cord cavities only rarely communicate with the fourth ventricle, the considerations

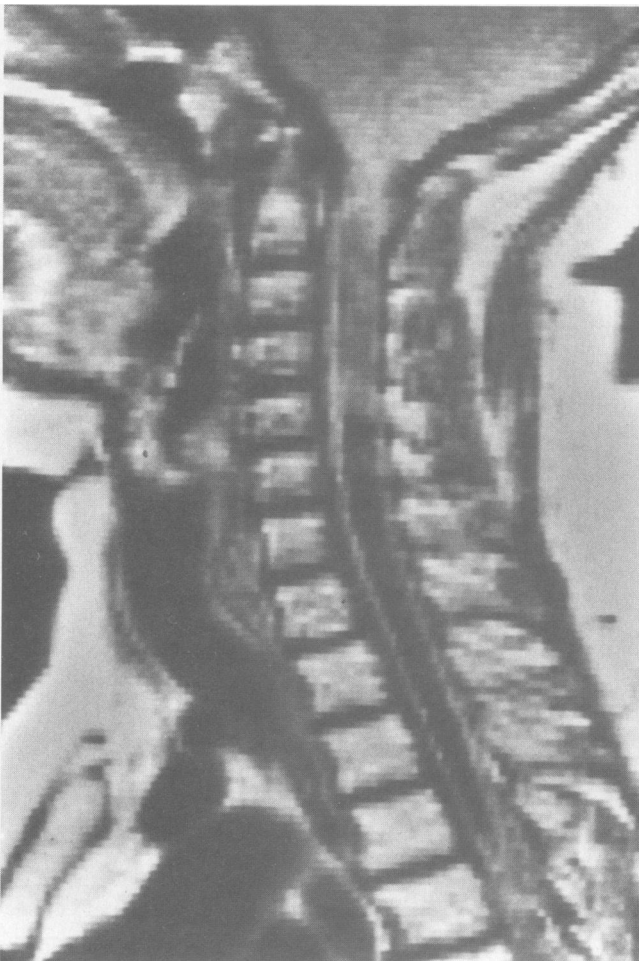


Figure 7.—Case 8: A sagittal magnetic resonance image shows the intramedullary cavity.

that apply to their treatment differ from those that apply to congenital syringomyelia associated with a Chiari malformation. The aim of surgical treatment of posttraumatic syringomyelia is to establish drainage of the cyst, thus reducing the compression from within of surrounding functional spinal cord tissue. Drainage of the cyst thereby counteracts the forces that have been postulated to act in favor of cyst extension.

Over the years, several approaches have been used to achieve drainage of intramedullary cysts. These have included myelotomy,^{7,14} cordectomy,^{1,7,11,18} cyst-to-subarachnoid shunt,^{1,7,19} and cyst-to-peritoneal shunt.^{1,7,8,20,21} Currently, shunting procedures are the preferred method of surgical treatment. We have used cyst-to-peritoneal shunting exclusively as opposed to cyst-to-subarachnoid shunts. The dense arachnoidal adhesions associated with the posttraumatic situation can make shunting into the subarachnoid space difficult if not technically impossible in many cases. Further, cyst-to-peritoneal shunting without interposition of a flow-restricting valve enhances cyst drainage by capitalizing on pressure differentials between the intramedullary cavity and the free peritoneal cavity. With cyst-to-peritoneal shunting, percutaneous access to the system by means of an in-line antechamber allows the diagnosis of a suspected shunt malfunction or infection, distinct advantages over an inaccessible cyst-to-subarachnoid shunt.

Surgical drainage of a posttraumatic spinal cord cyst into the peritoneal cavity is an effective treatment modality, but it

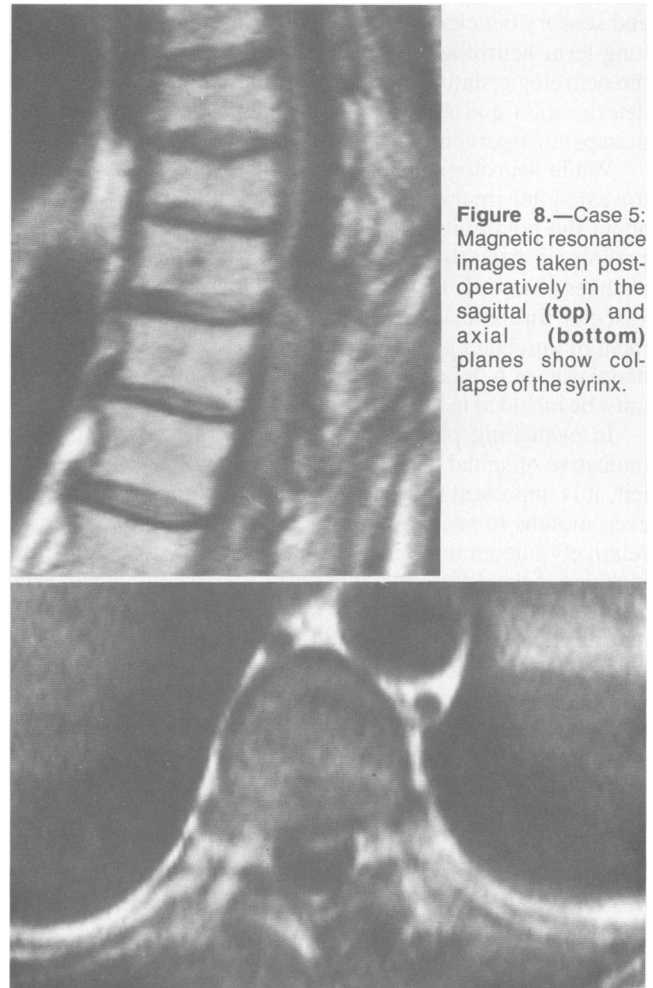


Figure 8.—Case 5: Magnetic resonance images taken post-operatively in the sagittal (top) and axial (bottom) planes show collapse of the syrinx.

should be reserved for those patients whose clinical syndrome is due to cord distention by cavity formation, with symptoms and signs appropriate to the demonstrated lesion. A progressive course certainly mandates therapy.

The burgeoning popularity and availability of MRI will certainly lead to the detection of a number of small, perhaps clinically silent, cases of posttraumatic syringomyelia. Treatment as herein described is only recommended if the lesion is clearly a source of neurologic morbidity.

Of the constellation of neurologic signs and symptoms attributable to posttraumatic syringomyelia, spasticity and dysesthetic pain (probably of central origin) seem least responsive to a shunting procedure. Aching local pain (probably due to distention of the cyst with resultant traction on pain-sensitive structures), motor deficits, and, to a lesser extent, sensory impairment are much more responsive to treatment. Progressive neurologic manifestations of this condition have been arrested, and in most instances patients' conditions are substantially improved as a result of this surgical procedure. This gratifying outcome has been sustained throughout follow-up periods.

Posttraumatic syringomyelia should be considered in any patient showing a delayed onset or progression of neurologic symptoms following spinal injury. The magnitude of the initial traumatic insult has no consonant bearing on the subsequent development of this disorder. Further, posttraumatic syringomyelia can be both temporally and spatially remote from spinal trauma. A clinical suggestion of posttraumatic syringomyelia and the thoughtful use of magnetic resonance imaging in evaluating these patients will lead to prompt diagnosis and appropriate referral. The cyst-to-peritoneal shunting offers effective treatment of this disorder.

REFERENCES

1. Shannon N, Symon L, Logue V, et al: Clinical features, investigation and treatment of post-traumatic syringomyelia. *J Neurol Neurosurg Psychiatry* 1981; 44:35-42

2. Barnett HJM: Syringomyelia consequent on minor to moderate trauma. *In* Barnett HJM, Foster JB, Hudgson P (Eds): *Syringomyelia*. London, WB Saunders, 1973, pp 174-178
3. Williams B, Terry AF, Jones F, et al: Syringomyelia as a sequel to traumatic paraplegia. *Paraplegia* 1981; 19:67-80
4. Rossier AB, Werner A, Wildi E, et al: Contribution to the study of late cervical syringomyelia syndromes after dorsal or lumbar traumatic paraplegia. *J Neurol Neurosurg Psychiatry* 1968; 31:99-105
5. Barnett HJM, Botterell EH, Jousse AT, et al: Progressive myelopathy as a sequel to traumatic paraplegia. *Brain* 1966; 89:159-174
6. Oakley JC, Ojemann GA, Alvord EC Jr: Posttraumatic syringomyelia—Case report. *J Neurosurg* 1981; 55:276-281
7. Peerless SJ, Durward QJ: Management of syringomyelia: A pathophysiological approach. *Clin Neurosurg* 1983; 30:531-576
8. Vernon JD, Silver JR, Symon L: Post-traumatic syringomyelia: The results of surgery. *Paraplegia* 1983; 21:37-46
9. Barbaro NM, Wilson CB, Gutin PH, et al: Surgical treatment of syringomyelia: Favorable results with syringoperitoneal shunting. *J Neurosurg* 1984; 61:531-538
10. Barnett HJM, Foster JB, Hudgson P (Eds): *Syringomyelia*. London, WB Saunders, 1973
11. Barnett HJM, Jousse AT: Nature, prognosis and management of posttraumatic syringomyelia. *In* Barnett HJM, Foster JB, Hudgson P (Eds): *Syringomyelia*. London, WB Saunders, 1973, pp 154-164
12. Barnett HJM, Jousse AT: Posttraumatic syringomyelia (cystic myelopathy). *In* Vinken PJ, Bruyn GW (Eds): *Handbook of Clinical Neurology*, Vol 26. Amsterdam, North-Holland, 1976, pp 113-157
13. Barnett HJM, Jousse AT, Ball MJ: Pathology and pathogenesis of cystic myelopathy. *In* Barnett HJM, Foster JB, Hudgson P (Eds): *Syringomyelia*. London, WB Saunders, 1973, pp 179-219
14. Freeman LW: Ascending spinal paralysis. *J Neurosurg* 1959; 16:120-122
15. Holmes G: Spinal injuries of warfare: I. The pathology of acute spinal injuries—The Goulstonian lectures on spinal injuries of warfare. *Br Med J* 1915; 2:769-776
16. Westberg G: Gas myelography and percutaneous puncture in the diagnosis of spinal cord cysts. *Acta Radiol* 1966; 252(suppl):1-67
17. Dietemann JL, Babin E, Wackenheim A, et al: Percutaneous puncture of spinal cysts in the diagnosis and therapy of syringomyelia and cystic tumors. *Neuroradiology* 1982; 24:59-63
18. Durward QJ, Rice GP, Ball MJ: Selective spinal cordectomy: Clinicopathological correlation. *J Neurosurg* 1982; 56:359-367
19. Tator CH, Meguro K, Rowed DW: Favorable results with syringosubarachnoid shunts for treatment of syringomyelia. *J Neurosurg* 1982; 56:517-523
20. Edgar RE: Surgical management of spinal cord cysts. *Paraplegia* 1976; 14:21-27
21. Phillips TW, Kindt GW: Syringoperitoneal shunt for syringomyelia: A preliminary report. *Surg Neurol* 1981; 16:462-466