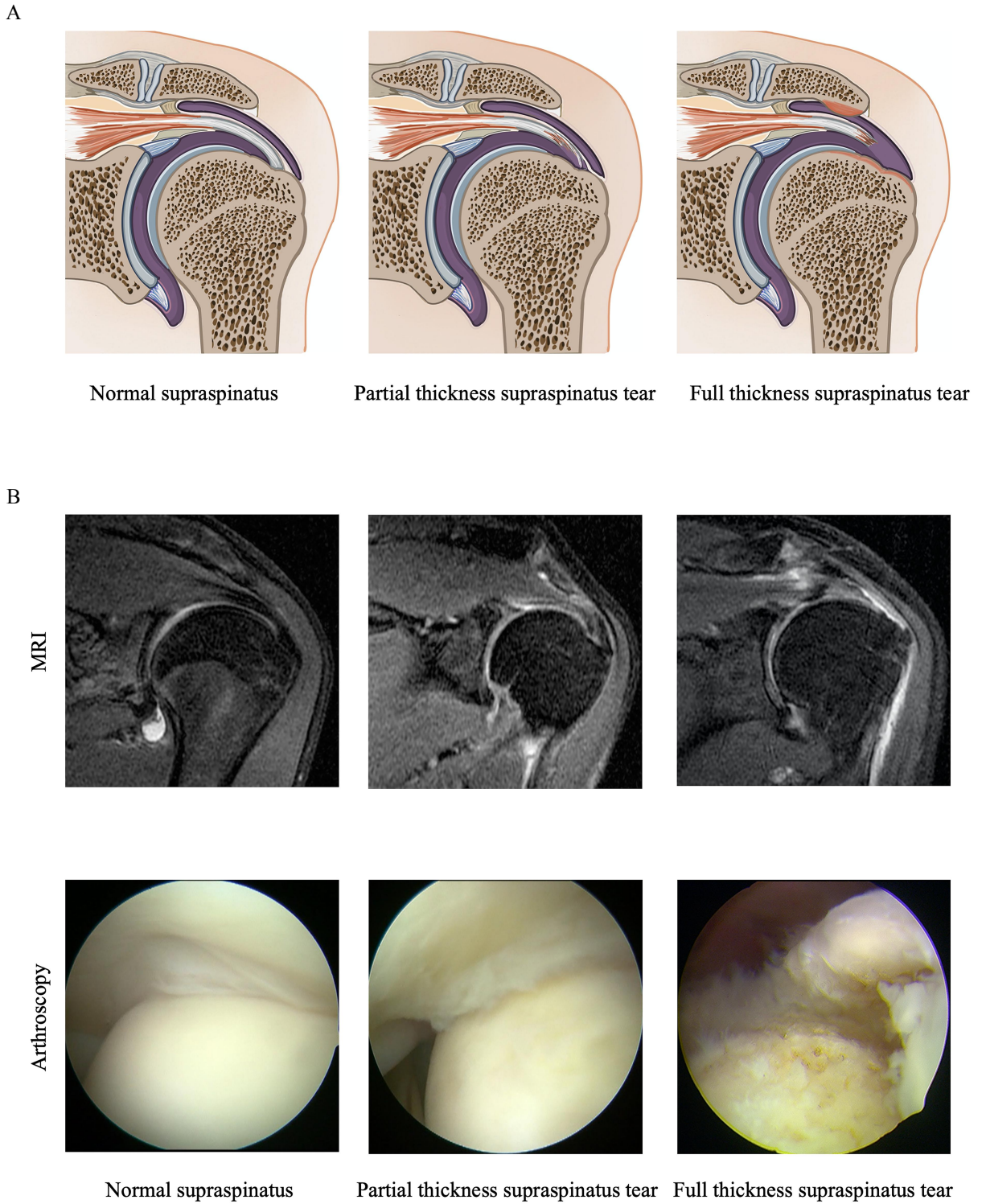


Additional Files 2



Additional Figure 2. Different ST subtypes. (a) Histological damage diagram. (b) Representative images on MRI and arthroscopy. ST, supraspinatus tear.