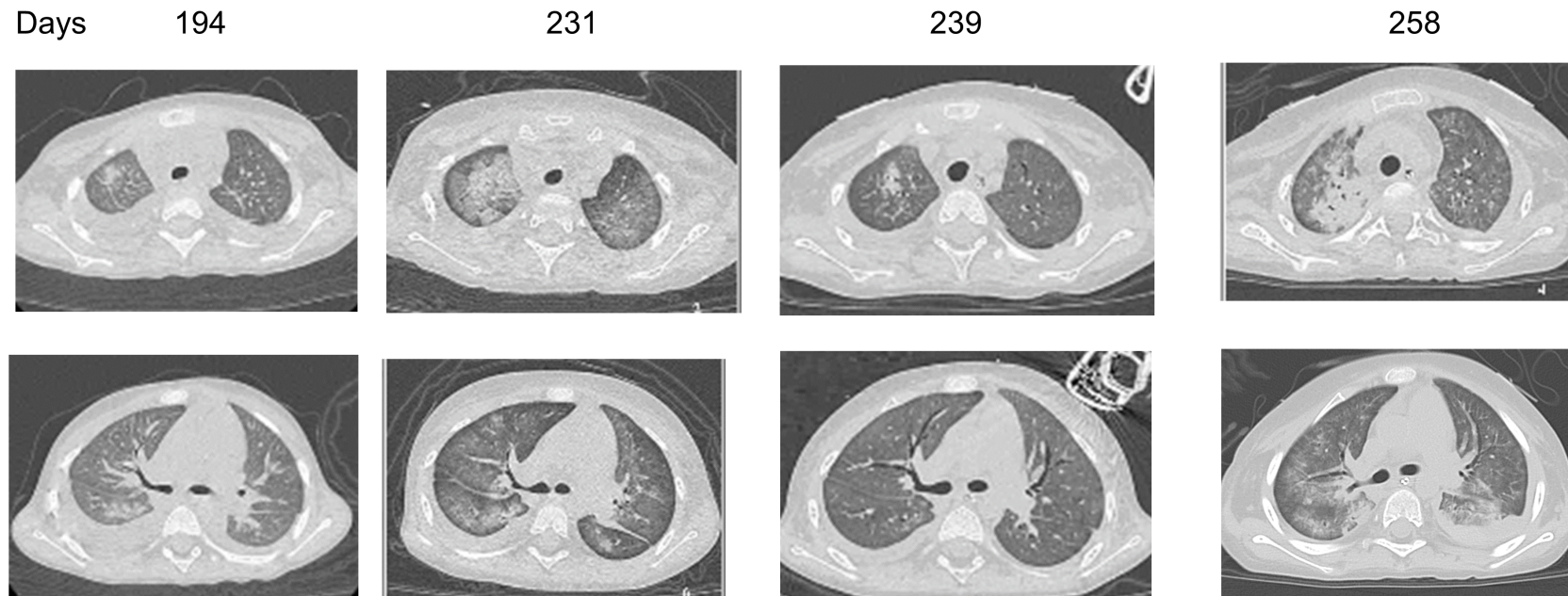


**Figure S2.** Sequential CT findings of the patient

Chest CT findings on day 194 (admission), 231 (PICU transfer), 239, and 258. Despite receiving a medium dose of prednisolone, the patient's respiratory condition deteriorated along with CT findings. After transfer to the PICU (day 231), the initiation of inhaled NO and methylprednisolone improved both PH and respiratory conditions (day 239). However, prednisolone tapering led to worsened PH and respiratory conditions along with the deterioration of CT findings (day 258).

Abbreviations: CT, computed tomography; NO, nitric oxide; PICU; pediatric intensive care unit; PH, peripheral hypertension.