

Short report

Progressive optic neuropathy and sensorineural hearing loss due to chronic glue sniffing

ABDOLREZA EHYAI, FRANK R FREEMON

From the Department of Neurology, Vanderbilt University Hospital and Veterans Administration Hospital, Nashville, Tennessee USA.

SUMMARY A 27-year-old male developed cerebral and cerebellar atrophy over a period of five years of extensive glue sniffing. He also developed bilateral optic atrophy with blindness and severe sensorineural hearing loss. Investigation failed to show any other cause for the visual or hearing loss. Peripheral polyneuropathy and central nervous system damage may follow chronic toluene toxicity, but these auditory and visual complications have not previously been described.

The acute central nervous system symptoms after inhalation of doses of toluene, the major component of glue vapour, include headache, nausea, tinnitus, ataxia, and less commonly, confusion, erratic behaviour, visual hallucination and seizures.¹⁻³ Sudden death has occurred when physical exercise followed glue sniffing; the mechanism probably involves cardiac arrhythmia. Chronic toxicity has been associated with peripheral neuropathy,^{4,5} permanent encephalopathy,⁶ cerebellar dysfunction,⁷⁻⁸ and muscle weakness.⁹ We have encountered a patient with cerebellar and cortical atrophy as well as a mild sensory peripheral neuropathy, who exhibited two additional deficits: progressive visual and hearing loss.

Case report

In 1976, a 27-year-old man complained of progressive incoordination and slurred speech of about five months duration. His relatives reported that within the same period of time they had frequently seen him sniffing glue. The patient described sniffing glue from a plastic bag several times per day for several months. He had never abused other substances except he was a heavy user of tobacco. On examination he was alert and oriented with normal memory and affect but seemed mildly intoxicated and agitated. There was a strong smell of glue on his breath. Cranial

nerve examination was normal including fundi, visual acuity and fields and hearing. Sensory and motor examination was normal as were the deep tendon reflexes. Cerebellar testing disclosed slurred and scanning speech. He had wide based, reeling gait and truncal swaying. Moderate dysmetria was noted on finger to nose and heel to shin testing. Haematological studies, liver function tests, BUN, serum electrolytes and glucose, serologic tests for syphilis, urinalysis and chest radiograph were all normal. Cranial CT scan was normal. Examination of the CSF disclosed no abnormalities; EEG and nuclear brain scan were normal and urine for drug screen was negative. One week hospital-

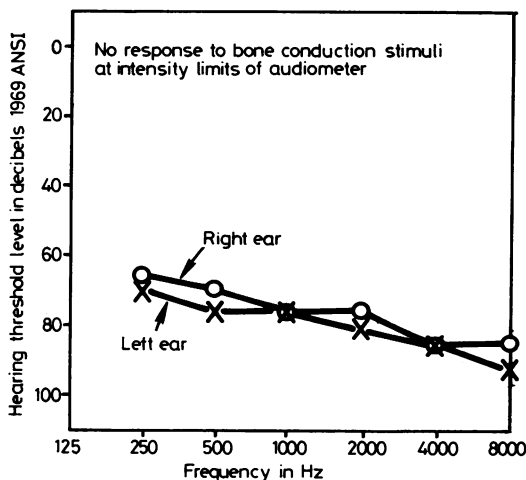


Fig 1 Audiogram shows extensive hearing loss at all frequencies in both ears.

Address for reprint requests: Dr FR Freemon, Veterans Administration Medical Center, 1310 Twenty-first, South, Nashville, Tennessee 37203, USA.

Received 24 June 1982 and in revised form 28 October 1982. Accepted 20 November 1982.

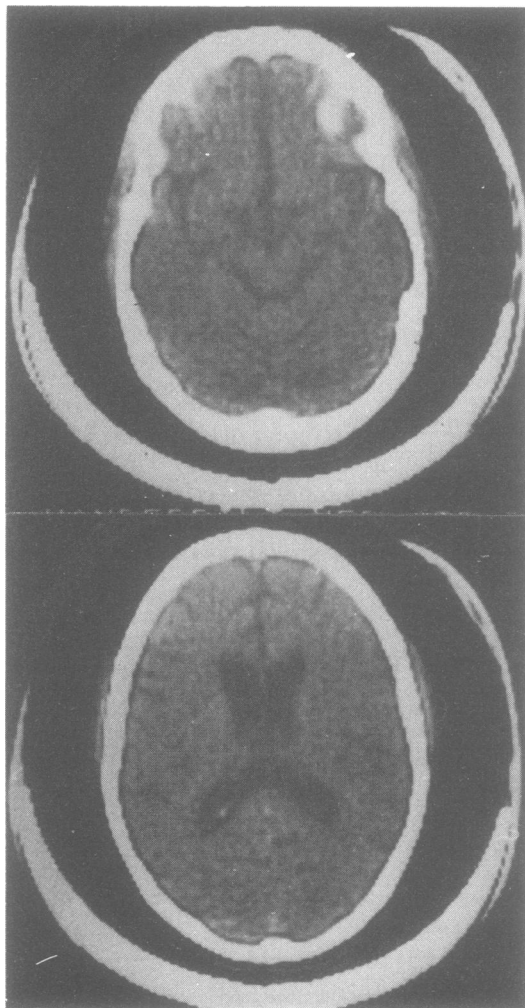


Fig 2 Computed tomographic scan shows cerebellar and cerebral cortical atrophy.

isation with no toluene exposure was associated with gradual improvement of his cerebellar functions.

Two years later very gradual decrease in his hearing and vision was noticed. These symptoms progressed and in December 1980 he reported severe difficulty with his hearing, although he denied tinnitus, dizziness or true vertigo. Otolaryngological examination showed normal external auditory canals and tympanic membranes in both ears. Nose, mouth and pharynx were normal. Tympanometry was normal bilaterally. The audiogram (fig 1) demonstrated a bilateral relatively flat sensorineural pure tone threshold shift of moderately severe to severe degree. The average for the three speech frequencies in the right ear was 73 dB and in the left ear was 77 dB hearing loss. Ophthalmological examination revealed normal pupillary

reaction and intraocular pressure. There was mild pallor of the optic discs with visual acuity 20/400 bilaterally.

In December 1981 he was readmitted to the Nashville Veterans Hospital; on examination he had decreased mental function, appeared dull, answering questions slowly and had a vacant face with smell of glue on his breath. He reported that he had sniffed glue several times per day but claimed he had discontinued use about one month previously. Marked bilateral decrease in hearing was noted with bilateral optic atrophy. The rest of the cranial nerves were normal, as well as the motor and sensory exam. Plantar responses were flexor bilaterally. Deep tendon reflexes, including ankle jerks, were normal. He had a wide based, unsteady gait, poor heel to shin test bilaterally, and mild dysmetria with a mild truncal ataxia. The patient could not walk unaided. The laboratory data showed normal haematological tests and sedimentation rate. Creatine kinase level was normal as well as liver function tests and serum proteins. Serum chloride was elevated on two occasions but sodium and potassium levels were normal. Serum bicarbonate showed marked reduction with metabolic acidosis. An anion gap of 15 meq/l was noted. Thyroid function tests, serum folate and B12 were normal and urine test for heavy metals was negative. CT scan of the head revealed cortical and cerebellar atrophy with slightly enlarged ventricles (fig 2). Electromyography and motor nerve conduction velocities in the lower extremities were normal, but no sural nerve action potential could be obtained. There was a total absence of visual evoked potentials bilaterally. Electroretinogram showed no abnormalities. No identifiable auditory evoked responses were recorded and audiometric examination at this time was consistent with severe sensorineural hearing loss. Psychological evaluation using Wechsler Adult Intelligence Scale and Wechsler Memory Scale showed a dull normal range. Comparison with similar tests administered one year ago revealed a slight decline in overall scores.

Discussion

This patient showed many neurological complications of toluene sniffing. He had ataxia and slurred speech initially improving after a few days of abstinence. Later he developed permanent cerebellar dysfunction associated with cerebellar atrophy on CT scan which was not evident four years previously. Cerebellar involvement reported with glue sniffing has been based upon clinical grounds.^{7,8} The development of cerebellar atrophy in this patient seems to be relatively rapid compared to another reported patient in whom pneumoencephalogram 13 years after the onset of ataxia still failed to show cerebellar atrophy.⁶

The patient's slight intellectual decline and mild encephalopathic features correlate well with the anatomical evidence of cerebral cortical atrophy as revealed by CT scan. Such anatomical changes have only been noted in two reported cases.⁶⁻¹⁰ Each time this patient was hospitalised for evaluation, he

became agitated and tremulous after a few days, then left the hospital. Withdrawal symptoms and delirium tremens-like state are occasionally seen in glue sniffers.¹¹ Metabolic acidosis noted in this patient seems to be a frequent complication of glue sniffing.⁹

While most of the neurological complications of toluene are seen in this patient, progressive visual and hearing loss have not previously been reported. The process of visual loss was gradual and at the earlier stages seemed to be due to retrobulbar optic neuropathy, since marked reduction of visual acuity occurred when the optic discs were of normal appearance; however, later, mild bilateral optic atrophy was seen. A specific cause for this patient's neurological and visual abnormalities was not found during five years' observation. Extensive and repeated evaluations for other causes were always unrevealing. One post mortem examination of brain indicates diffuse demyelination of corpus callosum and long tracts;¹⁰ conceivably this process could account for this patient's optic atrophy.

The sensorineural hearing loss in this patient was quite dramatic, progressing to an almost total deafness in a matter of 3 years. No specific cause of hearing loss in this patient was found by extensive and repeated examination. Damage to peripheral nerves due to organic solvents have been often reported. These peripheral neuropathies are predominantly motor in type with subacute onset. Pathologically the peripheral nerves show severe axonal lesion and myelin retraction.¹² Conceivably similar damages could occur in cranial nerves such as the acoustic nerves in this patient. The patient

had evidence of subclinical sensory neuropathy by nerve conduction studies.

References

- ¹ Press E, Done A. Physiologic effects and community control measures for intoxication from the intentional inhalation of organic solvents: 1. *Pediatrics* 1967;**39**:451-61, 611-22.
- ² Massengale ON, Glaser HH, LeLievre RE, Dobbs JB, Klock ME. Physical and psychologic factors in glue sniffing. *N Engl J Med* 1963;**269**:1340.
- ³ Brozovsky M, Winkler EG. Glue sniffing in children and adolescents. *NY State J Med* 1965;**65**:1984.
- ⁴ Korobkin R, Asbury AD, Summer AJ, Nielsen SL. Glue sniffing neuropathy. *Arch Neurol* 1975;**32**:158-62.
- ⁵ Shirabe T, Tsuda T, Terao A, Araki S. Toxic polyneuropathy due to glue sniffing. *J Neurol Sci* 1974;**21**:101-13.
- ⁶ Knox JW, Nelson FR. Permanent encephalopathy from toluene inhalation. *New Engl J Med* 1966;**275**:1494-1496.
- ⁷ Grabski DA. Toluene sniffing producing cerebellar degeneration. *Am J Psychiatry* 1961;**118**:461-2.
- ⁸ Kelly TW. Prolonged cerebellar dysfunction associated with paint sniffing. *Pediatrics* 1975;**56**:605-6.
- ⁹ Streicher HZ, Gabow PA, Moss AH, Kono D, Kaehny WE. Syndromes of toluene sniffing in adults. *Ann Int Med* 1981;**94**:758-62.
- ¹⁰ Escobar A, Aruffo C. Chronic thinner intoxication: clinico-pathologic report of a human case. *J Neuro, Neurosurg, Psychiatry* 1980;**43**:986-94.
- ¹¹ Lindstrom F. Delirium tremens as a symptom in abstinence in thinner sniffing. *Sven Lakartidn* 1960;**57**:2214-9.
- ¹² Altenkirch H, Mager J, Stoltengurg G, Helmbrecht J. Toxic polyneuropathies after sniffing a glue thinner. *J Neurol* 1977;**214**:137-52.