

## Physiologic and prognostic significance of "alpha coma"

VICENTE J IRAGUI, CHARLOTTE B McCUTCHEN

*From the Department of Neurosciences, University of California, San Diego and the Veterans Administration Medical Center, San Diego, California, USA*

**SUMMARY** A patient with posthypoxic "alpha coma" is described whose EEGs were recorded before coma, within two hours following the onset of coma and after recovery. The differences observed between the alpha activity during coma and that seen before and after suggest that the alpha activity during coma and the physiologic alpha rhythm are different phenomena. This case, as well as others reported, also suggests that "alpha coma" resolving in the first 24 hours following hypoxia may have a better prognosis than "alpha coma" detected after the first day, and stresses the need for EEG monitoring begun in the immediate period following hypoxia in order to assess accurately the prognostic significance of this EEG pattern in the early stages of postanoxic encephalopathy. The aetiology of "alpha coma" also affects outcome. The survival rate appears higher in patients with respiratory arrest than in those with combined cardiopulmonary arrest.

"Alpha coma" was first described in patients with brainstem lesions<sup>1-16</sup> and later in patients with post-hypoxic coma<sup>13-15 17-27</sup> and coma from drug overdose.<sup>14 28-31</sup> With a few notable exceptions,<sup>2 12 28</sup> the EEG prior to the onset of coma has not been available, and it remains uncertain whether this pattern represents a retained physiological alpha rhythm or is an abnormal pattern.<sup>13</sup> The prognosis of "alpha coma" has been generally considered to be poor,<sup>13 21 22 27</sup> although some patients have experienced partial or complete recovery.<sup>14 22-31</sup> In most instances, however, EEGs with alpha pattern coma have been recorded several hours or days after the onset of coma, and recordings during the first few hours of coma are scarce. This is particularly relevant since the time of recording is critical in assessing the prognostic significance of EEG patterns following cerebral hypoxia.<sup>32-34</sup> The following is a case report of a patient who recovered from posthypoxic "alpha coma" on whom we had the opportunity to record EEGs prior to the hypoxic episode, within two hours of the onset of coma, and

after recovery. The available literature is reviewed in the light of this observation.

### Case report

A 64-year-old man with hypertension and severe widespread arteriosclerotic vascular disease suffered several 2-3 minute episodes of transient loss of consciousness in 1977. Two EEGs eight months apart were performed that year. The tracings (fig 1) showed well modulated 40-50  $\mu\text{V}$ , 10 Hz activity confined to the occipital, parietal and posterior temporal regions of both hemispheres that was attenuated by eye opening. Generalised rhythmic 30-40  $\mu\text{V}$  beta activity was also noted, and was thought to be related to 15 mg oral diazepam that the patient was receiving daily. During Stage I of sleep, the alpha activity subsided and generalised rhythmic 20-30  $\mu\text{V}$ , 4-7 Hz activity appeared, most prominent over the fronto-central regions. During Stage II of sleep, physiological vertex waves as well as symmetrical 14-15 Hz sleep spindles were present. Hyperventilation elicited no significant change, and photic stimulation resulted in no consistent photoentrainment.

During the ensuing years, he developed unstable angina and suffered five myocardial infarctions. In December of 1980, he had a new myocardial infarction accompanied by congestive heart failure and acute pulmonary oedema. He received immediate care and during attempts at endotracheal intubation he became unresponsive. Examination one hour later showed him to be comatose, perspiring profusely and agitated with a respiratory rate of 35/min, pulse 90/min and blood pressure of 180/110 mm Hg. He did not follow commands or open his eyes to auditory stimulation,

Address for reprint requests: Dr Iragui, Department of Neurosciences (M-008), University of California at San Diego, La Jolla, California 92093, USA.

Received 17 June 1982 and in revised form 20 December 1982.  
Accepted 7 February 1983

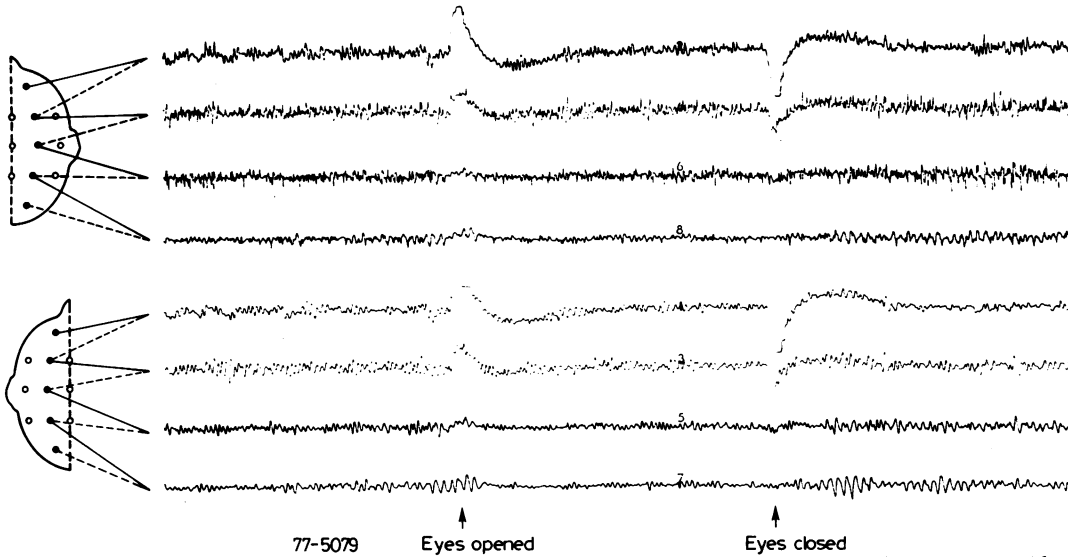


Fig 1 EEG performed prior to "alpha coma" showing a posteriorly distributed alpha rhythm that attenuates with eye opening. Time constant: 1 s. High frequency filter (-3 dB): 70 Hz.

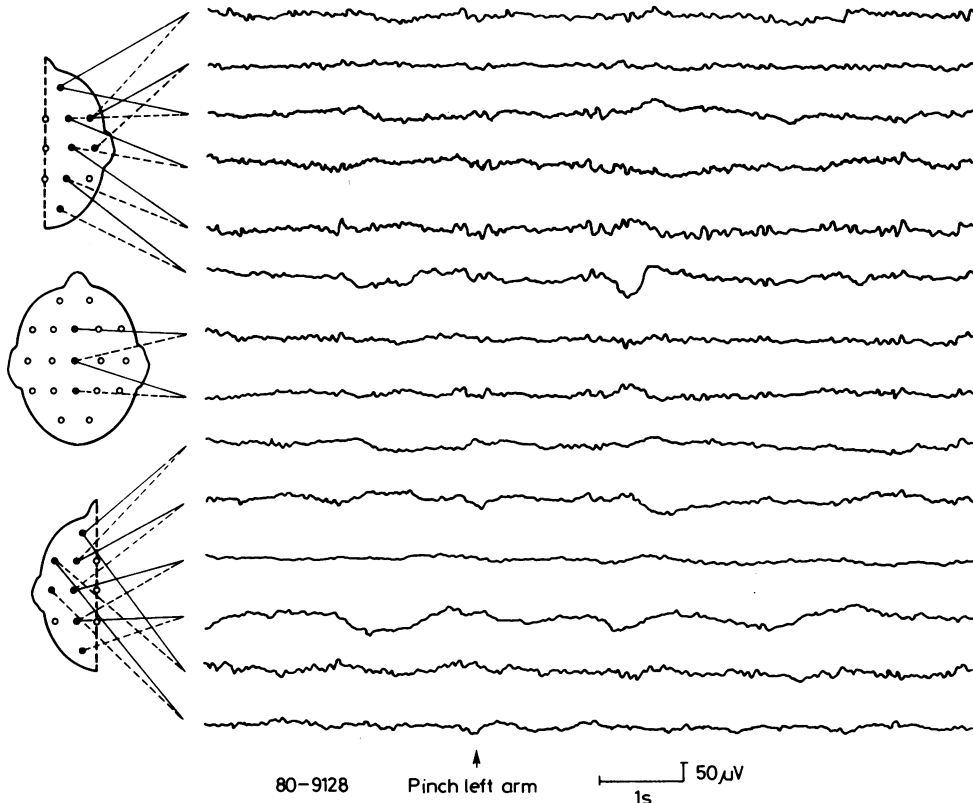


Fig 2 EEG performed within two hours after the onset of coma showing widespread unreactive alpha activity, maximal anteriorly as well as theta and delta potentials, maximal on the left side. Prominent head movement artifact from laboured respirations arising from the left occipito-parietal region obscured some portions of the tracing. The patient was perspiring profusely and sweat artifact is also present. Time constant: 1 s. High frequency filter (-3 dB): 70 Hz.

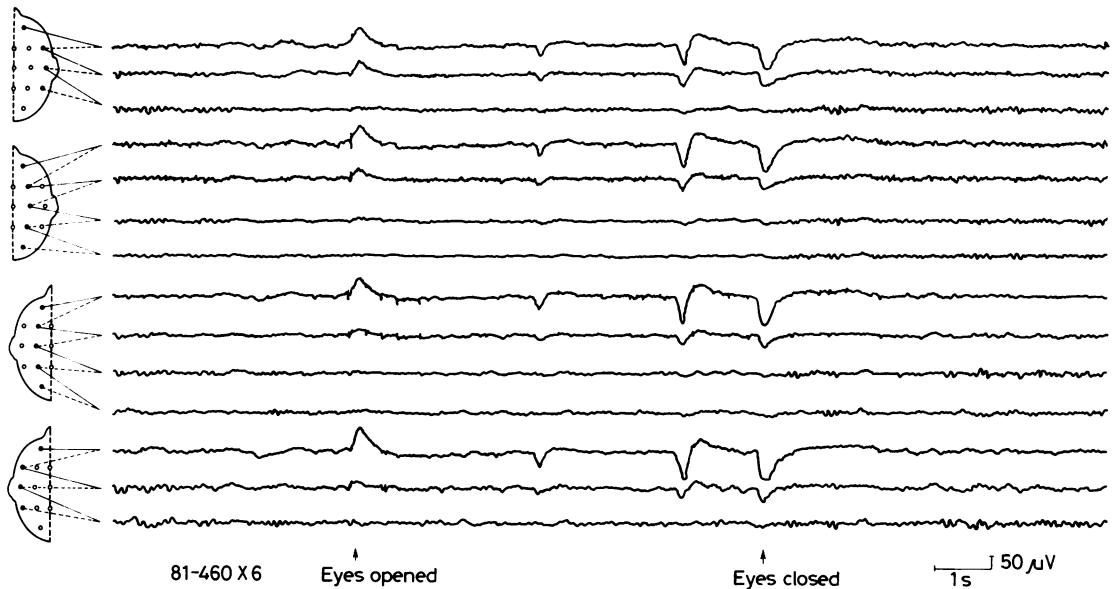


Fig 3 EEG after recovery showing posteriorly distributed, reactive alpha rhythm. Irregular theta and delta activity is most prominent in the left temporal area. Time constant: 1 s. High frequency filter (-3 dB): 70 Hz.

and he responded to pain only with incomprehensible sounds and withdrawal. His Glasgow Coma Scale rating<sup>35</sup> was 6. Pupils were equal and reacted normally to light. Roving conjugate horizontal eye movements were present and the oculocephalic responses were normal. Corneal and gag reflexes were present. The muscle tone was normal, and all extremities exhibited withdrawal to painful stimulation. Muscle stretch reflexes were normal, and there were flexor plantar responses bilaterally. The EEG performed within two hours of the onset of coma (fig 2) showed rhythmic, 20–30  $\mu\text{v}$ , 11–12 Hz activity with generalised distribution, but more prominent anteriorly and of slightly greater amplitude on the right side. This activity was fairly constant in amplitude and frequency, and did not change with painful stimulation, auditory stimulation or passive eye opening. A moderate amount of irregular, 20–40  $\mu\text{v}$ , 2–5 Hz potentials were also seen that, although generalised, had lower amplitude over the left centro-parietal region. 20–60  $\mu\text{v}$ , 0.5–1 Hz potentials were present maximally over the left centro-parietal region. Shortly after completion of the EEG, the patient underwent endotracheal intubation. He remained in coma for the next four hours. Subsequently, he exhibited gradual improvement, and twelve hours after the onset of coma he was alert and able to open his eyes to command. He followed only simple instructions and did not talk. He also had a moderate right hemiparesis as well as a right extensor plantar response, and was believed to have suffered a left hemispheric infarct. An EEG performed at that time showed generalised fairly rhythmic 20–40  $\mu\text{v}$ , 6–7 Hz theta activity. Rare potentials of 20–30  $\mu\text{v}$  and 11–12 Hz were also present diffusely. In addition, polymorphic 20–40  $\mu\text{v}$ , 1–3 Hz delta potentials were prominent over the left temporal region. The patient showed progressive neurological improve-

ment, and six months later his residual deficit was a nonfluent aphasia and he was moderately disabled according to the Glasgow Outcome Scale.<sup>36</sup> EEGs performed two and six months after the onset of coma (fig 3) showed an alpha rhythm of 20–40  $\mu\text{v}$  and 9–10 Hz confined to the occipital, parietal and posterior temporal regions of both sides. This activity was attenuated by eye opening, painful stimulation and auditory stimulation. A small amount of irregular low to medium voltage 6–7 Hz theta activity was also present diffusely. Low to medium voltage irregular 1–3 Hz delta activity was detectable over the left hemisphere, particularly the left temporal region, more so in the record performed two months after the onset of coma than in the record performed six months afterwards. No significant changes occurred with hyperventilation or photic stimulation. Sleep records were not made.

## Discussion

The present case is unique in that it demonstrates “alpha coma” in the immediate posthypoxic period in a patient who recovered and had had prior EEGs. The data from this patient combined with the available reports in the literature contribute to our understanding of: (1) the relationship of the alpha pattern in coma to the physiologic alpha rhythm, and (2) the prognostic value of early resolving “alpha pattern coma”.

Important differences were observed in our patient between the alpha activity during coma and that recorded before or after coma. Distinguishing characteristics include the frequency, amplitude,

Table 1 Alpha coma patients who recovered consciousness

Reference	Age (yr) Sex	Aetiology‡	Length of coma	Time from onset of coma to EEG	EEG during coma	EEG after coma	Outcome§
<i>Post hypoxic encephalopathy</i>							
22	53 M	CA during diabetic coma	8 d	48 h	10-11 Hz, 20-40 $\mu$ v, 6-7 Hz diffuse diffuse and fronto- cent, reactive	—	—
22	48 M	CA from anaphylaxis	not stated	48 h	9-10 Hz, 15-30 $\mu$ v diffuse unreactive	5-7 Hz diffuse	b
23	28 M	CA from electrical injury	3 wks	19 h	7-9 Hz, low amp, gen max fronto- cent, unreactive	8-10 Hz Posterior reactive	b
23	26 M	CA from electrical injury	2 wks	24 h	9-11, med. amp, gen, max fronto- central	7-8 Hz, very low voltage reactive	b
14	81 F	RA from vertebro- basilar insuff.	4 wks	*	*	*	c
14	52 F	RA from food asp.	2 mo	*	*	*	c
14	28 F	Malpositioned endotracheal tube	Not stated	*	*	*	c
24	56 M	CA	—	24 h	"alpha-coma"	—	—
25	39 M	CA from myocardial infarction	3 d	18 h	8 Hz, max. fronto- temp. unreactive	9-10 Hz and 4-7 Hz, 30-50 $\mu$ v	b
26	16 M	CA	5 d	24 h	Alpha, max. frontal reactive	"Normal"	—
26	66 M	CA	6 d	4 d	Alpha	Not reported	a
26	34 M	CA	15 d	1 d	Alpha, max. frontally unreactive	"Normal alpha"	b
41	1 <sup>19</sup> / <sub>12</sub> M	Strangulation	8 d	3 d	10-11 Hz, 50-120 $\mu$ v, gen, max middle and Post. areas, unreactive; wide- spread theta and delta	5 Hz, 40-150 $\mu$ v post. reactive; widespread theta and delta	a
37	12 M	CA	19 d	3 d	11.5 Hz, widesp read unreactive	not reported	b, c
14	34 F	RA from Elavil ingestion	24 h	*	*	*	a
14	38 F	RA from barbiturate overdose	5 d	*	*	*	a
31	41 M	RA from tranquilizers	24 h	12 h	Unreactive alpha	Normal reactive alpha	c
†	64 M	CHF from myocardial infarction	12 h	2 h	11-12 Hz, 20-30 $\mu$ v gen, max, frontal, unreactive	9-10 Hz, 20-40 $\mu$ v posterior reactive	b
<i>Brain stem lesion</i>							
12	63 F	Vertebrobasilar insufficiency	1 h	10 sec (coma onset during EEG)	12-14 and 8 Hz, 20-30 $\mu$ v unreactive	10-12 Hz 20-35 $\mu$ v reactive	a
14	68 M	Midbrain infarction	6 wks	*	*	*	b, c

Patients with alpha coma from drug overdose or head trauma are not included.

\*This study comprises 24 patients in 16 of whom the initial EEG was performed within 24 hrs after the onset of coma. The alpha activity was diffuse in 9 patients, anteriorly predominant in 11 and posteriorly predominant in 4. Sensory stimulation was performed in 18 patients, and the EEG of only one patient considered to be "locked-in" showed a response. Follow-up EEGs in 5 of the 9 survivors demonstrated a low voltage alpha rhythm that responded to visual stimulation.

†Present report.

‡CA = cardiac arrest; RA = respiratory arrest; CHF = congestive heart failure.

§a = full recovery; b = intellectual deficit, aphasia; c = motor disability, gait ataxia.

morphology, topography and/or reactivity. The premorbid alpha rhythm was of lower frequency and higher amplitude than the alpha activity during coma. It also displayed typical spindling while the alpha activity during coma was sustained and displayed little voltage modulation. The "normal"

alpha rhythm was most prominent over the posterior head regions and was reactive to sensory stimulation, whereas the alpha activity during coma was widespread and unreactive. Similar differences between alpha activity during coma and that following coma have been reported in a number of cases who

recovered from "alpha coma" (table 1). However, few reports contain an EEG taken prior to the onset of coma. Carroll and Mastaglia<sup>28</sup> reported four patients with "alpha coma" caused by drug intoxication apparently uncomplicated by cerebral hypoxia. An EEG prior to the onset of coma, available in one of the patients, showed "reactive and symmetrical 10 c/s alpha activity in a posterior distribution". An EEG during coma showed "symmetrical 10 c/s alpha activity in a fronto-central distribution which did not react to manual eye opening or to vigorous auditory or painful stimuli". An EEG following recovery was similar to the one prior to the onset of coma. The authors suggested that pharmacological depression of the brain stem reticular formation played an important role in the pathogenesis of drug-induced "alpha coma", its genesis therefore being similar to that of "alpha coma" in structural brain stem disease. Jones *et al*<sup>12</sup> reported a patient with vertebro-basilar insufficiency due to cervical osteochondrosis, in whom transient ischaemia of the brainstem resulted in coma lasting about one hour. Prior to the onset of coma, the EEG showed "a partially responsive and symmetrical alpha rhythm at 10–12 c/s of 20–35  $\mu$ v". During coma, "the dominant activity was within the alpha frequency range, chiefly at 12–14 c/s, but intermixed at times with waves of about 8 c/s; the amplitude was usually 20–30  $\mu$ v peak to peak. Auditory or painful stimuli and passive opening of the eyes were without apparent effect on the EEG." Topography was not reported. An EEG following recovery from coma was similar to the first EEG. Lundervold<sup>2</sup> studied a patient who did not recover from coma following vertebral angiography in whom post mortem examination showed a pontine lesion involving the reticular formation. The alpha activity during coma had the same amplitude, frequency and distribution as the alpha rhythm recorded before coma, but it did not react to sensory stimulation. Molofsky<sup>37</sup> reported "alpha coma" in a 12-year-old boy whose EEG at age 10 "was normal showing a well-developed 50–60  $\mu$ v 10 Hz alpha rhythm which attenuated with eye opening". An EEG on day 1 of posthypoxic coma showed "diffuse slowing comprised of low voltage polymorphic 1–2 Hz waves and small amounts of intermixed 7–8 Hz activity". On day 3, "the EEG was characterised by widespread 11.5 Hz rhythmic activity unreactive to auditory, visual or noxious stimuli". On day 10, the EEG showed "continuous polymorphic and rhythmic 5–7 Hz activity, residual 1–3 Hz waves and abnormal sleep patterns". "Alpha coma" has also been reported in three children of 2, 22 and 30 months of age though a posterior dominant rhythm in the alpha range is not typical of this age group.<sup>40–42</sup>

These observations and the findings in our patient support the interpretation that the alpha activity in comatose patients is an abnormally generated pattern different from the physiologic alpha rhythm.

Unlike our case and the paediatric case of Molofsky,<sup>37</sup> the other reports containing an EEG prior to the onset of coma are of patients whose "alpha coma" was thought secondary to drug or vascular insult to the brain stem. Apparently, there are some differences between the alpha activity in this clinical circumstance and the alpha activity in posthypoxic coma.<sup>13</sup> In patients rendered comatose by cardiac or respiratory failure, the alpha activity is either generalised or most prominent over the anterior head regions, and is usually unreactive to sensory stimulation, as in our patient.<sup>13 14 21 22</sup> Moderate amounts of theta and delta potentials are also seen<sup>21 27</sup> (fig 2). In patients with brainstem lesions, on the contrary, the alpha activity is typically maximal over the posterior head regions and may be attenuated by sensory stimulation,<sup>9 13</sup> although in some patients, stimulation failed to alter the EEG.<sup>2 5 12 14</sup> This emphasises the fact that patients with "alpha coma" have to be distinguished from those with the "locked-in syndrome". The latter patients usually have an alpha rhythm with normal topography and reactivity and are conscious, though they may appear to be in coma because they are mute and quadriplegic.<sup>14 22 38 39</sup> In these cases a reactive alpha rhythm suggests that the patient may be awake and "locked-in" rather than comatose, as pointed out by Grindal *et al*.<sup>14</sup>

The prognosis of "alpha coma" has generally been thought to be poor<sup>13 21 22 27</sup> although recovery with little or no neurological deficit has been reported in some patients<sup>14 22–31 37 41</sup> including two of the four reported paediatric cases.<sup>37 41</sup> The aetiology of the coma has bearing on the outcome (table 1). Only two of approximately 40 patients with "alpha coma" from brainstem lesions reported in the English literature survived, one of whom had significant mental and motor disability.<sup>12 14</sup> All patients with drug overdose, with or without respiratory arrest, survived without sequelae.<sup>14 28–31</sup> Though the sample is small, the survival rate of patients with posthypoxic "alpha coma" seems to be higher with respiratory arrest than with cardiopulmonary arrest (table 2). In our case, significant but incomplete clinical recovery occurred with the most important disability being a nonfluent aphasia secondary to left hemispheric infarct. Although an alpha rhythm developed with characteristic physiologic distribution and reactivity, polymorphic delta activity remained in the left temporal region as a consequence of the stroke.

The timing of electroencephalography following

Table 2 Outcome of patients with post hypoxic alpha coma

Author	No of pts.	Cardiopulm arrest pts/survivors	Respiratory arrest pts/survivors
Lindgren <i>et al</i> <sup>17</sup>	1	1/0	0/0
Brierley <i>et al</i> <sup>19</sup>	1	1/0	0/0
Vignaendra <i>et al</i> <sup>21</sup>	8	8/0	0/0
Westmoreland <i>et al</i> <sup>13</sup>	5	5/0	0/0
Chokroverty <sup>22</sup>	9	9/2	0/0
Grindal <i>et al</i> <sup>14, 23</sup>	20	14/2*	6/5†
Snyder <i>et al</i> <sup>24</sup>	2	2/1	0/0
Sorensen <i>et al</i> <sup>26</sup>	13	13/3	0/0
Alvin <i>et al</i> <sup>27</sup>	30	30/1	0/0
Obeso <i>et al</i> <sup>15</sup>	2	2/0	0/0
Kuroiwa and Furukawa <sup>31</sup>	1	0/0	1/1‡
Collins and Chatrian <sup>41</sup>	1	0/0	1/1
Molofsky <sup>37</sup>	1	1/1	0/0
Total	94	86/10	8/7

\*Cardiac arrest was secondary to electrical injury in both survivors.

†In two of the survivors, respiratory arrest was secondary to drug intoxication.

‡Respiratory arrest was secondary to drug intoxication.

hypoxia seems critical for accurate assessment of the prognostic significance of EEG patterns in post-hypoxic coma.<sup>32-34</sup> Since early onset continuous EEG monitoring in comatose patients has not been standard, the actual incidence and evolution of "alpha coma" is unknown. However, it appears from our case and from those in the literature<sup>13-15 17-27</sup> that patients with an alpha pattern detected and resolved within 24 hours after the onset of posthypoxic coma have a more favourable outcome than patients with alpha pattern discovered on or after the second day of coma (table 1). Alpha pattern not present in the initial EEGs after hypoxia but appearing in later recordings usually indicates a poor prognosis<sup>13 14 19 20 22</sup> and when it is followed after several hours by electrocerebral silence has been called "transitional alpha".<sup>43</sup> In contrast, the time at which the alpha pattern appears in patients rendered comatose by brain stem lesions does not seem to have prognostic implications.<sup>1-16</sup>

Our case is of particular interest because the alpha pattern was recorded within 2 hours of the onset of posthypoxic coma in a patient that subsequently recovered. Although EEGs during the first two hours following cardiac arrest are now seldom performed, aggressive therapy for posthypoxic encephalopathy such as the use of barbiturates may require earlier prediction of potential for recovery.<sup>44</sup> Under this circumstance, the prognostic value of the EEG pattern immediately following hypoxia may be important in selecting patients for such treatment. Transient early "alpha coma" may not be uncommon and, as our case and others<sup>12</sup> suggest, may not indicate a poor prognosis. EEG monitoring begun in the immediate period following hypoxia is needed to adequately assess the incidence of this pattern and its prognostic significance.

We thank Mr Hilary Lawrence for technical assistance and Ms Marlene Brindell and Ms Emily Maheu for assistance in the preparation of the manuscript.

#### Addendum

Janati and Erba<sup>45</sup> recently reported "alpha coma" in three children with near-drowning accompanied by cardiorespiratory arrest that required resuscitation. The EEGs recorded within 72 hours after the accident, "presented widespread delta activity superimposed by 8-13 c/sec rhythms which were either diffuse or maximal in the frontal regions. Although largely unreactive, this alpha-like activity was at times attenuated by painful stimulation". Two male children ages 3.5 and 5 years, died days after the accident. The third one, a 22-month-old girl, survived with severe neurological deficits.

#### References

- Loeb C, Poggio G. Electroencephalograms in a case with ponto-mesencephalic hemorrhage. *Electroencephalogr Clin Neurophysiol* 1953;5:295-6.
- Lundervold A, Hauge T, Loken AC. Unusual EEG in unconscious patient with brain stem atrophy. *Electroencephalogr Clin Neurophysiol* 1956;8:665-70.
- Loeb C, Rosadini G, Poggio GF. Electroencephalograms during coma. Normal and borderline records in five patients. *Neurology (Minneapolis)* 1959;9:610-8.
- Kaada BR, Harkmark W, Stokke D. Deep coma associated with desynchronization in EEG. *Electroencephalogr Clin Neurophysiol* 1961;13:785-9.
- Chatrian GE, White LE, Shaw CM. EEG pattern resembling wakefulness in unresponsive decerebrate state following traumatic brain-stem infarct. *Electroencephalogr Clin Neurophysiol* 1964;16:285-9.
- Marquardsen I, Harvald B. The electroencephalogram in acute vascular lesions of the brain stem and cerebellum. *Acta Neurol Scand* 1964;40:58-69.

- <sup>7</sup> Rohmer F, Jurtz D, Kiffer A. Etude critique de L'activite E.E.G. dans les syndromes vasculaires de tronc cerebral. *Rev Neurol (Paris)* 1965;113:279-84.
- <sup>8</sup> Radermecker J. Severe acute necrosis of the pons with long survival. Electro-clinical symptoms and absence of cerebral lesions. *Electroencephalogr Clin Neurophysiol* 1967;23:281.
- <sup>9</sup> Chase TN, Moretti L, Prensky AL. Clinical and electroencephalographic manifestations of vascular lesions of the pons. *Neurology (Minneapolis)* 1968;18:357-68.
- <sup>10</sup> Wilkus RJ, Harvey F, Ojeman LM, Lettich E. Electroencephalogram and sensory evoked potentials. Finding in an unresponsive patient with pontine infarct. *Arch Neurol* 1971;24:538-44.
- <sup>11</sup> Hughes JR, Cayaffa J, Leetsma J, Mizuna Y. Alternating "waking" and "sleep" EEG patterns in a deeply comatose patient. *Clin Electroencephalogr* 1972;3:86-93.
- <sup>12</sup> Jones BN, Binnie CD, Fung D, Hamblin JJ. Reversible coma with an EEG pattern normally associated with wakefulness. *Electroencephalogr Clin Neurophysiol* 1972;33:107-9.
- <sup>13</sup> Westmoreland BF, Klass DW, Sharbrough FY, Reagan TJ. Alpha-coma. Electrographic, clinical, pathologic and etiologic correlations. *Arch Neurol* 1975;32:713-8.
- <sup>14</sup> Grindal AB, Suter C, Martinez AJ. Alpha-pattern coma: 24 cases with 9 survivors. *Ann Neurol* 1977;1:371-7.
- <sup>15</sup> Obeso JA, Iragui MI, Marti-Masso JF, Maravi E, Teijeira JM, Carrera N, Teijeira J. Neurophysiological assessment of alpha-pattern coma. *J Neurol Neurosurg Psychiatry* 1980;43:63-7.
- <sup>16</sup> Dias A, Scott DF. Alpha coma: a case report. *Clin Electroencephalogr* 1981;12:130-2.
- <sup>17</sup> Lindgren S, Petersen I, Zwetnow N. Prediction of death in serious brain damage. *Acta Chir Scand* 1968;134:405-16.
- <sup>18</sup> Binnie CD, Prior PF, Lloyd DSL, Scott DF, Margerison JH. Electroencephalographic prediction of fatal anoxic brain damage after resuscitation from cardiac arrest. *Br Med J* 1970;4:265-8.
- <sup>19</sup> Brierley JB, Adams JH, Graham DI, Simpson JA. Neocortical death after cardiac arrest. A clinical, neurophysiological and neuropathological report of two cases. *Lancet* 1971;2:560-5.
- <sup>20</sup> Lemmi H, Hubbart CH, Faris AA. The electroencephalogram after resuscitation of cardiocirculatory arrest. *J Neurol Neurosurg Psychiatry* 1973;36:997-1002.
- <sup>21</sup> Vignaendra V, Wilkus RJ, Copass MK, Chatrian GE. Electroencephalographic rhythms of alpha frequency in comatose patients after cardiopulmonary arrest. *Neurology (Minneapolis)* 1974;24:582-8.
- <sup>22</sup> Chokroverty S. "Alpha-like" rhythms in electroencephalograms in coma after cardiac arrest. *Neurology (Minneapolis)* 1975;25:655-63.
- <sup>23</sup> Grindal AB, Suter C. "Alpha-pattern coma" in high voltage electrical injury. *Electroencephalogr Clin Neurophysiol* 1975;38:521-6.
- <sup>24</sup> Snyder BD, Ramirez-Lassepas M, Lippert DM. Neurologic status and prognosis after cardiopulmonary arrest: I. A retrospective study. *Neurology (Minneapolis)* 1977;27:807-11.
- <sup>25</sup> Møller M. "Alpha-pattern coma" and survival after cardiac arrest. *Electroencephalogr Clin Neurophysiol* 1978;44:518-22.
- <sup>26</sup> Sorensen K, Thomassen A, Wernberg M. Prognostic significance of alpha frequency EEG rhythm in coma after cardiac arrest. *J Neurol Neurosurg Psychiatry* 1978;41:840-2.
- <sup>27</sup> Alvin J, Møller M, Sindrup E, Nielsen BL. "Alpha pattern coma" following cerebral anoxia. *Electroencephalogr Clin Neurophysiol* 1979;47:95-101.
- <sup>28</sup> Carroll WM, Mastaglia FL. Alpha and beta coma in drug intoxication uncomplicated by cerebral hypoxia. *Electroencephalogr Clin Neurophysiol* 1979;46:95-105.
- <sup>29</sup> Endo M, Hirano M, Nakamura I, Kawai Y. The two survival cases of alpha-pattern coma caused by large amounts of hypnotics and neuroleptics. *Folia Psychiatrica Neurol Jap* 1980;34:451-8.
- <sup>30</sup> Guterman B, Sebastian P, Sodha N. Recovery from the alpha coma after lorazepam overdose. *Clin Electroencephalogr* 1981;12:205-8.
- <sup>31</sup> Kuroiwa Y, Furukawa T. EEG prognostication in drug-related alpha coma. *Arch Neurol* 1981;38:200.
- <sup>32</sup> Prior PF. *The EEG in Acute Cerebral Anoxia*. Amsterdam: Excerpta Medica, 1973.
- <sup>33</sup> Pampiglione G. Electroencephalographic studies after cardiorespiratory resuscitation. *Proc Roy Soc Med* 1962;55:653-62.
- <sup>34</sup> Pampiglione G, Harden A. Resuscitation after cardiocirculatory arrest. Prognostic evaluation of early electroencephalographic findings. *Lancet* 1968;1:1261-5.
- <sup>35</sup> Teasdale G, Jennett B. Assessment of coma and impaired consciousness: A practical scale. *Lancet* 1974;2:81-4.
- <sup>36</sup> Jennett B, Bond M. Assessment of outcome after severe brain damage: A practical scale. *Lancet* 1975;1:480-4.
- <sup>37</sup> Molofsky WJ. Alpha coma in a child. *J Neurol Neurosurg Psychiatry* 1982;45:95.
- <sup>38</sup> Hawkes CH, Bryan-Smyth L. The electroencephalogram in the "locked-in" syndrome. *Neurology (Minneapolis)* 1974;24:1015-8.
- <sup>39</sup> Plum F, Posner JB. *The Diagnosis of Stupor and Coma*. Philadelphia: FA Davis Co, 1980:159-60.
- <sup>40</sup> Yamada T, Stevland N, Kimura J. Alpha-pattern coma in a 2-year-old child. *Arch Neurol* 1979;36:225-7.
- <sup>41</sup> Collins AT, Chatrian GE. EEG rhythm of alpha frequency in a 22-month-old child after strangulation. *Neurology (Minneapolis)* 1980;30:1316-9.
- <sup>42</sup> Homan RW, Jones MG. Alpha-pattern coma in a 2-month-old child. *Ann Neurol* 1981;9:611-3.
- <sup>43</sup> Arfel G. Introduction to clinical and EEG studies in coma. In: Remond A, ed. *Handbook of Electroencephalography and Clinical Neurophysiology. Volume 12. Altered states of consciousness, coma and cerebral death*. Amsterdam: Elsevier Scientific Publishing Company, 1975:5-23.
- <sup>44</sup> Allen N. Life or death of the brain after cardiac arrest. *Neurology (Minneapolis)* 1977;27:805-6.
- <sup>45</sup> Janati A, Erba G. Electroencephalographic correlates of near-drowning encephalopathy in children. *Electroencephalogr Clin Neurophysiol* 1982;53:182-91.