

## *Occasional review*

# The differential diagnosis of congenital nystagmus

MICHAEL GRESTY, NICHOLAS PAGE, HILARY BARRATT

*From the MRC Neuro-Otology Unit, The National Hospital, Queen Square, London, UK*

**SUMMARY** The decision whether a nystagmus is congenital or acquired may be difficult and is of importance in patients presenting with neurological complaints. In this article, established diagnostic criteria are critically reviewed with particular emphasis on types of nystagmus waveform and their relationship to pursuit and optokinetic responses. Attention is drawn to certain acquired nystagmus which may have similar features which have hitherto been accepted as pathognomonic of congenital nystagmus. Symptoms due to congenital nystagmus are discussed and related to the oculomotor abnormalities. The importance of the characteristics of congenital nystagmus are evaluated for use in differential diagnosis.

*"Congenital nystagmus is observed at or shortly after birth and continues throughout life: it is sometimes associated with movements of the head which tend to disappear." (Walshe and Hoyt 1969).<sup>1</sup>*

Congenital nystagmus may be horizontal but on rare occasions is vertical or torsional; it is usually, but not invariably, conjugate and consists of combinations of pendular and jerk nystagmus with linear and exponential waveforms; there is frequently a null point or position of the eyes in which the nystagmus waveform affords best vision; if the null point is eccentric this leads to a head turn in the opposite direction; there may be a family history of nystagmus. Despite these variations a florid congenital nystagmus has a distinctive appearance of horizontal oscillations in all positions of gaze, often of high frequency, with irregular jerk and pendular movements.

Although congenital nystagmus is presumed to be present from birth (or early infancy) it may not be observed until later in life, when it may cause a diagnostic problem particularly if it resembles the more common forms of acquired nystagmus and neurological disease is suspected. Thus, Walshe and Hoyt state that "It may be impossible to differentiate between congenital nystagmus and that associated with disseminated sclerosis other than on the basis of history and other evidences of disseminated sclerosis".<sup>1</sup> This article discusses the characteristics

of congenital nystagmus which can be helpful in diagnosis (table, compiled from recent texts<sup>1-8</sup>) and draws attention to the acquired forms of oculomotor disorders which have similar features.

### PRESENCE OF NYSTAGMUS THROUGHOUT LIFE

We continue to encounter patients who undoubtedly have a marked congenital nystagmus which has passed unnoticed until school age and, on occasions, adult life. There are several reasons why the nystagmus has not been detected. Firstly, the null point of the nystagmus (at which the nystagmus is of minimal amplitude) may subtend a wide angle of ocular movement about the primary position of gaze in which case the nystagmus is only visible on eccentric gaze which the patient inherently avoids. Secondly, when the nystagmus waveform allows good foveation, acuity is preserved and the person is asymptomatic. In these cases the nystagmus is detected at school and armed service medicals, by opticians, and in medical examination for neurological symptoms. Some children are brought with compensatory head turn or head shaking without the nystagmus itself having been noticed by the parents.

Alternatively, the nystagmus is observed but mistaken for normal movements; it is thought to be a special feature of the child's eyes as opposed to an abnormality. For example, patients with congenital nystagmus have told us that in their youth they were said to have eyes that were "twinkling", "dancing", "roving" or "sexy"—adjectives which do not necessarily imply abnormal movement. Some normal people have frequent square wave jerks of large amplitude which are provoked by social eye contact. These "benign" square wave jerks have a superficial

Address for reprint requests: Dr M Gresty, MRC Neuro-Otology Unit, The National Hospital for Nervous Diseases, Queen Sq, London WC1N 3BG, UK.

Received 21 February 1984  
Accepted 10 March 1984

Table Characteristics and diagnostic criteria of congenital nystagmus

May be dominant or sex linked recessive trait Usually noted during first few months of life The pendular type is sometimes accompanied by head nodding Presence of a "null point" or position where nystagmus is least and vision best Sometimes accompanied by turning of the head Often absent, asymmetrical and "defective" optokinetic response Always affects two eyes conjugately* Frequent other ocular anomalies: astigmatism, convergent strabismus, hypoactive vestibulo-ocular reflexes	Cogan (1956) <sup>2</sup>
Suppressed by convergence Preservation of sufficient acuity for reading Head movements are (in some subjects) compensatory Amplitude of eye and head movements diminish during maturation Occasionally multiplanar, monocular*	Walshe and Hoyt (1969) <sup>1</sup>
Characterised by distinct waveforms (especially with exponentially increasing slow phases)	Dell'Osso and Daroff (1975) <sup>3</sup>
Binocular and uniplanar* Increased by fixation attempt No oscillopsia Sometimes superimposed latent component Absent in sleep Similar amplitude in both eyes Often an inversion of optokinetic response	Daroff et al (1978) <sup>4</sup>
Highly dependent on fixation with diminution abolition or reversal in darkness or eye closure High frequency of nystagmus "beats" unusual in acquired nystagmus Some head movements are compensatory other are "involuntary" tremors	Baloh and Honrubia (1979) <sup>5</sup>
Deranged pursuit and vestibulo-ocular suppression Pursuit (includes fast onset OKN) can be inverted	Gresty and Halmagyi (1980) <sup>6</sup> Halmagyi and Gresty (1981) <sup>7</sup> Leigh and Zee (1982) <sup>8</sup>

\*The authors would concur with Walshe and Hoyt that there are monocular and multiplanar forms of congenital nystagmus albeit these are rare and may have a different pathophysiology.

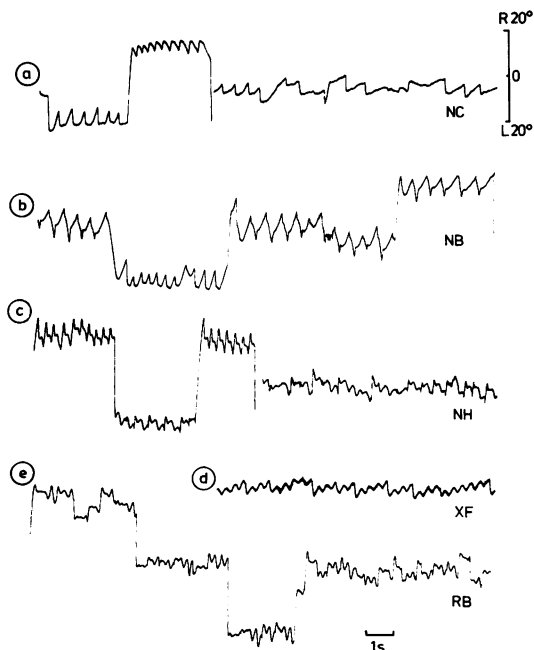
resemblance to nystagmus and may have an emotional significance (Dell'Osso and Gresty, personal observations), so it is not surprising that some nystagmus is misinterpreted as a normal phenomenon. In circumstances such as these, it may not be possible to determine whether the nystagmus has been lifelong.

#### NYSTAGMUS WAVEFORMS

Twelve waveforms of congenital nystagmus have been described consisting of combinations of jerk and pendular movements.<sup>3</sup> These can be simplified for the purposes of this discussion into pendular and uni-directional or bi-directional jerk waveforms (fig 1). The cause of congenital nystagmus is a defect in the slow eye movement system which is operating under unusual conditions of increased feedback gain.<sup>9</sup> The specific abnormality may be positive feedback in eye position and velocity signals from extra-ocular muscle proprioceptors.<sup>10</sup> As a consequence of this feedback instability, eye position is unstable and tends to "run away". This runaway constitutes the slow phase of the nystagmus which may show linear or exponential increasing or decreasing velocities. Saccades brake the slow phase and return the eyes to the fixation point constituting the fast phases of the nystagmus. Objective recording of eye movements is necessary to distinguish the

waveforms; clinically it is only possible to differentiate pendular and jerk waveforms.

When a unidirectional jerk nystagmus in the horizontal plane has an exponentially increasing slow phase velocity then it is almost certainly congenital; there has only been one report of an acquired nystagmus having this waveform<sup>11</sup> and in this case the nystagmus was in the vertical plane. The appearance of an exponentially increasing slow phase may appear artefactually on electro-oculographic recording of other nystagmus if there is a torsional component. This would be readily detected clinically by an examiner alerted to the possibility of artefact. A second waveform which is undoubtedly congenital is the bidirectional jerk nystagmus with exponentially increasing slow phase velocities in both directions. When these waveforms are clearly identified then they are highly characteristic of congenital nystagmus: however, many of the congenital waveforms show linear or exponentially decreasing slow phase velocities which may be mimicked by the waveforms of acquired nystagmus. Of particular note is that the pendular forms of congenital nystagmus can closely resemble the acquired variety.<sup>12</sup> Acquired pendular nystagmus can occur in conjunction with a jerk nystagmus, as in some cases of multiple sclerosis, resulting in a complex waveform which resembles combined pendular and jerk forms of congenital nys-

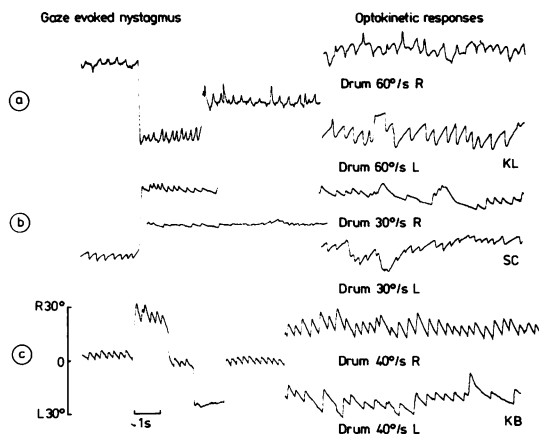


**Fig 1** Waveforms: Examples of nystagmus waveforms in centre, right and left gaze recorded from patients with congenital and acquired nystagmus showing that they may have similar characteristics, A, congenital nystagmus with exponentially increasing slow phases of unidirectional jerk nystagmus, B, congenital nystagmus with bidirectional jerk nystagmus in primary and right gaze and unidirectional jerk nystagmus in left gaze, C, congenital nystagmus with combined pendular and jerk waveforms, D, combined pendular and unidirectional jerk nystagmus in the primary position of gaze recorded from 24 year old male with proven multiple sclerosis, E, combined pendular and jerk nystagmus, flutter and square wave jerks recorded from a 34-year-old female with proven multiple sclerosis.

tagmus. Such acquired nystagmus waveforms are also illustrated in figure 1.

#### OPTOKINETIC RESPONSES

The optokinetic response is the slow phase following eye movement evoked by movement of large areas of the visual field. This is tested using a rotating drum which surrounds the patient and subtends almost the entire visual field. The patient is instructed to stare straight ahead at the stripes so that the response is not contaminated by gaze evoked (parietic) nystagmus or active following movements ("active optokinetic response"). A normal optokinetic response will generate slow phase eye movements at velocities up to about 60°/second<sup>13</sup> with an upper frequency limit of 1.5 Hz.<sup>14</sup> In congenital nystagmus optokinetic responses are



**Fig 2** Reversed Optokinetic Responses: A and B, nystagmus in centre, right and left gaze and optokinetic responses recorded from patients with congenital nystagmus. C, similar recordings taken from a 40 year old female with acquired PAN, dysarthria and gait ataxia. The nystagmus is illustrated in the right beating phase.

nearly always abnormal:<sup>15-19</sup> they may have deranged waveforms, abnormally high or low slow phase velocities, or be absent or reversed as illustrated in fig 2.

The reversal of the slow phase direction of the optokinetic response may be uni or bi-directional. It may occur with all velocities of stimulus or be provoked at certain velocities. It has been considered that a reversed optokinetic response, that is where the slow phase of the nystagmus is in the opposite direction from the direction of movement of the visual field, is pathognomic of congenital nystagmus.<sup>20,21</sup> However this is not the case; an apparently reversed optokinetic response may occur in acquired oculomotor disease when there is a second or third degree spontaneous nystagmus and no optokinetic reflex. Under these conditions the optokinetic responses will apparently be present to stimuli in the direction of the slow phase of the nystagmus and reversed in the opposing direction.

Periodic alternating nystagmus, which may be of a congenital or acquired variety, is a specific case of a third degree nystagmus which changes direction over a time period of several tens of seconds (reviewed by Rudge, 1983<sup>22</sup>). The nystagmus continues through pursuit and optokinetic stimuli and true optokinetic responses are minimal or absent. The result is that during the right beating phase of the nystagmus optokinetic responses appear to be in the normal direction for leftwards stimuli and reversed to rightwards stimuli. When the spontaneous nystagmus reverses to beating leftwards, the

inverse pattern of "optokinetic" responses appears (fig 2).

In acquired oculomotor disorders reversal of the optokinetic response only occurs in one direction at any one time which is determined by the direction of the spontaneous nystagmus. In congenital nystagmus bidirectionally reversed optokinetic responses may sometimes occur although the reversal is more often unidirectional and occurs only at certain stimulus velocities. The presence of bidirectionally reversed optokinetic responses, when an alternating nystagmus has been excluded, is pathognomonic of congenital nystagmus.

#### PURSUIT RESPONSES

The pursuit response is a slow phase eye movement evoked by a small target moving across the visual field. Pursuit is usually tested using sinusoidal and triangular waveforms of target motion which are varied in velocity and frequency. Normal pursuit movements, within certain velocity and frequency limits ( $<1$  Hz,  $<30$ – $40^\circ/\text{s}$ <sup>23,24</sup>) closely follow the trajectory of the target with minimal saccadic interruptions.

The majority of patients with congenital nystagmus do not have an organised slow phase of smooth pursuit; the envelope of eye movement accurately matches the target trajectory but the congenital nystagmus waveform is superimposed which gives the appearance of a grossly impaired response.<sup>21</sup> In subjects whose congenital nystagmus shows a clearly defined null point, that is those with jerk waveforms on lateral gaze, pursuit is impaired in the following way, as illustrated in fig 3: attempts to pursue influence the position of the null point of the nystagmus so that the null point shifts to the left when the eyes are moving towards the right and vice versa. In consequence, when the eyes are moving towards centre from lateral gaze the superimposed nystagmus has a slow phase in the opposite direction to the target motion, which gives the appearance of "reversed pursuit". Although reversal of pursuit, specifically during target motion towards centre, is strongly indicative of congenital nystagmus, a similar reversal can occur when there is acquired third degree, centripetal or periodic alternating nystagmus.

Emphasis here is laid on the significance of reversal of pursuit occurring when the eyes are tracking from an eccentric position towards centre gaze. Apparent reversal of pursuit for movements away from centre is a common finding in acquired oculomotor disorders which occurs when there is a combination of absent pursuit and gaze paretic nystagmus. In all forms of pendular nystagmus, congen-

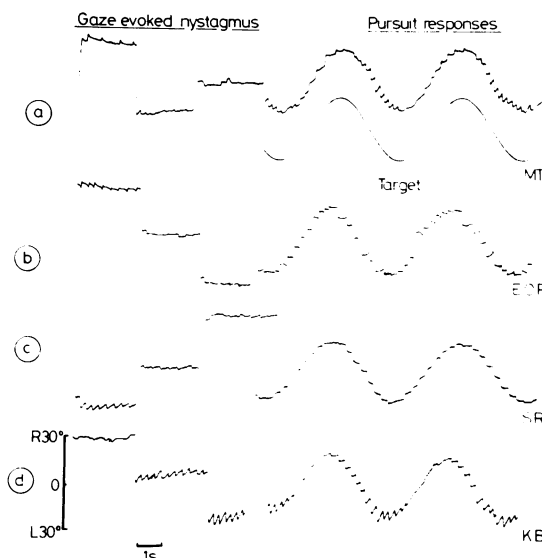


Fig 3 Pursuit Responses: Nystagmus in centre, right and left gaze and pursuit responses to sinusoidal target motion at a frequency of 0.2 Hz, peak amplitude of  $20^\circ$  (red laser target at 2 m distance). A and B, congenital nystagmus. C, Third degree spontaneous nystagmus in a 30-year-old female with a 16 year history of idiopathic spino-cerebellar degeneration. D, acquired periodic alternating nystagmus (same patient as fig 2).

ital or acquired, the nystagmus waveform is superimposed on the pursuit movement and can give the appearance of reversal.

**Mechanism of reversed pursuit and optokinetic responses:** Hood and Leech<sup>25</sup> proposed that in congenital nystagmus there is an algebraic addition of the nystagmus waveform and the optokinetic response which produces a composite waveform giving the impression of a fast phase in the direction of the stimulus and an inverted slow phase. The alternative theory, which has had widespread acceptance,<sup>26</sup> springs from the observation by Halmagyi *et al*<sup>20</sup> and Dell'Osso<sup>21</sup> that the waveforms of inverted optokinetic responses are similar to the spontaneous gaze evoked nystagmus. This suggests that the optokinetic stimulus shifts the null point of the congenital nystagmus in the opposite direction to the stimulus motion. The nystagmus evoked by gaze in the direction of stimulus motion also shifts so that it extends across the range of movement. This nystagmus persists during the eye movement and has a slow phase in the opposite direction to the stimulus motion which gives the appearance of an "inverted" response. The inversion of pursuit responses is explained similarly.

Both of these theories are inadequate to explain the wide variety of responses encountered when large numbers of subjects with congenital nystagmus are examined in detail.<sup>19</sup> It is quite clear that not all waveforms of inverted optokinetic responses can be construed either as combinations of normal optokinetic and congenital nystagmus or as manifestations of gaze evoked nystagmus provoked by shifts of the null point. Trace A of fig 2 shows examples of

exceptions. The response to drum rotation to the right closely resembles the nystagmus seen in the region of the null and not the nystagmus of rightwards gaze. In addition responses to leftwards stimuli have an exponentially decaying waveform and not the exponentially increasing waveform of the leftwards gaze evoked nystagmus. In contrast the optokinetic responses of fig 2 B resemble the gaze evoked nystagmus as if the null had shifted. Our own experience is that shifting of the null point during pursuit and optokinetic stimuli is a variable phenomena which can fluctuate from moment to moment in response to stimulus direction and velocity. At present there is no explanation of these phenomena.

#### ABNORMAL HEAD MOVEMENTS AND POSTURES ASSOCIATED WITH NYSTAGMUS

It is currently accepted that two forms of head shaking may be associated with congenital nystagmus.<sup>27</sup> Firstly, there is involuntary head tremor which does not improve visual acuity and secondly, there are compensatory movements of the head which are opposite in direction to the beating of the nystagmus. Tremor and compensatory shaking can be differentiated by asking the patient to read a Snellen chart with head free and head held stationary—if vision improves significantly when the head is free to move then the shaking is compensatory.

We have recently observed a third type of head movement in a patient referred by Mr Peter Fells of Moorfields Eye Hospital. The patient, with definite congenital nystagmus, shook her head rhythmically to improve her vision. Eye and head movement recordings revealed that during head shaking the nystagmus was suppressed and replaced by normal compensatory “dolls head” eye movements. Head shaking which suppresses nystagmus is also observed in the rare entity of spasmus nutans,<sup>6</sup> which is a high frequency nystagmus that develops during infancy and is reported to remit during childhood. We have also observed the suppression of acquired pendular nystagmus by head shaking although the patients do not seem to adopt this manoeuvre to improve visual acuity. The required condition for the suppression of nystagmus appears to be vestibular stimulation, for the suppression also occurred during passive movements.

Abnormal head postures adopted to improve visual acuity occur frequently with congenital nystagmus but may also result from acquired nystagmus. In each case there is a position or positions of the eyes in the orbit in which nystagmus has the least amplitude or the lowest frequency, and in which vision is best. Accordingly, the head is turned to an eccentric position which allows the eyes to fixate from the orbital position which affords best acuity. In periodic alternating nystagmus the head posture varies as the null point of the nystagmus shifts with the

reversal of the nystagmus.

Shaking and posturing of the head to improve visual acuity are extremely rare in acquired oculomotor disorders. Such manoeuvres, particularly if long-standing, are most likely to indicate congenital nystagmus. Involuntary movements and abnormal postures of the head unrelated to visual acuity have no differential diagnostic value and occur commonly in neurological disorders.<sup>6,28</sup>

#### VESTIBULAR RESPONSES TO ROTATIONAL TESTING

Abnormalities of responses to rotational testing occur in about 50% of asymptomatic patients with congenital nystagmus.<sup>29,30</sup> Short or apparently absent responses to rotational steps may occur, with persistence of the spontaneous nystagmus which swamps or masks any induced nystagmus. Wandering eye movements and extreme gaze deviations in the dark as a consequence of lack of position or velocity sensitivity in these subjects may also mask any underlying vestibular response and do not per se indicate vestibular derangement. In contrast, testing with sinusoidal stimuli shows appropriate phase modulation of the spontaneous nystagmus suggesting that underlying vestibular function is essentially normal. In asymptomatic patients, highly abnormal responses that defy conventional neuro-otological interpretation strongly suggest the presence of congenital nystagmus.

#### FLUCTUATIONS IN AMPLITUDE OF NYSTAGMUS WITH FIXATION/DARKNESS/EYE CLOSURE

Congenital nystagmus changes its characteristics in the presence or absence of vision. The nystagmus has the most consistent waveform and amplitude with fixation. In darkness the amplitude may increase or the nystagmus may cease. The nystagmus almost always disappears with eye closure. In contrast most forms of acquired nystagmus persist in darkness and with eye closure and may increase in amplitude and slow phase velocity. In some forms of acquired nystagmus the brainstem mechanisms which generate the fast position corrective phase are also defective. Accordingly, in darkness or with eye closure, fast phases may not be generated and the eyes drift with the slow phase.<sup>31</sup> Thus, the rare combination of maintenance of a steady gaze position in the dark together with the cessation of nystagmus is strongly indicative of congenital nystagmus.

#### SYMPTOMATOLOGY

The commonest symptom of congenital nystagmus is reduced visual acuity which can range from mild to severe. The patients describe their visual impair-

ment in terms of blurring and defocussing. Clearly, there is least impairment at the null point of the nystagmus which, if eccentric, leads to a marked head turn which may itself be symptomatic. When the patient looks with his eyes away from the null point (nystagmus being faster and/or larger amplitude) then blurring increases with a loss of acuity which can be detected on a Snellen chart. Nystagmus of high frequency is particularly detrimental to visual acuity and we have encountered one patient with beats in excess of 7/second who was effectively blind.

When viewing a stationary target under normal illumination oscillopsia is generally not a symptom of congenital nystagmus regardless of eye position. We have, on rare occasions, encountered a patient with congenital nystagmus who does experience oscillopsia under these conditions. Their nystagmus has been intermittent or alternating with long quiescent periods. Presumably these individuals have not been forced to adapt to their involuntary eye movements unlike those with continuous nystagmus. Oscillopsia may occur under the unusual conditions of viewing solitary points of light in darkness and there may be excessive awareness of the flicker of fluorescent lights.

More frequently, patients experience oscillopsia when attempting to track moving targets such as reading the number of a moving omnibus. Under these circumstances it would seem that the deficit in the pursuit system becomes symptomatic. All patients with congenital nystagmus have great difficulty in reading within a moving vehicle which requires suppression of the vestibulo-ocular reflex by a mechanism closely related to pursuit.<sup>7</sup> They experience increased blurring of vision and have symptoms of motion sickness. Some report blurring of a moving visual scene, for example when they look out of a train window; this may result from their abnormal optokinetic responses.

In general people with congenital nystagmus have few complaints apart from reduced acuity. The problems for the clinician lies in the interpretation of their symptoms which are not in commonplace experience.

## Conclusions

The clinician should be aware of the possibility of congenital nystagmus when a patient presents with a marked nystagmus which seems inappropriate to other neurological symptoms and signs. Diagnosis can be particularly difficult when there is a less florid congenital nystagmus which is of low amplitude in lateral gaze and has a large null region which thus resembles the usual acquired gaze evoked nystag-

mus. In the absence of a definite lifelong history of nystagmus a detailed oculomotor examination should be performed with special attention to the slow eye movement systems. In problem patients objective recordings of eye movements may be needed which can elucidate characteristic nystagmus waveforms, pursuit and optokinetic responses.

Nicholas Page was supported financially by the Smith Charity.

## References

- 1 Walshe FB, Hoyt WH. *Clinical Neuro-ophthalmology*. Vol 1. Baltimore, Williams and Wilkins. 1969.
- 2 Cogan DG. *Neurology of the Ocular Muscles*. Springfield, Ill. CC Thomas. 1956.
- 3 Dell'Osso LF, Daroff RB. Congenital nystagmus waveforms and foveation strategy. *Documenta Ophthalmologica* 1975;39:155-82.
- 4 Daroff RB, Troost BT, Dell'Osso LF. Nystagmus and related ocular oscillations. In: Glaser JS ed. *Neuro-Ophthalmology*. Hagerstown, Maryland. Harper and Row, 1978:219-43.
- 5 Baloh RW, Honrubia V. *Clinical Neurophysiology of the Vestibular System*. Philadelphia, Davies FA. 1979.
- 6 Gresty MA, Halmagyi GM. Abnormal head movements. *J Neurol Neurosurg Psychiatry* 1979;42:705-14.
- 7 Halmagyi GM, Gresty MA. Clinical signs of visual vestibular interaction. *J Neurol Neurosurg Psychiatry* 1979;42:934-9.
- 8 Leigh RJ, Zee DS. *The Neurology of Eye Movements*. Philadelphia. Davis FA. 1982.
- 9 Dell'Osso LF, Gauthier G, Liberman G, Stark L. Eye movement recordings as a diagnostic tool in a case of congenital nystagmus. *Am J Optom and Arch Am Acad Ophthalmol* 1972;49:3-13.
- 10 Zee DS, Optican LM. *J Bio Eng* 1984 In press.
- 11 Zee DS, Leigh J, Mathieu-Millaire F. Cerebellar control of ocular gaze stability. *Ann Neurol* 1980;7:37-40.
- 12 Gresty MA, Ell JJ, Findley LJ. Acquired pendular nystagmus: its characteristics, localising value and pathophysiology. *J Neurol Neurosurg Psychiatry* 1982;45:431-9.
- 13 Honrubia V, Downey WL, Mitchell DP, Ward PH. Experimental studies on optokinetic nystagmus. II. Normal Humans. *Acta Oto-laryngol* 1968;65:441-8.
- 14 Trinker D, Sieber J, Bartual J. Schwingungsanalyse der vestibulärer, optokinetisch und durch elektrische Reizungsausgelosten Augenbewegungen beim Menschen. 1 Mitteilung: Steitige Augenbewegungen: Frequenzgänge und Ootskurven. *Kybernetik* 1961;1:21-8.
- 15 Barany R, Zur Klinik und Theorie des Eisenbahn nystagmus. *Acta Oto-laryngol* 1921;3:260-5.
- 16 Brunner H. Zur Klinischen der Inversion des optokinetischen Nystagmus. *Albrecht v Graeves Arch Ophthalmol* 1922;129:30-56.
- 17 Dichgans J, Jung R. Oculomotor abnormalities due to cerebellar lesions. In: Lennerstrand G, Bach-Y-Rita P. *Basic Mechanisms of Ocular Motility and Their*

- Clinical Implications*. Pergamon, Oxford. 1975:281-98.
- <sup>18</sup> Abadi RV, Dickinson CM, Lomas MS. Inverted and asymmetrical optokinetic nystagmus. In: Lennerstrand G, Zee DS, Keller E, eds. *Functional Basis of Ocular Motility Disorders*. New York: Pergamon. 1982:143-6.
- <sup>19</sup> Kommerell G, Mehdorn E. Is an optokinetic defect the cause of congenital nystagmus? In: Lennerstrand G, Zee DS, Keller E, eds. *Functional Basis of Ocular Motility Disorders*. New York: Pergamon. 1982:159-67.
- <sup>20</sup> Halmagyi GM, Gresty MA, Leech J. Reversed optokinetic nystagmus (OKN): Mechanism and clinical significance. *Ann Neurol* 1980;**7**:429-35.
- <sup>21</sup> Dell'Osso LF. Congenital nystagmus: basic aspects. In: Lennerstrand G, Zee DS, Keller, eds. *Functional Basis of Ocular Motility Disorders*. New York: Pergamon. 1982:129-38.
- <sup>22</sup> Rudge P. *Clinical Neuro-Otology*. Edinburgh, Churchill Livingstone. 1983.
- <sup>23</sup> Stark LG, Vossius G, Young LR. Predictive control of eye tracking movements. *IRE Trans. Human Factors in Electronics* 1962:HLE3:52-7.
- <sup>24</sup> Young LR. Pursuit eye tracking movements. In: Bach-Y-Rita P, Collins CC, eds. *The Control of Eye Movements*. New York: Academic Press. 1971:429-44.
- <sup>25</sup> Hood JD, Leech J. The significance of peripheral vision in the perception of movement. *Acta Otolaryngol* 1974;**77**:72-9.
- <sup>26</sup> Kommerell G. Congenital nystagmus: discussion. In: Lennerstrand G, Zee DS, Keller E, eds. *Functional Basis of Ocular Motility Disorders*. New York: Pergamon. 1982:169-70.
- <sup>27</sup> Gresty MA, Ell JJ. Normal modes of head and eye coordination and the symptomatology of their disorder. In: Lennerstrand G, Zee DS, Keller E, eds. *Functional Basis of Ocular Motility Disorders*. New York: Pergamon. 1982:391-405.
- <sup>28</sup> Brain WR. On the rotated or "Cerebellar" posture of the head. *Brain* 1926;**49**:61-76.
- <sup>29</sup> Forssman B. A study of congenital nystagmus. *Acta Oto-laryngol* 1964;**57**:427-49.
- <sup>30</sup> Yee RD, Baloh RW, Honrubia V, Kim YS. A study of congenital nystagmus: vestibular nystagmus. *J Oto-laryngol* 1981;**10**:89-98.
- <sup>31</sup> Leech J, Gresty MA, Hess K, Rudge P. Gaze failure, drifting eye movements and centripetal nystagmus in cerebellar disease. *Br J Ophthalmol* 1977;**61**:774-81.