

# A FURTHER ANATOMICAL CHECK ON THE ACCURACY OF INTRA-ARTICULAR HIP INJECTIONS IN RELATION TO THE THERAPY OF COXARTHROSIS

BY

MARJORIE M. DOBSON

*London*

In an attempt to test the accuracy of the intra-articular injection treatment of coxarthrosis, as used by Waugh (1945), Crowe (1944), and many other investigators; hip-joints of 33 cadavers were injected (Dobson, 1948) with dye solution which jellified on cooling. The technique of injection was similar to that applied in living patients undergoing treatment for osteo-arthritis of the hip. In 1947 at a Heberden Society meeting, D. P. Nicholson remarked on the difficulty of the procedure of injection into the arthritic hip-joint. He reported that in a series of 23 hip-joints radiographed after the intra-articular injection of diodone (an opaque dye) only one x-ray film confirmed the appearance of the dye in the joint injected (Nicholson, 1948).

It seemed that it might be of interest to record the results of a second series of forty hip-joints injected with the dye solution in the cadaver. Not only would an independent control be made on the original experiment, but a comparison could be made between the relative efficacy of the anterior and the lateral approach to the hip-joint.

## Material

In my second series of experiments on intra-articular injections in the cadaver, nearly all the bodies used were of good physique and weight, and were injected within a day or two of reception in the Anatomy Department. Thus a similar varied resilience of each tissue-substance penetrated by the needle was experienced, as in the living osteo-arthritic patient.

## Results

The results were recorded as positive when the dye was very plainly seen, inside the acetabular cavity, or on the head or intra-capsular part of the neck of the femur, or on the inner surface of the capsule lining. Only one example of a jell precipitate was seen in the outer capsular layers, and in the iliopsoas tendon in this series.

The results classed as negative imply an entire absence of any dye coloration inside or outside the capsule of the joint, or in the periarticular tissues. It may be presumed that the dye decolorizes or decomposes if in the softer tissues outside

the joint itself, or is intra-capsular rather than intra-articular. One grossly deformed osteo-arthritic hip was found on dissection. No dye was seen in this case, whether because of difficulty of penetration of the joint or not may be surmised.

At the end of 18 months the percentage of cases was found to be almost identical with that obtained in the previous series of hip-joints. An unfortunate over-concentration of carbolic acid used in the "curing" of seven bodies, prevented a consolidation of the dye as "jelly" in fourteen hip-joints injected, but the dye coloration was recognizable as such. The anterior approach to the joint resulted in a slightly higher proportion of successful results than the lateral approach; although both methods could give satisfactory results (see Table).

TABLE  
COMPARATIVE RESULTS WITH LATERAL AND  
ANTERIOR APPROACH

Results	Approach	
	Lateral	Anterior
Positive .. ..	10	13
Negative .. ..	9	8
Per cent. Positive ..	52 (6)	61 (9)
Total Cases .. ..	19	21

Figs 1, 2, and 4, showing the acetabular cavity of three specimens, illustrate good positive results. The bright carmine jelly deposit (indicated by arrows) is seen right inside the cavity. Fig. 3 (rather distorted by foreshortening) demonstrates a similar deposition of jelly on the femoral head and inside the reflexion of capsule from the neck.

Thus it is reasonable to assume that 20 ml. fluid, injected by a similar technique into the hip-joint of the living patient, would bathe the articular components of the joint, and "swill out" the synovial membrane, fringes, and lining of the joint capsule.

#### Summary

In forty cases of hip-injection in the cadaver, it was shown, by means of a special dye solution, that 67 per cent. were completely successful. In the former series of 33 cases, 61 per cent. had been successful.

The anterior method of approach to the hip joint may give better results than the lateral method, when intra-articular injections are attempted in osteo-arthritic patients receiving acid-injection treatment for coxarthrititis.

Photographs of typical successful results emphasize the probable success in entering the hip-joint cavity in more than 60 per cent. of attempted intra-articular injections.

My thanks are due to Prof. Lucas Keene of the Anatomy Department of the Royal Free Hospital, London, for permission and encouragement to continue this work, and to Mr. Champion, the curator, for his valuable help in the preparation of the specimens.

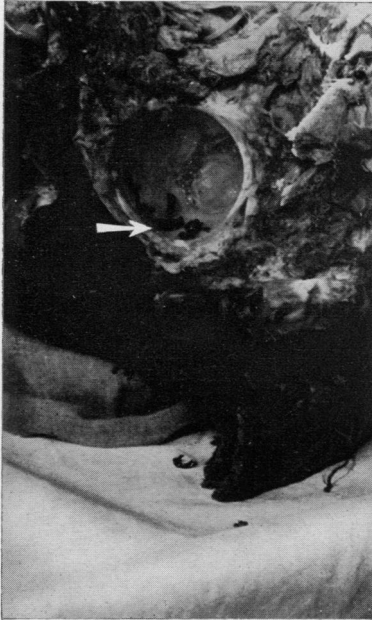


FIG. 1.—Deposit in acetabular cavity of specimen A.

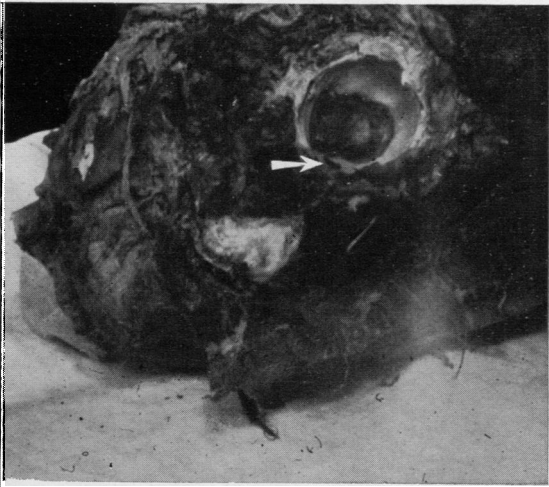


FIG. 2.—Deposit in acetabular cavity of specimen B.

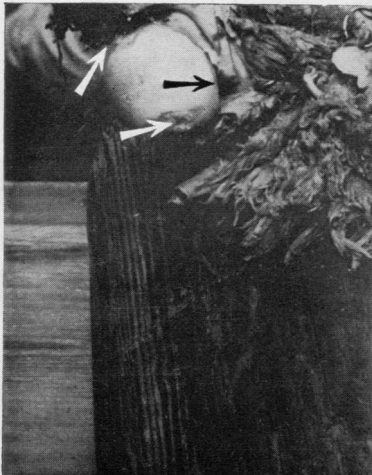


FIG. 3.—Deposit on femoral head of specimen C.

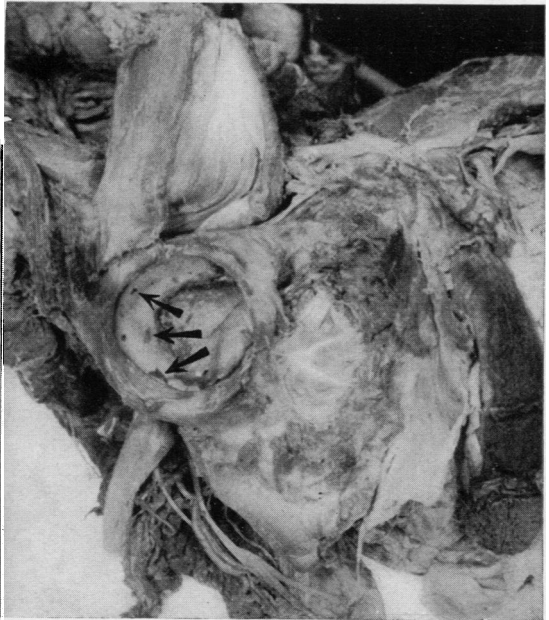

FIG. 4.—Deposit in acetabular cavity of specimen D.

## REFERENCES

- Crowe, H. W. (1944). *Lancet*, 1, 563.  
Dobson, M. M. (1948). *Annals of the Rheumatic Diseases*, 7, 172.  
Nicholson, D. P. (1948). *Ibid.*, 7, 28.  
Waugh, W. G. (1945). *Brit. med. J.*, 1, 873.

**Nouvelles Vérifications Anatomiques de la Précision des Injections dans  
l'Articulation Coxo-fémorale, à propos du Traitement de l'Arthrite de la Hanche**

## RÉSUMÉ

L'injection d'un colorant spécial dans l'articulation coxo-fémorale des cadavres réussit complètement dans 67 pour cent des cas; il y eut 40 tentatives. Dans la série précédente de 33 tentatives, il y eut 61 pour cent de réussites.

La méthode d'accès antérieur à l'articulation de la hanche peut donner de meilleurs résultats que celle d'accès latéral dans le traitement de l'arthrite coxo-fémorale par des injections intra-articulaires d'acide.

Les photographies, montrant des résultats favorables typiques, mettent en relief les chances d'entrée dans la cavité articulaire coxo-fémorale dans plus de 60 pour cent des tentatives d'injection.

**Nevas Comprobaciones Anatomicas de la Precision de las Inyecciones en la  
Articulacion Coxo-femoral en Relacion con el Tratamiento de la Artritis de la Cadera**

## RESUMEN

Se notó un éxito completo en 67 por ciento de los 40 casos de inyección de un tinte especial en la articulación coxo-femoral de cadáveres. En la serie anterior de 33 casos el porcentaje de inyecciones logradas fue 61.

Al tratar la artritis coxo-femoral por inyecciones intra-articulares de ácido el método de acceso anterior a la articulación puede dar mejores resultados que el acceso lateral.

Las reproducciones fotográficas, mostrando resultados favorables típicos, ponen en relieve la probabilidad de penetración de la cavidad articular coxo-femoral en más de 60 por ciento de tentativas de inyección.