

ARTHRITIC MANIFESTATIONS IN REGIONAL ENTERITIS*

BY

BARBARA M. ANSELL AND R. A. D. WIGLEY

M.R.C. Rheumatism Research Unit, Canadian Red Cross Memorial Hospital, Taplow

Arthritis occurred in 4.5 per cent. of 600 patients with regional enteritis reviewed by Van Patter, Bargaen, Dockerty, Feldman, Mayo, and Waugh (1954). Ford and Vallis (1959) described four cases of arthritis in regional enteritis and suggested that it was similar in nature to the arthritis associated with ulcerative colitis (Bywaters and Ansell, 1958). The present study was undertaken to investigate further the incidence and pattern of arthritis in patients suffering from chronic regional enteritis.

Plan of Study

To obtain suitable material, the case records of all patients in whom a diagnosis of regional enteritis had been suggested during the 5-year period from January, 1957, to December, 1961, at the Hammersmith, Central Middlesex, West Middlesex, and Canadian Red Cross Memorial Hospitals were reviewed with the clinician in charge of the case. The diagnosis of chronic regional enteritis was made by him on the basis of history and clinical findings supported by either radiological or histological examination, with both in about half the cases. No patient in whom there was any doubt as to the diagnosis was included, nor were those with acute ileitis or primary involvement of the colon. As a number of suitable patients had been referred for consultation from other hospitals, those included in the survey were those currently attending as out-patients, re-admitted during the survey period, or resident within a reasonable distance of the base hospital.

In-patients and those currently attending the out-patients department were asked to co-operate in the survey, while those no longer attending were written to with a request for their help. Patients were seen by special appointment, when they were questioned about joint stiffness, pain or swelling, eye or skin troubles, and a family history of either arthritis or gastro-intestinal disorders. The musculo-skeletal system was carefully examined and, when possible, a blood sample was obtained. If there had been any complaint of joint symptoms, radiographs of the appropriate joints were

taken, and in all cases in which the sacro-iliac joints could not be readily seen on a recent barium study, a further radiograph of these joints was taken. The majority of patients were seen on one occasion only, but it has been possible to follow more closely the pattern of the joint manifestations of those seen at Hammersmith Hospital.

Results

A total of 114 patients satisfied the diagnostic and geographical criteria. Of these, thirteen had died before this survey: ten from surgical complications associated with this disorder; one from inanition; one from amyloidosis; and one from a perforated duodenal ulcer while on steroid therapy. In only one of these had any rheumatic complaint been recorded. This was an elderly lady who had attended the rheumatology clinic 2 years before her death, when a diagnosis of osteo-arthritis of the knees had been made. Of the remaining 101, 91 co-operated fully in the study, four were questioned but refused examination on the grounds that they had no rheumatic complaints, two refused to co-operate in any way, and four could not be traced.

There were 54 females and 37 males in the survey; at this time, the majority of the females were between the ages of 25 and 45 years, and the age peak in males was between 25 and 35 years (Table I).

TABLE I
AGE AND SEX DISTRIBUTION OF 91 PATIENTS REVIEWED

Age (yrs)	Sex	
	Male	Female
0-14	2	1
15-24	3	9
25-34	15	16
35-44	6	14
45-54	7	8
55-64	2	4
65+	2	2
Total	37	54

* Based on a paper given to the Heberden Society on November 30, 1962.

The mean duration of bowel symptoms was 7.9 years (range 1 to 33); ileal involvement, usually associated with caecal involvement, was present in ninety, and this was associated with colonic lesions in 26 and jejunal lesions in eight: in one patient the lesion was confined to the jejunum. A family history of regional enteritis was given by three patients, involving a cousin in two and a sibling in one, while rheumatoid arthritis was said to be present in two mothers and one father. In addition, one mother was suffering from Sjögren's syndrome and one father had a history of a "back disorder" suggestive of ankylosing spondylitis.

Incidence of Arthritis.—33 of the 91 patients had had symptoms related to the joints at some time, but not all were thought to be related to the gastrointestinal disorder.

At the time of the survey, six patients (four female and two male) had polyarthritis; two of these patients gave a history of at least one previous attack of polyarthritis.

A history of acute arthritis was obtained in a further twelve patients, five male and seven female. Eight of these had a history of a self-limiting attack of polyarthritis which in four had occurred on two or more occasions. In two further patients the arthritis had developed in association with erythema nodosum and had involved the large joints. The remaining two patients gave a history of a single joint being involved for a period of months.

Psoriasis was present at the time of examination in one patient with recurrent polyarthritis and one who had had a monarticular arthritis.

Five patients, one male and four female, were diagnosed as suffering from ankylosing spondylitis which in two was associated with peripheral joint involvement, while a further patient with a past history of back injury, who now had a peripheral arthritis and back symptoms, was diagnosed as a possible case of ankylosing spondylitis.

In addition, one male and two females gave a history of acute attacks of arthralgia which they felt had coincided with exacerbations of bowel symptoms.

The remaining eight consisted of three patients with a history compatible with rheumatic fever at 8, 16, and 17 years of age respectively, all many years before the onset of enteric symptoms, one with a history suggestive of Reiter's syndrome some 30 years before the bowel symptoms, which had led to residual deformity of the feet, and four with signs of degenerative joint disease in the knees or ankles, the latter on a traumatic basis in one (Table II).

TABLE II
RHEUMATIC MANIFESTATIONS IN 91 CASES OF CHRONIC REGIONAL ENTERITIS

Rheumatic Symptoms	Sex	
	Male	Female
Polyarthritis	2	4
Ankylosing spondylitis with peripheral arthritis	1	1
Ankylosing spondylitis	3	0
Possible ankylosing spondylitis	1	0
Past polyarthritis	3*	5
Erythema nodosum	0	2
Mono-arthritis	2*	0
Arthralgia	1	2
Miscellaneous	3	5

* 1 patient in each of these groups also suffered from psoriasis.

Pattern of Polyarthritis.—The six patients with polyarthritis at the time of the survey all showed involvement of the proximal interphalangeal joints of the finger and knee joints, while other joints involved included the wrists and ankles and, in one case, the hip. A similar distribution of joint involvement was described in the eight patients with past polyarthritis, the knee joint being that most commonly involved. In these eight patients, there were minimal clinical residua and no erosive changes were seen radiologically in previously affected joints. In two patients a single joint was involved, a shoulder in one and a hip in the other.

The relationship of the arthritis to bowel symptoms varied considerably. Thus, in Case 1 (see Appendix), an attack of acute polyarthritis involving all the proximal interphalangeal joints and persisting for 3 to 4 months had occurred 6 years before the onset of bowel symptoms and further attacks developed shortly after the diagnosis of regional enteritis was made and again with a relapse in symptoms, remitting on the last two occasions after surgery. Conversely, in Case 2 (see Appendix), the patient noticed stiffness of the fingers in the mornings 13 years after the onset of bowel symptoms, and this was relieved by steroid given for the regional enteritis; frank arthritis developed 5 years later and was particularly marked during steroid withdrawal.

Among the fourteen patients with present or past polyarthritis there was only one in whom the first attack of arthritis had antedated the bowel symptoms. In two it had occurred with the onset and in the remainder at varying times from 1 to 17 years and not necessarily in association with a relapse or recurrence of the underlying disease. In the majority of the patients, the attacks of arthritis were short-lived, lasting from 3 to 8 weeks.

Five of the 91 patients were suffering from psoriasis and arthritis had occurred in two of them.

Ankylosing Spondylitis.—Among the five patients diagnosed clinically as suffering from ankylosing spondylitis, back symptoms had begun 16 years before bowel symptoms in one and 5 years before in another. The remaining three had first developed back symptoms 1, 4, and 8 years respectively after the intestinal disorder and this included two with peripheral joint involvement (*e.g.* Case 3).

The patient diagnosed as a case of possible ankylosing spondylitis was difficult to evaluate as he gave a history of back injury leading to crush-fractured vertebrae 17 years previously and some 5 years before the onset of bowel symptoms. After this injury he had been subject to back pain, but it had been persistent only for the last 5 years, while for 3 years he had had recurrent swelling and pain in a number of peripheral joints. At the time of examination he had slight residua in one wrist and one ankle; the movement of the spine was limited, but it was felt that this could have resulted from the old injury.

Altogether, 32 patients had suffered from back-ache but the majority had no abnormal physical signs. It was considered that one patient might have had a prolapsed intervertebral disk, and nine were thought to have mild lumbar disk degeneration, but in sixteen no cause could be suggested.

Serology.—The Waaler-Rose differential agglutination titre (Rose, Ragan, Pearce, and Lipman, 1948) was negative in all 89 of the sera available as was the latex test (Singer and Plotz, 1956) and the antinuclear factor (Holborow, Weir, and Johnson, 1957).

Sacro-iliac Changes.—For the purposes of reading the radiographs of the sacro-iliac joints, the *x* rays were matched for sex and age with controls obtained from a population survey or with pelvic films taken previously in connexion with another study. The films were mixed and then read for erosions, sclerosis, and narrowing, each aspect being graded 0 to 3 as described by Dixon and Lience (1961).

In each of these categories the incidence of sacro-iliac abnormality both doubtful (Grade 1) and definite (Grades 2 and 3) was greater in the males than in their controls. The females also showed a slightly greater incidence, but this was less marked than in the males. For sacro-iliac joints to be classed as abnormal, a reading of Grade 2 or 3 in at least two categories was required. Altogether, eighteen patients (twelve male and six

female) showed significant sacro-iliac change compared to two controls; this was bilateral in nine of the male and five of the female patients, but not in either of the controls (Table III).

TABLE III
RADIOLOGICAL SACRO-ILIITIS IN REGIONAL
ENTERITIS AND CONTROLS

Series	Total No. of Cases	Bilateral		Unilateral	
		Male	Female	Male	Female
Regional Enteritis ..	18	9	5	3	1
Controls	2	0	0	1	1

When radiological data was correlated with clinical data, it was found that the patient with Reiter's syndrome had abnormal sacro-iliac joints, as had one of the male patients with psoriasis and arthritis. After exclusion of these two, ten males had significant sacro-iliac changes, presumably related to their regional enteritis. This included the five in whom a clinical diagnosis of ankylosing spondylitis had been made. Two other males with bilateral sacro-iliitis had each complained of incapacitating back-ache on occasions, but no abnormal physical signs had been found, while a further male with predominantly unilateral sacro-iliitis had a history of two attacks of polyarthritis (Fig. 1, opposite).

Among the females, the patient diagnosed clinically as a case of ankylosing spondylitis had abnormal sacro-iliac joints, as did two who had had attacks of polyarthritis considered to be related to their regional enteritis; a fourth patient had psoriasis but no arthritis.

Other Manifestations.—The only patients with erythema nodosum in this series were the two already recorded, in both of whom the erythema had been associated with polyarthritis. No uveitis or episcleritis was seen or recorded in the case histories, although four patients, all male, gave a history of one or more attacks of conjunctivitis.

Relationship to Colonic Involvement.—There appeared to be no correlation between sacro-iliitis or peripheral arthritis and colonic involvement. Among the patients with peripheral arthritis, 28 per cent. were thought to have colonic involvement as were 22 per cent. of those with radiologically abnormal sacro-iliac joints, but the colon was involved in 30 per cent. of the patients with neither rheumatic history nor radiological abnormality (Table IV, opposite).

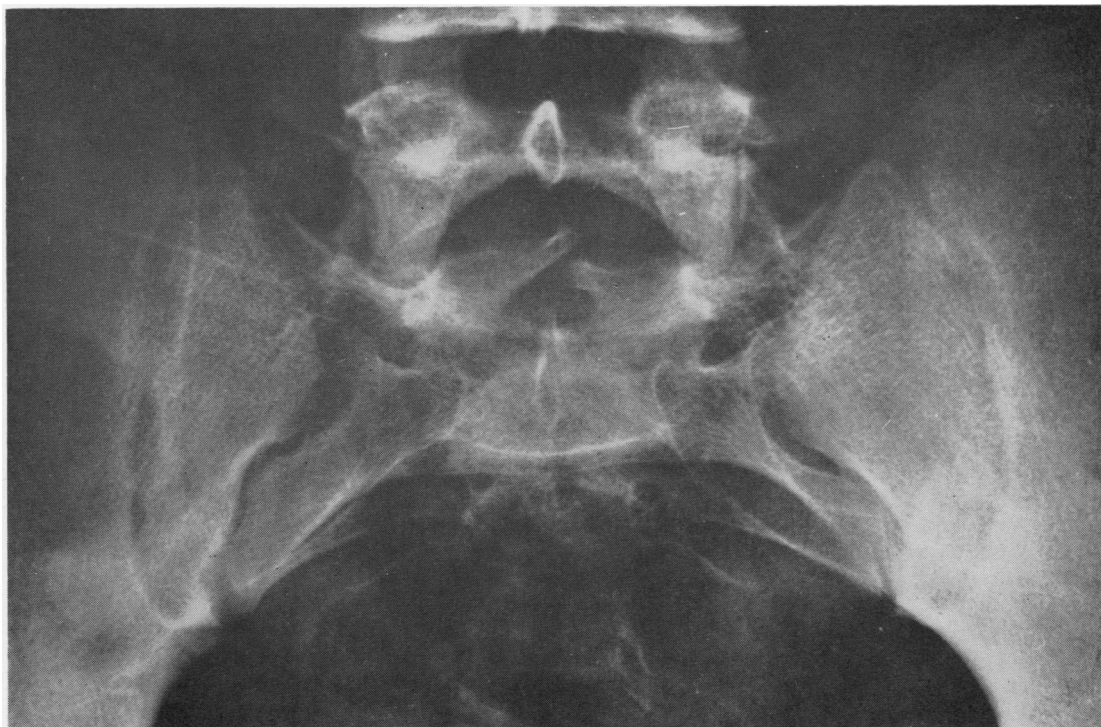

Fig. 1.—Sacro-iliitis in a patient with a past history of two attacks of polyarthritis.

TABLE IV
ASSOCIATION OF COLONIC INVOLVEMENT WITH
RHEUMATIC MANIFESTATIONS

Rheumatic Manifestations	Number of Cases	Colonic Involvement	
		No.	Per cent.
Sacro-iliitis	18	4	22
Arthritis	21	6	28
Non-specific	60	18	30

Discussion

Van Patter and others (1954) found arthritis in 4.4 per cent. of their cases, Crohn and Yarnis (1958) reported a large joint arthritis in 2.3 per cent. of 674 patients, and Daffner and Brown (1958) found six patients with rheumatoid arthritis, two with rheumatoid spondylitis, and two with erythema nodosum among 100 patients with regional enteritis. Our incidence of actual joint changes at the time of the survey is similar to that found by the last authors, but the patients' histories suggest a much higher incidence. In the majority of cases the joint involvement was mild, affecting particularly the proximal interphalangeal joints of the hands and knees; we found no involvement of the interphalangeal joints of the toes like that observed in

cases of ulcerative colitis (Bywaters and Ansell, 1958). The arthritis tended to be self-limiting and of short duration, and did not lead to clinical deformities or radiological abnormalities. It was not associated with positive sheep cell agglutination tests or with the presence of anti-nuclear factor in the blood.

Our findings confirm a close association with ankylosing spondylitis. Acheson (1960), reviewing the case records of 742 cases of regional enteritis and 1,175 of ulcerative colitis, found 22 of the former, three of the latter, and one with both conditions recorded as having ankylosing spondylitis. Previously, in reviewing 399 patients with ankylosing spondylitis, Steinberg and Storey (1957) had noted four with ulcerative colitis, one with regional enteritis, and one with both disorders. The incidence of chronic ankylosing spondylitis found in this survey in males may well be due to the care with which the patients were questioned and examined and concurs with the 6 per cent. incidence of ankylosing spondylitis found by Zvaifler and Martel (1960) in their review of 100 cases of chronic ulcerative colitis. It is of interest that, in addition to the classical disease, sacro-iliitis has been observed in

two other male patients with back-ache, as well as in three patients with peripheral arthritis. The peripheral arthritis seen in three of our patients in association with possible or definite ankylosing spondylitis was relatively mild, but tended to be recurrent.

Since this survey was completed, however, a patient has been seen with ankylosing spondylitis (Case 4) with severe hip involvement with narrowing and erosive changes (Fig. 2). In only two of our patients did the symptoms of ankylosing spondylitis antedate those of the bowel disorder; this is in contrast with the findings of Acheson (1960). There was no very obvious relationship between bowel activity and joint pathology, but the assessment of bowel activity is extremely difficult. This accords with the view of Ford and Vallis (1959). Contrary to the suggestion of Daffner and Brown (1958) that rheumatic manifestations might be associated with colonic involvement, there was no greater incidence of overt colonic involvement in our patients with rheumatic manifestations than in those without.

Erythema nodosum appears to be less common in this disorder than in ulcerative colitis. Thus Van Patter and others (1954) recorded it in five of 600 cases, and Daffner and Brown (1958) in two of 100 cases, and we obtained a history of it in only two patients.

Both Daffner and Brown (1958) and Acheson (1960) draw attention to the incidence of eye complications, uveitis and episcleritis, but in the series

under review, the only ocular complication seen was conjunctivitis. This may, of course, be due to the smallness of the group surveyed, as we have certainly observed ocular lesions in cases seen before and after the survey (*e.g.* Case 4).

The incidence of psoriasis (in five patients) is a little higher than would be expected, but again may well be due to the smallness of the sample.

Summary

(1) 37 males and 54 females with regional enteritis were questioned and examined with regard to the incidence of rheumatic complaints.

(2) At the time of the survey, polyarthritis was present in six patients (four female and two male); a history of arthritis was obtained in five males and seven females, and in two of the females this was associated with erythema nodosum. The polyarthritis tends to be mild and migratory, resolving without residua over a short period, but it may recur; occasionally it is severe enough to warrant steroid therapy.

(3) Ankylosing spondylitis was diagnosed clinically and confirmed radiologically in four males and one female, and it was thought that a fifth male might well be suffering from this disorder. Three of these six patients had an associated peripheral arthritis. Radiologically, sacro-iliitis was present in a total of eighteen patients, which

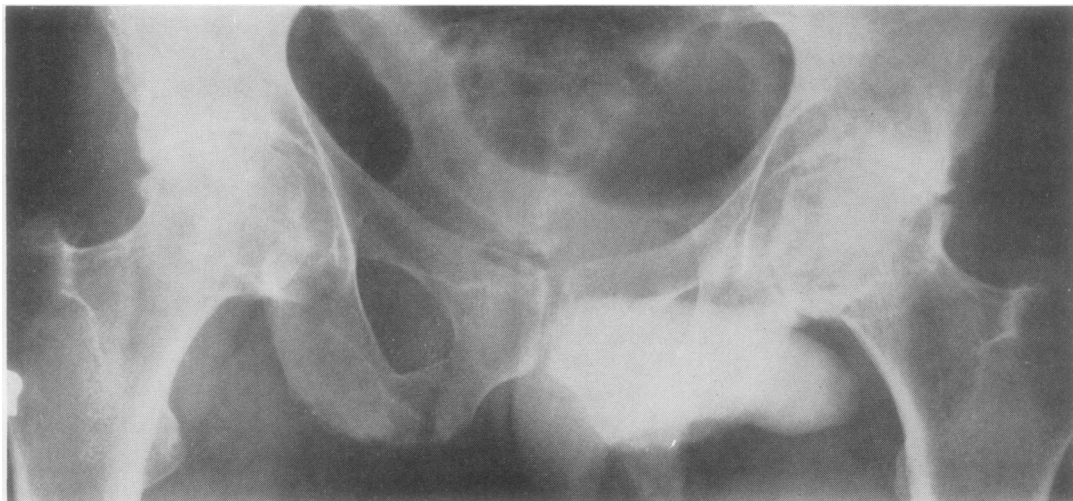

Fig. 2.—Narrowing, sclerosis, and erosive changes in the hips in a man aged 34 years (Case 4, see appendix), with an 11-year history of ankylosing spondylitis and regional enteritis.

included the six diagnosed as possible or definite cases of ankylosing spondylitis, two with psoriasis, and one who had had Reiter's syndrome. Even when the last three were excluded, there was a significantly greater incidence of sacro-iliitis, particularly in the males, as compared with the controls.

We should like to thank Drs. Avery-Jones, Kelloch, and Leonard-Jones and Mr. Henley at the Central

Middlesex Hospital; Drs. Coghill, Deane, and Parry, and Mr. Shoenfield at the West Middlesex Hospital; Mr. Ramsey at Taplow; and Drs. Booth and J. Stewart at Hammersmith Hospital, not only for allowing us to do this survey, but also for their help in the initial sorting of case records to obtain classical cases, and for their wonderful co-operation in allowing us to see patients both in the wards and in their out-patient departments. We should also like to thank Mr. Todd for his permission to include Case 4.

APPENDIX

Case Reports

Case 1.—In 1952, a 21-year-old man had sudden swelling of all the proximal interphalangeal joints of both hands which persisted for 3 to 4 months. In 1958 he first developed recurrent fever for which no cause could be found and only subsequently did bowel symptoms occur; a diagnosis of regional enteritis was made on the typical radiological findings. In 1959, swelling of the proximal interphalangeal joints of both hands recurred with oedema of the dorsum of the right hand and difficulty in straightening the fingers on that side. As the bowel symptoms became more severe, a resection of gut was performed and the joints became normal within days. One year later a recurrence of stiffness of the hands was followed by swelling of the proximal interphalangeal joints and both knees, and some weeks later there was a relapse of the bowel condition. A further resection was required, after which the joints improved, but the stiffness of the fingers with swelling of the proximal interphalangeal joints continues to recur and an attack may last for up to 3 weeks. The differential agglutination test and latex-fixation test are negative and no erosions were seen in the x ray of the hands in 1962.

Case 2.—In 1942, a 30-year-old female first developed bowel symptoms: surgery was undertaken early and was followed by some improvement, but she never became symptom-free. In 1955, at the time of an exacerbation of bowel symptoms, she first noticed stiffness of the hands and knees in the morning. Prednisone 15 mg. daily was administered for the bowels and the stiffness rapidly improved. In 1960, while on 10 mg. prednisone daily, the morning stiffness of the hands recurred, followed by swelling of the proximal interphalangeal joints, wrists, knees, and ankles. These settled, but in January, 1961, while under investigation for malabsorption, the dose of steroid was reduced and stopped. This was followed by acute swelling of all the proximal interphalangeal joints, both wrists, and the right knee. As this had not settled in 2 months, the steroid was re-introduced, and she has continued to take 12.5 mg./day, primarily for the joints. On this treatment she has only slight joint symptoms—residual swelling and limitation of the right wrist and a small effusion in the right knee. The erythrocyte sedimentation rate is 22 mm./1st hr (Westergren), the differential agglutination test and

latex-fixation test are negative, anti-nuclear factor negative, x rays of peripheral and sacro-iliac joints normal.

Case 3.—In 1948, at the age of 16 years, this man first developed abdominal symptoms and 3 years later underwent surgery for intestinal obstruction when a segment of diseased ileum was removed. In 1953 a further laparotomy was performed because of persistent abdominal pain, and a stenosed section of intestine was resected. About this time, he had his first attack of pain in the left hip, and this responded to short-wave diathermy. In 1958 he noticed aching in the back, right hip, both thighs, manubrio-sternal joint, and shoulders. The back movements were full, but there was marked pain on sacro-iliac compression. Other involved joints showed full but painful movement and there was soft tissue swelling and tenderness of the manubrio-sternal joint. Radiologically there was sclerosis of the left sacro-iliac joint. Prednisone 30 mg. daily was started and both bowel and joint symptoms rapidly improved. In July, 1959, he underwent further surgery for a faecal fistula, and the bowel symptoms improved. In September, 1960, the prednisone was cut to 10 mg. daily and after this stiffness of the back and shoulders developed, particularly marked in the mornings. There was restriction of movement of the lower thoracic and upper lumbar spine so that he was unable to touch the floor by 10 inches. In May, 1961, because of a gastric ulcer, the prednisone was reduced and stopped. This caused an acute exacerbation of arthritis with aching in all joints, swelling of both knees, pain in both heels, and 7 days later marked limitation of movement of the cervical spine. The thoracic and lumbar spine was held immobile and the movement of both hips was limited by severe pain. Both knees contained effusions and both heels were tender. There was pain on breathing with tenderness of the costochondral junctions 3, 4, 5, 6, and 7 on the left. Phenylbutazone was given with food in divided doses, and, although this helped the symptoms, epigastric pain recurred. An exacerbation of joint symptoms in September, 1961, was associated with swelling of the proximal interphalangeal joints of both hands and a new fistula appeared in the right iliac fossa. Although the erythrocyte sedimentation rate was only 14 mm./1st hr, the C-reactive protein was strongly positive.

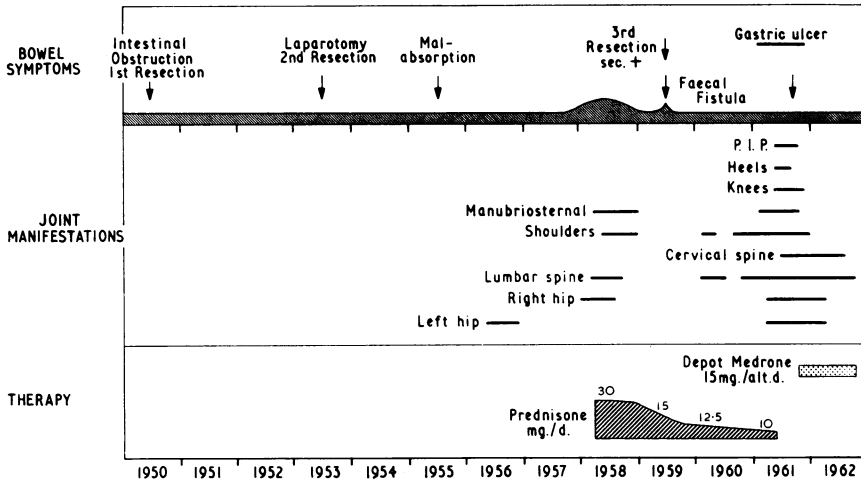


Fig. 3.—Pattern of involvement in a man aged 16 years at the onset of bowel symptoms (Case 3), who developed ankylosing spondylitis with peripheral joint involvement during the course of the regional enteritis.

It was decided to re-introduce steroid treatment with methyl prednisolone acetate (Depo-Medrone) 20 mg. intramuscularly on alternate days. The response was good, so that one month later the dose could be reduced to 15 mg. three times weekly (Fig. 3), but no further reduction has been possible.

Although the patient still has some symptoms and signs in the back, the peripheral joints have improved and he is able to work. Radiologically, the sacro-iliac joints show increasing sclerosis and early spinal involvement.

Case 4.—In January, 1951, a 23-year-old man first had pain in the lumbar region which lasted only a few days. In December, 1951, he developed diarrhoea which persisted for 2 weeks. In February, 1952, he had a recurrence of back pain and diarrhoea, and he was considered to be suffering from ulcerative colitis. The bowels improved after 5 weeks, but the back continued painful, so that in November, 1952, he was given deep x-ray therapy to the spine. He was then completely well until 1954 when he had a recurrence of bowel symptoms for which he had a sub-total colectomy with ileostomy and 8 months later an ileorectal anastomosis was performed. The histology showed Crohn's disease. In 1956 he noticed recurrent pain in the back and progressive stiffness which has steadily increased despite periods of intensive physiotherapy and phenylbutazone. In 1960 he had a first attack of iritis involving the left eye and in the following year both eyes were affected. By 1962 the thoracic and lumbar spine was completely immobilized with severe limitation of extension and rotation of the cervical spine, bony swelling of the left sterno-clavicular joint, limitation of all movements in both hips, and chest expansion reduced to 1 inch. Radiology showed fusion of the sacro-iliac joints (Fig. 4, opposite), with irregular bony fusion in the lumbar spine and fusion of apophyseal joints in the cervical spine (Fig. 5, opposite). The hips showed narrowing, sclerosis, and erosive changes as

reported above (Fig. 2). The differential agglutination test, latex-fixation test, and anti-nuclear factor were negative.

REFERENCES

Acheson, E. D. (1960). *Quart. J. Med.*, n.s. **29**, 489.
 Bywaters, E. G. L., and Ansell, B. M. (1958). *Ann. rheum. Dis.*, **17**, 169.
 Crohn, B. B., and Yarnis, H. (1958). "Regional Ileitis", 2nd ed. N.Y.
 Daffner, J. E., and Brown, C. H. (1958). *Ann. intern. Med.*, **49**, 580.
 Dixon, A. St. J., and Lience, E. (1961). *Ann. rheum. Dis.*, **20**, 247.
 Ford, D. K., and Vallis, D. G. (1959). *Arthr. and Rheum.*, **2**, 526.
 Holborow, E. J., Weir, D. M., and Johnson, G. D. (1957). *Brit. med. J.*, **2**, 732.
 Rose, H. M., Ragan, C., Pearce, E., and Lipman, M. O. (1948). *Proc. Soc. exp. Biol. (N.Y.)*, **68**, 1.
 Singer, J. M., and Plotz, C. M. (1956). *Amer. J. Med.*, **21**, 888.
 Steinberg, V. L., and Storey, G. (1957). *Brit. med. J.*, **2**, 1157.
 Van Patter, W. N., Bargaen, J. A., Dockerty, M. B., Feldman, W. H., Mayo, C. W., and Waugh, J. M. (1954). *Gastroenterology*, **26**, 347.
 Zvaifler, N. J., and Martel, W. (1960). *Arthr. and Rheum.*, **3**, 76.

DISCUSSION

DR. V. WRIGHT (*Leeds*): We have also been interested in this problem and have come to similar conclusions. In our investigation of patients with ulcerative colitis and Crohn's disease we now have 230 cases with ulcerative colitis. The sacro-iliac joints have all been examined radiologically. Our preliminary analysis is of interest in relation to ulcerative colitis. We have found a

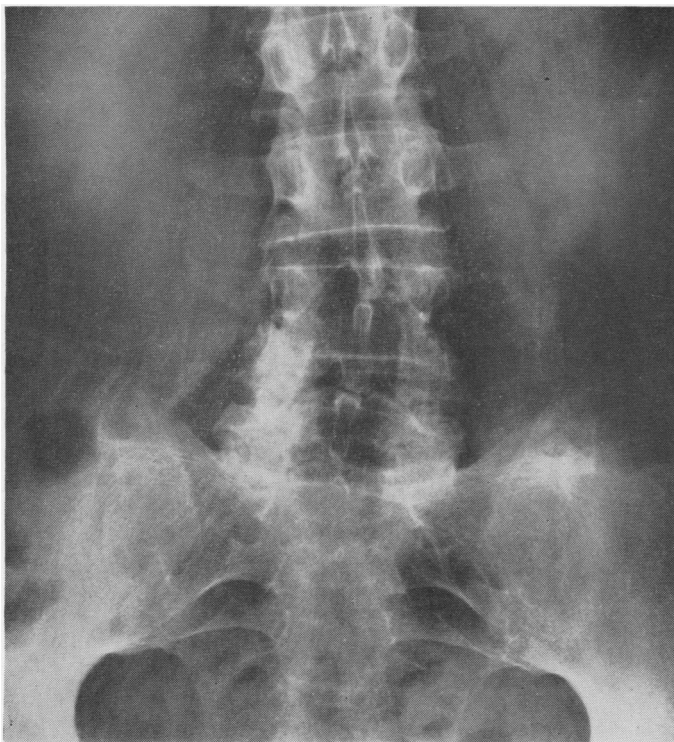


Fig. 4.—Obliteration of sacro-iliac joints and commencing bony bridging L 3-4 (Case 4).

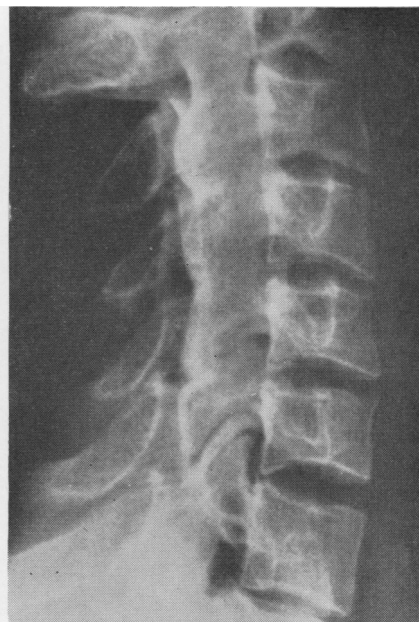

Fig. 5.—Bony fusion of apophyseal joints with early changes along the anterior vertebral bodies (Case 4).

percentage incidence of sacro-iliitis similar to that quoted by Dr. Ansell (16·8 per cent.).

I should like to know if Dr. Ansell found a family history of psoriasis in the patients with Crohn's disease? We were interested to find that 10 per cent. of first-degree relatives of patients with Crohn's disease had a history of psoriasis contrasted with 2 per cent. of an unselected group with rheumatoid arthritis.

Has Dr. Ansell any data on the correlation of the sacro-iliac involvement and peripheral arthritis? We have found a definite correlation in the patients with colitis—particularly in the females—between those with sacro-iliac joint involvement and those with peripheral inflammatory arthritis.

How many of the sacro-iliac changes were read from barium enemas rather than from films taken specifically for sacro-iliac joint changes? We have done some comparative work with barium enema films and sacro-iliac joint films taken for the purpose, and there seems little doubt that those of the sacro-iliac joints give a far more accurate picture than the barium enema films.

DR. ANSELL: In the time available I obviously could not include all our data on the patients studied, but I will answer these questions in order:

(1) We found a total of five patients with psoriasis. There was a family history of psoriasis in a number of relatives and there was also a family history of rheumatic complaints in some, *e.g.* ankylosing spondylitis in the father of the one woman with ankylosing spondylitis.

(2) Of our six females with bilateral sacro-iliac changes, two had frank peripheral polyarthritis and one had had arthritis with erythema nodosum, *i.e.* half the females with sacro-iliac change. Only one of our males with sacro-iliac lesions had a history of peripheral polyarthritis apart from the two diagnosed as cases of spondylitis.

(3) A film of the sacro-iliac joints was taken for all patients with any form of arthritis, and I think that I had to rely on barium enemas or barium meals in 29 cases only.

Manifestations arthritiques dans l'entérite régionale

RÉSUMÉ

1. On a interrogé et examiné 37 hommes et 54 femmes atteints d'entérite régionale à propos de la fréquence des manifestations rhumatismales.

2. Au temps de l'enquête, la polyarthrite était présente chez six malades (4 femmes et 2 hommes); des antécédents personnels d'arthrite existaient chez

5 hommes et 7 femmes, et chez deux de ces femmes l'érythème noueux s'y trouvait associé. La polyarthrite tendait à être bénigne et migratoire, disparaissant sans sequelles dans une période très courte, mais capable de revenir; de fois à autre elle était assez sévère pour justifier une thérapie stéroïde.

3. La spondylarthrite ankylosante fut reconnue cliniquement et confirmée radiologiquement chez 4 hommes et une femme, et on pensa qu'un cinquième homme puisse en être atteint. Trois d'entre eux présentèrent aussi une arthrite périphérique associée. Du point de vue radiologique l'atteinte sacro-iliaque exista chez 18 malades en tout, y compris les six cas de spondylarthrite ankylosante confirmée ou probable, deux cas de psoriasis et un cas de syndrome de Reiter. Même si on en exclut les trois derniers cas, la fréquence de l'atteinte sacro-iliaque, surtout chez les hommes, fut appréciablement plus grande que chez les témoins.

Manifestaciones artríticas en la enteritis regional

SUMARIO

1. Se interrogaron y examinaron 37 hombres y 54

mujeres con enteritis regional respecto a la frecuencia de manifestaciones reumáticas.

2. Al tiempo de la investigación, la poliartritis fue presente en seis enfermos (4 mujeres y 2 hombres); antecedentes personales de artritis existieron en 5 hombres y 7 mujeres y en dos de éstas se observó además el eritema nodoso. La poliartritis tendió a ser benigna y migratoria, resolviéndose sin secuela en un tiempo muy corto, pero con capacidad de recaída; a veces fue bastante grave para justificar una terapia esteroide.

3. La espondilartritis anquilosante fue diagnosticada clínicamente y confirmada radiológicamente en cuatro hombres y en una mujer; se cree también que un quinto hombre padeció posiblemente de esta enfermedad. Tres de estos presentaron además una artritis periférica. Desde el punto de vista radiológico una sacro-iliitis existió en un total de 18 enfermos, incluyendo seis casos de espondilartritis anquilosante confirmada o probable, dos casos de psoriasis y un caso de síndrome de Reiter. Aun cuando se excluye los tres últimos casos, la frecuencia de sacro-iliitis, particularmente en los hombres, fue significativamente mayor que en los testigos.