

Short report

Clinicopathological correlation in a case of painful ophthalmoplegia: Tolosa-Hunt syndrome

P J GOADSBY, J W LANCE

From the Department of Neurology, The Prince Henry Hospital and School of Medicine, University of New South Wales, Sydney, Australia

SUMMARY A case of painful ophthalmoplegia due to idiopathic granulomatous involvement of the superior orbital fissure (Tolosa-Hunt syndrome) is described. The clinical features of recurrent pain, ocular motor nerve palsies and proptosis correlated well with the eventual demonstration of an enhancing mass in the region of the cavernous sinus. Removal of the lesion led to a resolution of the clinical picture and demonstration of a non-caseating granuloma with no other detectable cause. The original observation of Tolosa was thus re-affirmed.

Recurrent painful ophthalmoplegia is a rare condition first described by Tolosa¹ in a male patient who had died soon after an operation to explore the sella turcica for left retro-orbital pain and ophthalmoplegia. At necropsy there was granulomatous tissue surrounding the left intracavernous carotid. Hunt² further characterised the syndrome by noting its responsiveness to steroid therapy. Although there have been over two hundred cases³ reported since, pathological descriptions have been limited to Tolosa's and to two further confirmatory descriptions of granulation tissue lining the superior orbital fissure.^{4,5} Another example is described in which the clinical and CT findings correlate closely and pathological examination confirmed the presence of a granuloma.

Case report

The patient, a 56 year old retired soldier, presented initially in 1982 with a 10 week history of left-sided throbbing headache, retro-orbital pain, nausea and diplopia. A left sixth nerve palsy was the only finding on physical examination. Blood count, erythrocyte sedimentation rate (ESR), serum elec-

trolytes, fasting blood glucose level, liver enzymes, glucose tolerance test, coagulation profile and electrocardiograph were all within normal limits. At lumbar puncture the CSF was clear and colourless with no cells and a protein content of 0.55 g/l. An endrophenium (*Tensilon*) test was negative and radiography of the paranasal sinuses unremarkable. A cerebral CT scan and bilateral carotid angiogram demonstrated no abnormalities. The provisional diagnosis of temporal arteritis was made and treatment with prednisolone was started. The pain resolved over the ensuing two weeks and the diplopia over the next eight months. Twelve months later, steroid therapy was discontinued but the headaches recurred six months later, on this occasion without any ocular signs. Steroid therapy was recommenced, again with a good response and he experienced few headaches over the following years until 1985. In October, 1985, he presented for review of polydipsia and polyuria. Diabetes mellitus was diagnosed and the steroid therapy was withdrawn. His headache soon became much worse while his blood sugar level returned to normal. In January, 1986, he was referred to the Neurology Clinic for review with a daily throbbing headache and a left proptosis. A cerebral CT scan was again normal. He was started on pizotofen (1.5 mg nocte) with amelioration of his headaches for three months after which they recurred. At review in May, 1986, proptosis had resolved and therapy with methysergide was initiated with six months of relief. By early 1987 the headaches returned and a trial of naproxen proved unsuccessful. By mid-1987 the headaches were a major problem; a left proptosis and left sixth nerve lesion had recurred with the addition of a partial left third nerve palsy. Cerebral CT and left carotid angiogram were normal. The third nerve and retro-orbital space were explored and some thickening of the third nerve was noted, although no mass lesion was seen. Post-operatively both his eye signs and headache resolved.

Correspondence to: Dr P J Goadsby, Department of Neurology, Clinical Sciences Building, The Prince Henry Hospital, Little Bay NSW 2036 Australia.

Received 10 January 1989 and in revised form 29 March 1989.
Accepted 6 April 1989

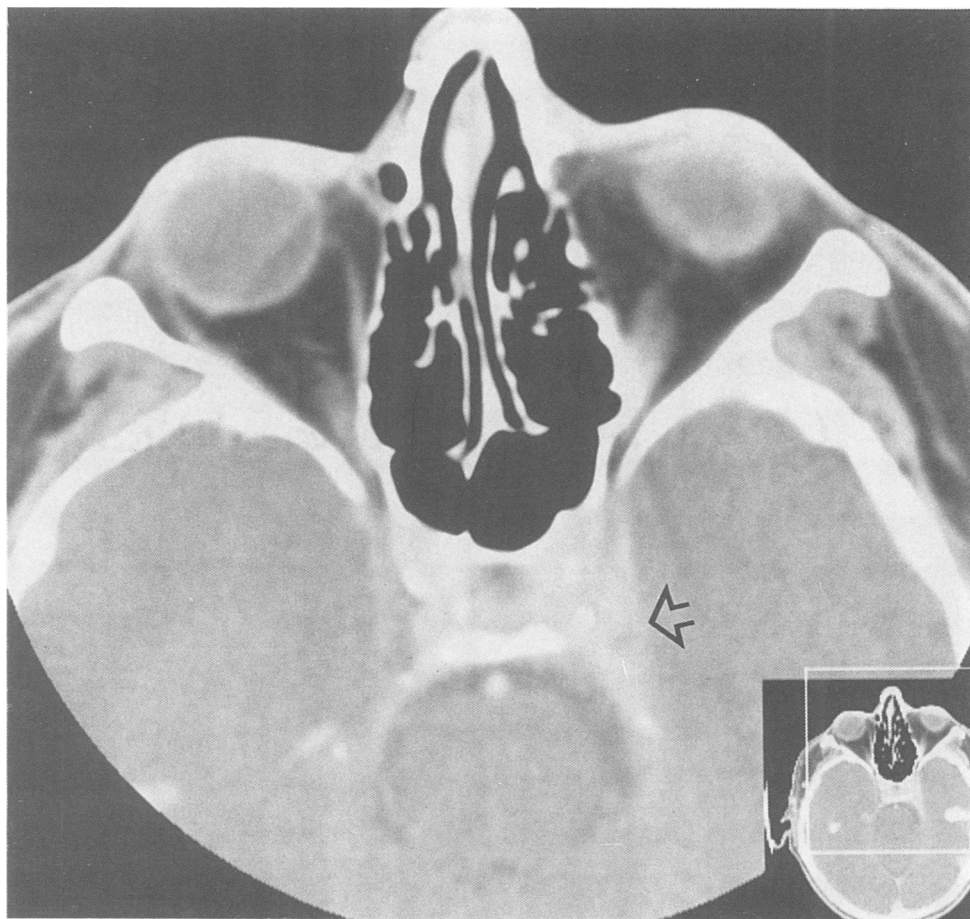


Fig 1 A cerebral CT scan with intravenous contrast showing an enlarged view of the orbit. A contrast-enhancing lesion is demonstrated against the medial wall of the left cavernous sinus.

His headaches returned in late 1987 and were refractory to all medical therapy. The pain had changed somewhat and become constant with sharp jabs in the distribution of ophthalmic division of the trigeminal nerve. A posterior fossa exploration (Jannetta procedure) provided no relief and section of the ophthalmic division of the trigeminal nerve was then undertaken with abolition of the headache. In September, 1988, he returned with a two week history of diplopia. On examination there was left proptosis and left third nerve and sixth nerve palsies. CT demonstrated an enhancing lesion along the left cavernous sinus (figs 1 and 2). A left carotid angiogram was normal. At craniotomy a 5 mm diameter granuloma was removed (fig 3). At follow up two months later he was pain-free and his ocular signs had resolved significantly with some slight weakness remaining in the left lateral rectus.

Discussion

A case of painful ophthalmoplegia due to non-specific granuloma of the retro-orbital region, the Tolosa-Hunt syndrome, is described. The clinicopathological correlation in this case is precise in that the lesion suspected clinically was eventually demonstrated on CT and then excised, leading not only to resolution of signs but also to a clear pathological diagnosis, a rarity in the case-reports of this disorder.

Recently the aetiology has been called into question by the suggestion that the syndrome may be caused by vasculitis⁶ and orbital venography had been used in the diagnosis.⁷ This case, however, certainly re-affirms the

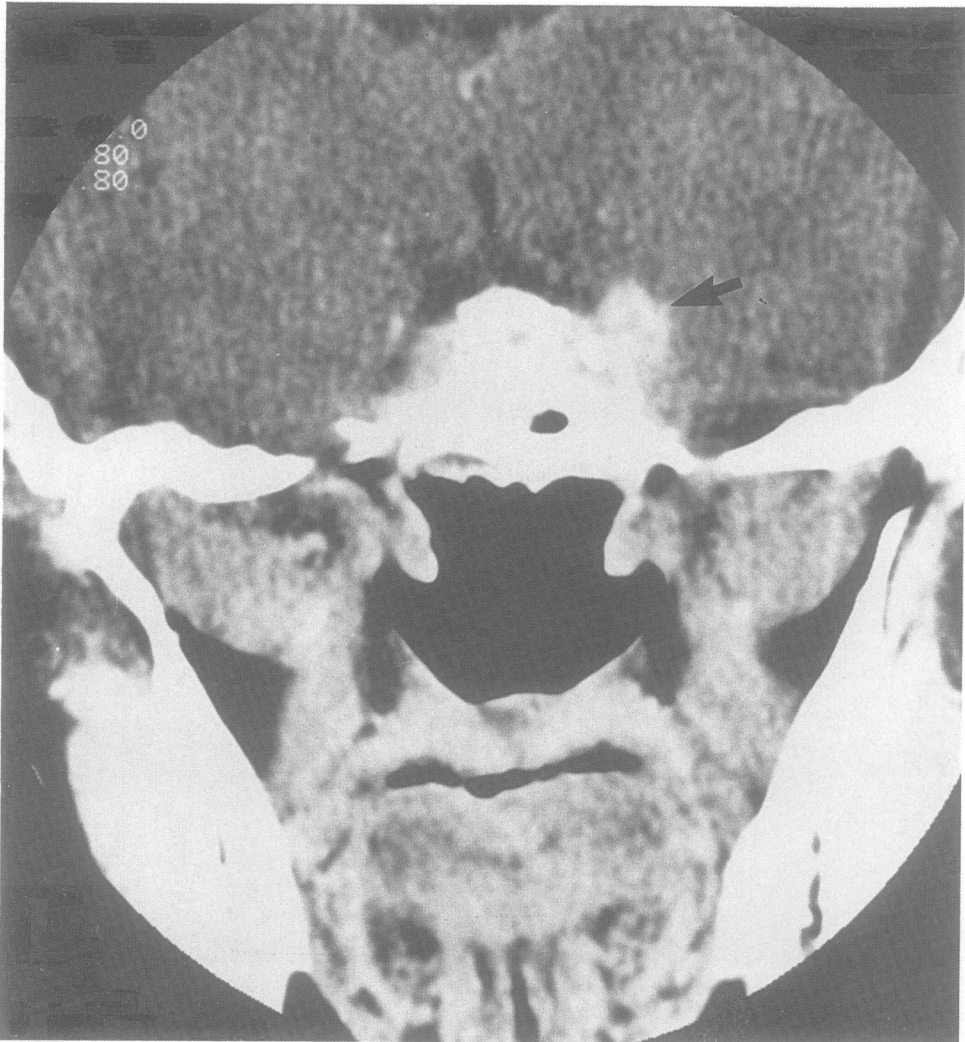

Fig 2 A cerebral CT scan with intravenous contrast showing a coronal slice through the anterior cranial fossa. A contrast-enhancing lesion is again demonstrated near the medial wall of the cavernous sinus.

original findings reported by Tolosa.¹ The case was somewhat atypical in that the patient's retro-orbital pain was often throbbing whereas the pain in this condition has usually been described as boring or stabbing.⁸ The patient's pain did assume a stabbing quality for a short period before operation.

The main differential diagnoses in this setting are: diabetic ophthalmoplegia (excluded by the normal fasting blood sugar levels and normal glucose tolerance test); carotid aneurysm (excluded by the repeatedly normal angiograms) and tumours of the nasopharynx and orbit (not demonstrated by repeated CT examinations). In this instance after repeated

examinations, CT revealed the diagnosis. Similar CT findings have been reported by others,^{9,10} but without the benefit of pathological correlation.

In summary, a case of Tolosa-Hunt syndrome with painful ophthalmoplegia caused by idiopathic retro-orbital granuloma, is presented. The case history is almost identical to that described by Tolosa and provides a rare affirmation of the pathology of this unusual condition.

The authors thank the Department of Medical Illustration, University of New South Wales, for photographing the figures.

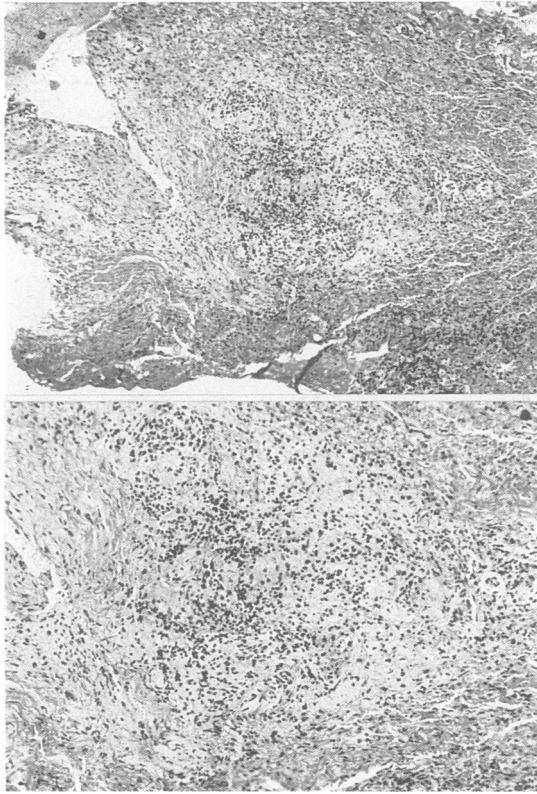


Fig 3 A photomicrograph of the mass removed at operation. A granulomatous lesion with some multinucleated giant cells is demonstrated (A: $\times 78$; B: $\times 120$).

References

- 1 Tolosa E. Periarteritic lesions of the carotid siphon with the clinical features of a carotid infraclinoidal aneurysm. *J Neurol Neurosurg Psychiatry* 1954;**17**: 300-2.
- 2 Hunt WE, Meagher JN, LeFever HE, Zeman W. Painful ophthalmoplegia. Its relation to indolent inflammation of the cavernous sinus. *Neurology* 1961;**11**:56-62.
- 3 Hoes MJAJM, Bruyn GW, Vielvoye GJ. The Tolosa-Hunt syndrome- literature review: seven new cases and a hypothesis. *Cephalalgia* 1981;**1**:181-94.
- 4 Lakke JP. Superior orbital fissure syndrome: report of a case caused by local pachymeningitis. *Arch Neurol* 1962;**7**:289-300.
- 5 Schatz NJ, Farmer P. Tolosa-Hunt syndrome: the pathology of painful ophthalmoplegia. In: Smith JL ed. *Neuro-ophthalmology Vol. 6*. St Louis: Mosby Co., 1972:102-12.
- 6 Hannerz J. Pathoanatomic studies in a case of Tolosa-Hunt syndrome. *Cephalalgia* 1988;**8**:25-30.
- 7 Sondheimer FK, Knapp J. Angiographic findings in the Tolosa-Hunt syndrome: painful ophthalmoplegia. *Radiology* 1973;**106**:105-12.
- 8 Hannerz J. Pain characteristics of painful ophthalmoplegia (the Tolosa-Hunt syndrome). *Cephalalgia* 1985;**5**:103-6.
- 9 Thomas DJB, Charlesworth MC, Afshar F, Galton DJ. Computerised axial tomography and magnetic resonance scanning in the Tolosa-Hunt syndrome. *Br J Ophthalmol* 1988;**72**:299-302.
- 10 Neigel JM, Rootman J, Robinson RG, Durity FA, Nugent RA. The Tolosa-Hunt syndrome: computed tomographic changes and reversal after steroid therapy. *Can J Ophthalmol* 1986;**21**:287-90.