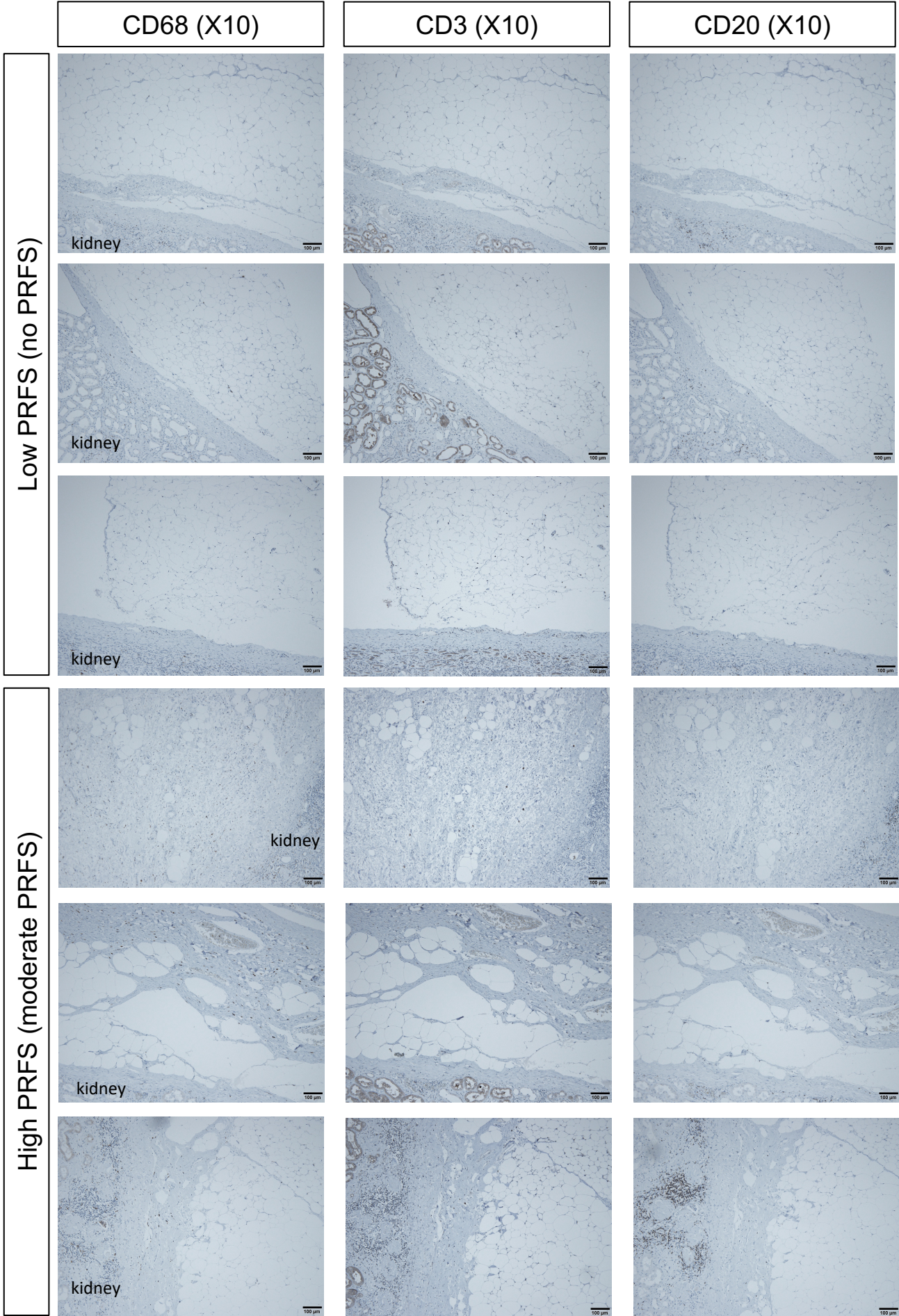


Supplementally Figure 2. CD68, CD3 and CD20 staining for perirenal fat of 3 patients without ipsilateral PRFS (low PRFS) and 3 patients with ipsilateral moderate PRFS (high PRFS).



PRFS, perirenal fat stranding