

# Autosomal recessive hereditary motor and sensory neuropathy with mental retardation, optic atrophy and pyramidal signs

K D MACDERMOT,\* R W H WALKER†

*From the Clinical Research Centre, Harrow and the Kennedy Galton Centre,\* Radlett, and The National Hospital for Nervous Diseases,† Queen Square, London, UK*

**SUMMARY** A syndrome is described, consisting of severe neurogenic distal wasting, generalised muscle weakness, absent ankle reflexes, pyramidal signs, mental retardation, optic atrophy and retinal colloid bodies. A sural nerve biopsy from one case showed loss of nerve fibres suggesting the diagnosis of hereditary motor and sensory neuropathy. Progression of the disorder was very slow, all patients still being able to walk more than 20 years after the onset. The persons affected with this syndrome were two brothers and their female cousin from a large Gujarati pedigree where consanguinity was high. Autosomal recessive inheritance is therefore suggested.

Peroneal muscular atrophy is a descriptive term for a group of disorders which are heterogeneous clinically, electro physiologically, genetically and in their pathology. Several distinct entities have been defined, the commonest being hereditary motor and sensory neuropathy types I and II, and the distal form of spinal muscular atrophy.<sup>1-3</sup> Rarer syndromes include combinations of hereditary motor and sensory neuropathy and central nervous system involvement.<sup>3-5</sup> We report here the combination of an axonal motor and sensory neuropathy, pyramidal signs, optic atrophy and mental retardation in three related individuals, which appears to have autosomal recessive inheritance.

## Patients

The proband (V-7 in fig 1) was referred to the genetic clinic because unaffected family members were seeking genetic counselling. He had previously been extensively investigated at St Bartholomew's Hospital. His brother (V-10 in fig 1) had not been investigated previously. Their female first cousin (V-6 in fig 1) had been investigated 10 years previously at the National Hospital for Nervous Diseases, but the family history had been withheld at that time. All three patients were reexamined. Nine other family members were examined clinically and two electrophysiologically.

Address for reprint requests: Dr K D MacDermot, University of Birmingham, Clinical Genetics, Birmingham Maternity Hospital, Edgbaston, Birmingham B15 2TG, UK.

Received 5 December 1986 and in revised form 26 February 1987.  
Accepted 28 February 1987

## Case 1 (V-7)

This 34 year old Indian male was born after a normal pregnancy and delivery. In the first year of life he had feeding difficulty and unexplained failure to thrive. His psychomotor milestones were uniformly delayed; he did not walk unaided until the age of 3 years. Wasting and weakness of lower limbs was noted at the age of 8 years, followed by similar involvement of his hands. Progression of the wasting and weakness had been very slow, but there was an exacerbation of weakness and deterioration of intellect 3 years before, when he was treated for pulmonary tuberculosis. The drugs given at that time were: rifampicin, 450 mg daily; isoniazid, 300 mg daily; ethambutol, 700 mg daily, and pyridoxine 20 mg daily.

On examination, he obeyed only simple commands and his cooperation was limited. His head circumference was 54.5 cm. The skull shape was normal and there were no dysmorphic features. He had bilateral optic atrophy and macular colloid bodies (fig 2b). The retinal vessels were normal. Both pupils were small and irregular, and did not react to light. Divergent strabismus was apparent, with pendular nystagmus in the primary position as well as gaze evoked nystagmus in all directions except downwards. He had a brisk jaw jerk, and a pout reflex. Severe symmetrical muscle wasting was present in the hands, forearms, feet and lower legs. Fasciculations were seen in both triceps muscles. Both hands were clawed in posture, without contractures. Spasticity was present in upper limbs. Small hand muscles were weak. There was no active movement of toes or feet. Ankle reflexes were absent, but all other reflexes were pathologically brisk. The abdominal reflexes were present. Plantar responses were absent. There was no spine deformity.

## Case 2 (V-10)

After a normal pregnancy and delivery this 33 year old

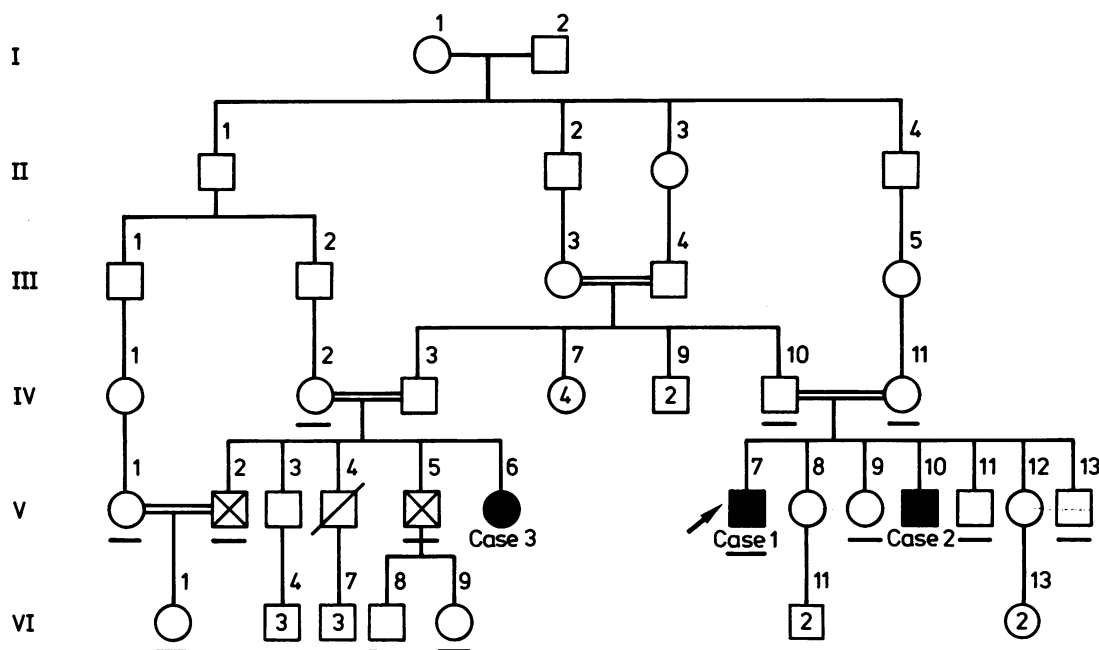


Fig 1 The pedigree of the family. The index case is arrowed.  $\square$  = male,  $\circ$  = female,  $\blacksquare$  = affected male,  $\bullet$  = affected female,  $\square$  = deceased,  $\boxtimes$  = affected by retinitis pigmentosa, — = examined family member, [2], [3], [4] = number of unaffected siblings.

brother of Case 1 also had feeding difficulty in the first year of life. His psychomotor milestones were uniformly delayed; he walked unaided at the age of 5 years. At the age of 3 years he underwent a linear coronal craniectomy in India because of suspected craniosynostosis. Wasting and weakness of his legs were first noticed at the age of 8 years. On examination, he was uncooperative and did not reliably obey simple commands. His vocabulary in Gujarati was very limited. The skull shape was normal (the craniectomy incision was palpable) and the head circumference was 53.5 cm. He had bilateral optic atrophy. Detailed examination of his fundi was not possible because of poor cooperation. The pupils were of normal size and reacted normally to light. Severe distal wasting was present in upper and lower limbs (fig 2a). Early Dupuytren's contractures were palpable in both palms, but no muscle or joint contractures were present. Tone was increased (spastic) in upper limbs. Weakness affected distal upper and lower limb muscles with no power at the ankles or in either foot. Ankle reflexes were absent. Other tendon reflexes were pathologically brisk. The plantar responses were absent.

#### Case 3 (V-6)

This 35 year old woman was a first cousin of Cases 1 and 2. She was born after a normal pregnancy, but the delivery was prolonged with some initial breathing difficulty. All her psychomotor milestones were delayed. Weakness of her lower limbs was noted at the age of 9 years and within 2 years had spread to involve upper limbs. She was investigated at the age of 22 years, at which time there had been no deterioration for 5 years. Her intellectual function was formally

assessed through an interpreter. She was unable to score anything on any standardised tests, apart from a couple of marks on arithmetic. She was unable to write her own name. Even from limited testing it was quite clear that she was of severely defective intelligence. Over the ensuing 10 years, progression of her symptoms was negligible. On examination, her head circumference was 51 cm and she had no dysmorphic features. Bilateral optic atrophy was present, with colloid bodies at both maculae. The pupils were unremarkable. She had a brisk jaw jerk and a pout reflex. Marked distal symmetrical wasting affected upper and lower limbs. In contrast to her cousins, tone in her upper and lower limbs was reduced throughout. There was severe distal weakness in upper and lower limbs. Upper limb reflexes were normal. Knee and adductor reflexes were abnormally brisk. Ankle and plantar reflexes were absent. She had a moderately severe thoracic scoliosis.

Sensation was impossible to assess reliably in all three cases because of their poor cooperation and mental retardation. As a crude estimate of visual acuity, they were able to watch television and recognise faces across the room. The female patient could do needlework. The families had not noticed any obvious signs of lack of sensation. In particular, there was no history of accidents, injuries or burns. All three patients could walk in a slow, unsteady fashion, with foot drop. There were no cerebellar signs, and tremor was not a feature. Hearing was normal. None had pes cavus. Peripheral nerves were not thickened.

Family members IV-2, IV-10, IV-11, V-1, V-2, V-5, V-9, V-11, V-13, VI-1, VI-8 and VI-9 were examined. They had no evidence of muscle wasting or weakness, and reflexes and

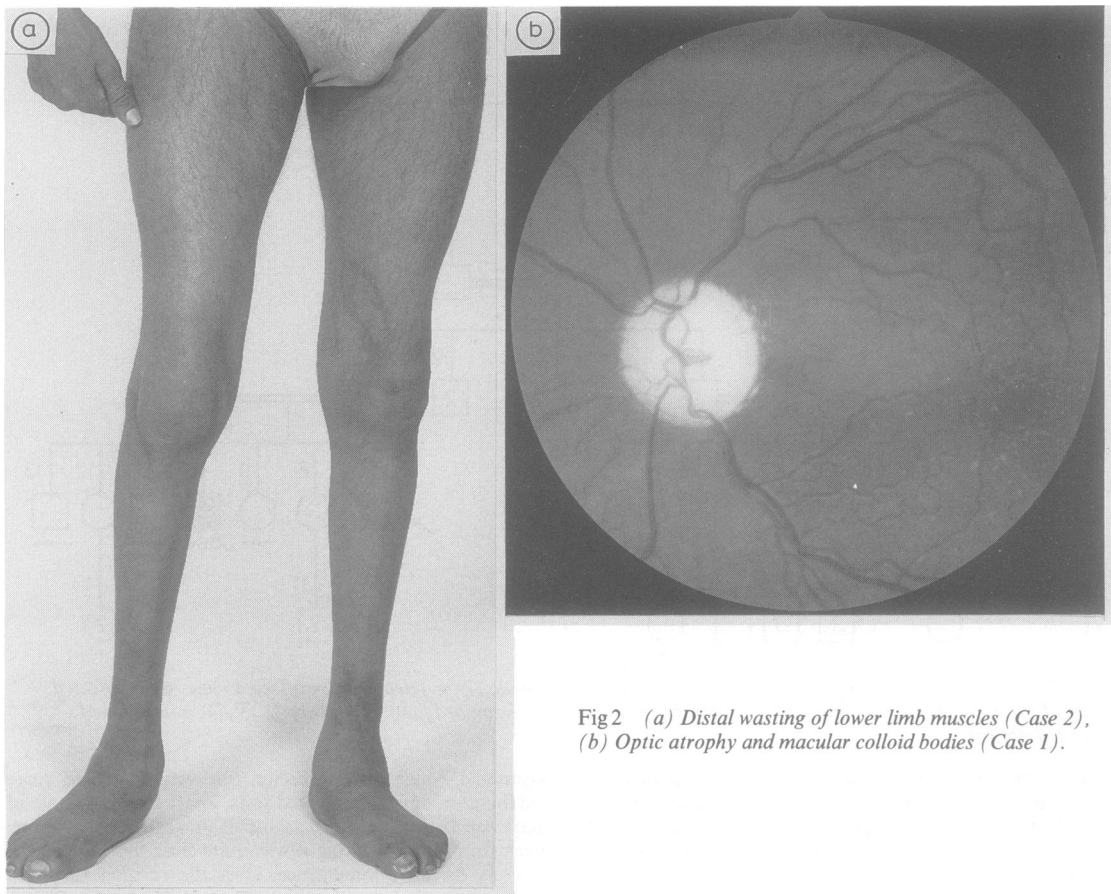


Fig 2 (a) Distal wasting of lower limb muscles (Case 2), (b) Optic atrophy and macular colloid bodies (Case 1).

sensation were normal. The optic fundi showed no optic atrophy or colloid bodies. IV-2 and IV-10 had senile cataracts. V-2 and V-5 gave history of failing vision and night blindness since the age of 5 years. Both were found to have peripheral fundus changes of retinitis pigmentosa (Moorfields Eye Hospital, Prof Barry Jay).

#### Investigations

Routine haematological and biochemical tests were normal, including vitamin B<sub>12</sub>, lipoprotein electrophoresis, treponemal antibody titre, phytanic acid, leucocyte arylsulphatase A and urinary porphyrins. Cerebrospinal fluid cell count, total protein and glucose concentrations were normal in Case 1. Chromosome analysis on all three cases showed normal male and female karyotypes respectively.

Computerised tomography head scans and electrocardiograms were normal in Cases 1 and 3 and in the same patients visual evoked potentials were absent to pattern reversal and flash stimuli. In Case 1, the electroencephalogram showed a low voltage, featureless record with no disturbance of cortical background rhythms, but occasional bifrontal slow wave bursts.

Nerve conduction studies and electromyography (EMG) were performed at the National Hospital by Dr Kerry Mills,

Table Nerve conduction studies

	Case 1	Case 2	Case 3	V-1	IV-11
SAP amplitude* ( $\mu$ V):					
Median	10	ND	15	40	5
Ulnar	6	ND	12	20	16
Sural	2	ND	5	ND	ND
NAP amplitude† ( $\mu$ V):					
Ulnar	ND	40	ND	ND	ND
MCV‡ (m/s):					
Ulnar	41	46	51	54	60

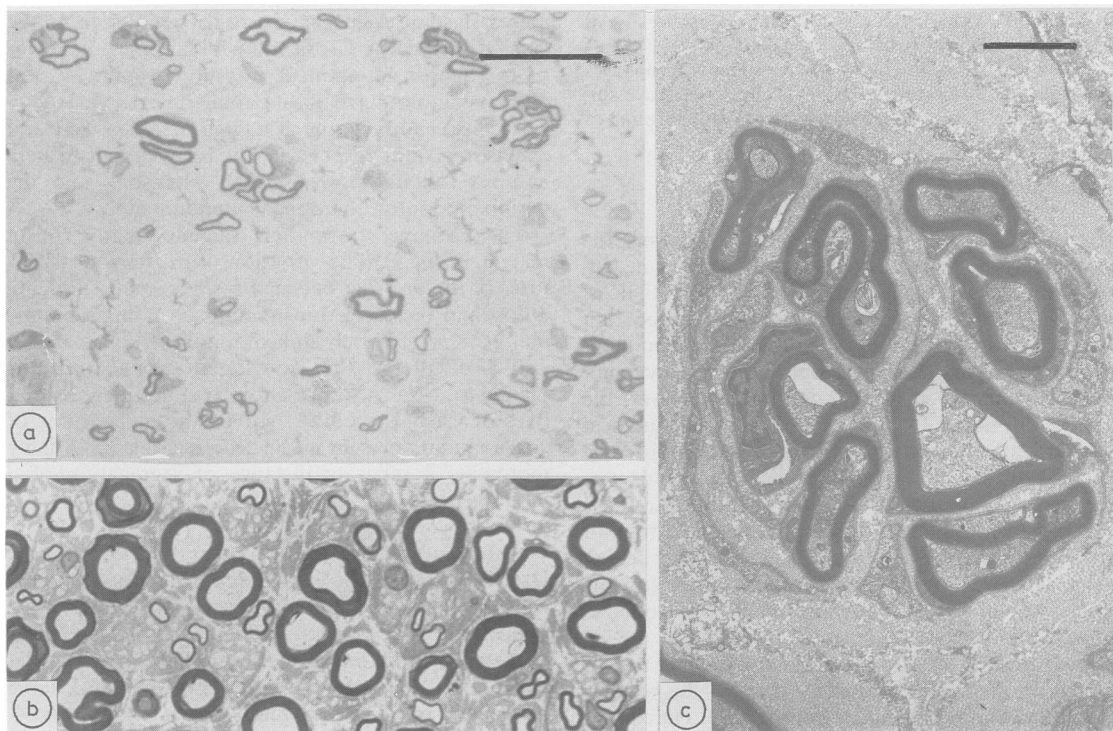
\*SAP = sensory action potentials; the median and ulnar SAPs were recorded orthodromically from second and fifth fingers to wrist, and the sural SAPs antidromically, all using surface electrodes.

†NAP = mixed nerve action potential; wrist to elbow segment, using surface electrodes.

‡MCV = motor conduction velocity, recorded using surface electrodes over abductor digiti minimi (Case 1, V-1 and IV-11, and flexor carpi ulnaris (Cases 2 and 3).

||With other electrophysiological evidence of a right carpal tunnel syndrome.

ND = Not done.



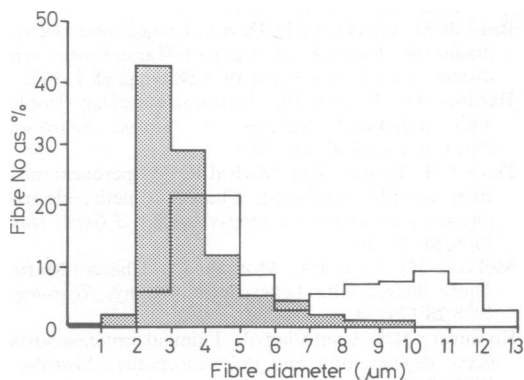
**Fig 3** The sural biopsy of Case 1. (a) Light microscopic appearances (toluidine blue stain; bar = 20  $\mu$ m), showing a marked reduction in numbers of myelinated fibres. The remaining fibres are of smaller than normal diameter, with reduced amounts of myelin, and regeneration clusters are seen. (b) An age-matched control normal sural nerve for comparison. (c) A regeneration cluster from the biopsy of Case 1, shown by electron microscopy (bar = 2  $\mu$ m).

using standard techniques. The results of nerve conduction studies are summarised in the table. In addition, in Case 1, the right peroneal nerve was stimulated at knee and ankle, producing no response.

EMG, in Case 1, using a concentric needle electrode in right biceps, showed occasional fibrillations and a reduced pattern of units up to 5 mV in amplitude. EMG in the right

extensor digitorum communis muscle showed no spontaneous activity, but a severely reduced pattern of units up to 10 mV firing at high rates. EMG was unsuccessful in Case 2. In Case 3, surface electrodes over the right biceps muscle showed high firing rates of large motor units, providing evidence of a neurogenic lesion. EMG in the clinically unaffected family member IV-11 (mother of Case 1 and 2) showed a reduced interference pattern of units up to 4 mV in right abductor pollicis brevis, compatible with carpal tunnel syndrome, but was normal in the first dorsal interosseous muscle.

The paraffin blocks of the sural nerve biopsy from Case 1, performed when he was investigated at St Bartholomew's Hospital at the time of his deterioration, were kindly made available and were examined by Dr Jean Jacobs. Teased fibre studies had not been undertaken at the time of the biopsy. The biopsy (figs 3 and 4) showed small numbers of large myelinated fibres with no evidence of active degenerative or demyelinating process. The nerve fascicles contained large numbers of Schwann cells and endoneurial collagen was greatly increased in quantity. Many small myelinated fibres were seen, both by light microscopy and electron microscopy, mostly in regeneration clusters. The few large, presumably original, myelinated fibres appeared normal. An occasional small myelinated fibre showed changes of early axonal degeneration. There was also loss of unmyelinated



**Fig 4** Fibre diameter histogram Case 1 (hatched), age matched control (open).

axons, but the degree of loss was difficult to assess because of the presence of numerous unmyelinated axonal sprouts associated with the regeneration clusters. Few macrophages were present, and no other abnormal cells or cellular inclusions were seen. Blood vessels showed some reduplication of basal laminae.

### Discussion

Clinically, it was not possible to assess whether the patients had an hereditary motor and sensory neuropathy or distal spinal muscular atrophy, that is, hereditary motor neuropathy. Harding<sup>2</sup> noted that occasionally the distinction cannot be made on clinical grounds alone. The electrophysiological evidence for sensory involvement was minimal; however, the sural nerve biopsy from Case 1 showed unequivocal involvement of sensory fibres, leading to the conclusion that these patients had neuronal type hereditary motor and sensory neuropathy. Case 1 had been receiving isoniazid for 9 months at the time of the biopsy, and isoniazid can cause an axonal neuropathy. However, pyridoxine had been taken concurrently, which would have prevented an isoniazid induced pyridoxine deficiency neuropathy.

Syndromes of hereditary motor and sensory neuropathy with involvement of other parts of the nervous system have been described, but are rare. Hereditary motor and sensory neuropathy Type V denotes associated pyramidal signs.<sup>5,6</sup> In hereditary motor and sensory neuropathy Type VI, optic atrophy is found in addition to peroneal muscular atrophy as reported by McLeod *et al.*,<sup>17</sup> and Dyck.<sup>3</sup> The combination of hereditary motor and sensory neuropathy, optic atrophy and deafness was described by Rosenberg and Chutorian<sup>8</sup> and Iwashita *et al.*<sup>9</sup> In both instances, the peripheral nerve disorder was of the neuronal rather than hypertrophic type. Mental retardation associated with hereditary motor and sensory neuropathy has also been described.<sup>10-14</sup> We are not aware of any previous reports of the combination of hereditary motor and sensory neuropathy, pyramidal signs, optic atrophy and mental retardation, although reports exist of hereditary motor and sensory neuropathy plus any one of the other features. Bell<sup>15</sup> cited and illustrated the cases of Bertolotti, who had peroneal muscular atrophy, optic atrophy and idiocy. Those cases had progressive dementia and visual failure, while the slowness of progression of the syndrome described here is striking.

There is a resemblance between the cases reported here and the Troyer-syndrome.<sup>16</sup> This autosomal recessive inherited disorder comprises spastic paraparesis, distal amyotrophy of upper and lower limbs, and mental retardation. However, dysarthria is a feature, as well as cerebellar signs and abnormal move-

ments, in some cases. Optic atrophy is not seen. In the cases described by Cross and McKusick,<sup>16</sup> the lower motor neuron component was not prominent, and patients did not have absent ankle reflexes. Spasticity was conspicuous, patients having a scissor gait and extensor plantar responses. The cases described here had no residual power in toe extensors, and the peripheral motor component predominated.

The pedigree shown here includes many cousin marriages (fig 1). The variation of expression of features of the disorder between cases is small, implying autosomal recessive transmission of a single abnormal gene or of closely linked abnormal genes.

It is of interest that autosomal recessive retinitis pigmentosa was also present in two first degree relatives of Case 3 (see fig 1). Given the high degree of consanguinity present in the pedigree, this most likely represents a separate instance of segregation of a recessive gene.

We are most grateful to Professor RW Gilliat and Dr AP Hopkins for permission to report patients who had been under their care; to Dr KR Mills for performing the electrophysiological studies; to Mr N Sarkies for ophthalmological examination and fig 2b; and to Dr JM Jacobs for studying the sural nerve biopsy and providing the photographs for fig 3 and 4.

### References

- 1 Harding AE, Thomas PK. The clinical features of hereditary motor and sensory neuropathy types I and II. *Brain* 1980;103:259-80.
- 2 Harding AE. Inherited neuronal atrophy and degeneration predominantly of lower motor neurones. In: Dyck PJ, Thomas PK, Lambert EW, Bunge R, eds. *Peripheral Neuropathy*. 2nd Ed, Vol 2. Philadelphia: WB Saunders, 1984:1537-56.
- 3 Dyck PJ. Inherited neuronal degeneration and atrophy affecting peripheral motor, sensory and autonomic neurones. *Ibid* 1984;Vol 2, 1600-55.
- 4 Brust JCM, Lovelace RE, Devi S. Clinical and electrodiagnostic features of Charcot-Marie-Tooth syndrome. *Acta Neurol Scand* 1978;58:Suppl 68:1-142.
- 5 Harding AE, Thomas PK. Peroneal muscular atrophy with pyramidal features. *J Neurol Neurosurg Psychiatry* 1984;47:168-72.
- 6 Davis CJF, Bradley WG, Madrid R. The peroneal muscular atrophy syndrome. Clinical, genetic, electrophysiological and nerve biopsy studies. *J Génét Hum* 1978;26:311-49.
- 7 McLeod JG, Low PA, Morgan JA. Charcot-Marie-Tooth disease with Leber optic atrophy. *Neurology* 1978;28:179-84.
- 8 Rosenberg RN, Chutorian A. Familial opticoacoustic nerve degeneration and polyneuropathy. *Neurology* 1967;17:827-32.
- 9 Iwashita H, Inoue N, Araki S, Kuroiwa Y. Optic atrophy, neural deafness and distal neurogenic amy-

- otrophy. *Arch Neurol* 1970;**22**:357–64.
- 10 Hoffmann J. Über einen eigenartigen Symptomencomplex, eine Combination von angeborenem Schwachsinn mit progressiver Muskelatrophie, als weiteren Beitrag zu den erblichen Nervenkrankheiten. *Dtsch Z Nervenheilkunde* 1895;**6**:150–66.
- 11 Siemerling E. Zur Lehre der spinalen neuritischen Muskelatrophie (Atrophia muscularis progressiva spinalis neuritica Bernhardt), (progressiven neurotischen oder neuralen Muskelatrophie Hoffman). *Archiv Psychiatr Nerven krankheiten (Berlin)* 1899;**31**:105–27.
- 12 Hariga J, Colle G, Guazzi GC. Sur l'extension supraspinale des lésions de l'atrophie de Charcot-Marie-Tooth. *Acta Neurol Belg* 1964;**64**:617–32.
- 13 Lundberg PO. Hereditary polyneuropathy, oligophrenia, premature menopause and acromicria. A new syndrome. *Eur Neurol* 1971;**5**:84–98.
- 14 Cowchock FS, Duckett SW, Streletz LJ, Grazini LJ, Jackson LG. X-linked motor-sensory neuropathy type II with deafness and mental retardation: a new disorder. *Am J Med Genet* 1985;**20**:307–15.
- 15 Bell J. In: Fisher RA, Penrose LS, eds. *The Treasury of Human Inheritance. Peroneal type of Progressive Muscular Atrophy*. Vol IV. Part II. Cambridge University Press, 1935:87–131.
- 16 Cross HE, McKusick VA. The Troyer syndrome. A recessive form of spastic paraplegia with distal muscle wasting. *Arch Neurol* 1967;**16**:473–85.