

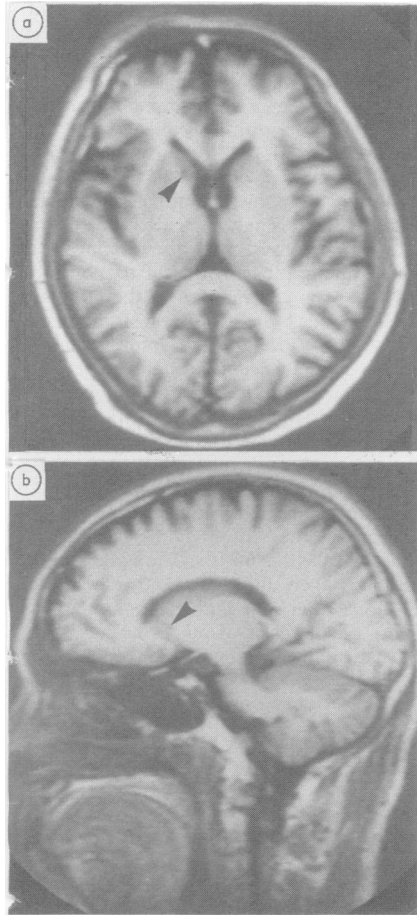Fig MRI (92 days after symptom onset) (inversion recovery technique). (a) Horizontal view [time of repetition (TR) 2080 ms, time of inversion (TI) 500 ms], (b) Left lateral sagittal view (10 mm from midline) (TR 2080 ms, TI 500 ms), showing a small low intensity area at the head of the left caudate nucleus (arrows).

ever, on the basis of experimental results in the cat, in which sensory neglect was brought about by lesions of the ventral half of the frontal lobe (including a portion of the caudate nucleus and putamen),<sup>6</sup> Goldblatt *et al*<sup>4</sup> have previously suggested that denial might be caused by damage to the basal ganglia. Among conditions conducive to the emergence of denial symptoms, the patient's personality prior to the disease has been emphasised,<sup>7</sup> and great care must be taken in considering the denial as indicative of a localised lesion. Nevertheless, recent

research on the cognitive functions of patients with Parkinson's disease have indicated that the basal ganglia may have an important role in cognition<sup>1</sup> and, from this perspective as well, the present case is of considerable interest.

MITSURU KAWAMURA  
NOBUYOSHI TAKAHASHI  
KEIZO HIRAYAMA  
Department of Neurology,  
Brain Research Institute,  
School of Medicine,  
Chiba University,  
1-8-1 Inohana,  
Chiba 280,  
Japan

#### References

- 1 Marsden CD. Function of the basal ganglia as revealed by cognitive and motor disorders in Parkinson's disease. *Can J Neurol Sci* 1984;11:129-35.
- 2 Babinski J. Contribution à l'étude des troubles mentaux dans l'hémiplégie organique cérébrale (anosognosie). *Rev Neurol (Paris)* 1914;22:845-8.
- 3 Weinstein EA, Kahn RL. *Denial of Illness*, 1st ed. Springfield, Charles C Thomas, 1955: 10 and 131.
- 4 Goldblatt D, Markesbery W, Reeves AG. Recurrent hemichorea following striatal lesions. *Arch Neurol* 1974;31:51-4.
- 5 Hécaen H, Albert ML. *Human Neuropsychology*, 1st ed. New York: J Wiley and Sons, 1978:303-7.
- 6 Reeves AG, Hagamen WD. Behavioral and EEG asymmetry following unilateral lesions of the forebrain and midbrain in cats. *Electroencephalogr Clin Neurophysiol* 1971;30:83-6.
- 7 Weinstein EA, Kahn RL. *Denial of Illness*, 1st ed. Springfield, Charles C Thomas, 1955:71-84.

Accepted 2 November 1987

#### Essential tremor cured by infarction adjacent to the thalamus

Sir: The thalamic nucleus ventralis is thought to be important in the pathophysiology of essential tremor,<sup>1</sup> and stereotactic Vim (ventralis intermedus) thalamotomy<sup>2</sup> and chemothalamectomy<sup>3</sup> have been used with some success in the treatment of essential tremor. We have seen a case in which tremor ceased unilaterally following an infarct of the internal capsule in close relation to the thalamus.

The patient presented at the age of 59 years with a one year history of tremor of

both hands. It was exacerbated by anxiety but not relieved by alcohol. His elder brother also had a tremor. He had no other complaints. There was no relevant past history. He was a smoker. On examination at that time, the only abnormality to be found was a postural tremor of the outstretched hands. There were no features of Parkinsonism. Idiopathic essential tremor was diagnosed, and he responded well to propranolol.

Six months later he presented again, with right sided weakness of acute onset. He was found to have a mild right hemiparesis with brisk tendon reflexes and upgoing plantar response. A CT scan showed a small infarct in the posterior limb of the internal capsule on the left, as it passed between the thalamus and the putamen (Fig). At review 6 months later the weakness had resolved completely. While the tremor persisted on the left, it had completely resolved on the right. Again, no features of Parkinsonism were found.

Using Marsden's classification,<sup>1,4</sup> this patient's tremor is likely to be Type II, or benign pathologic essential tremor. This is postural, affects mainly the arms, and has a frequency range of 5-7 Hz. There is often a family history, and the pathogenesis is thought to involve a central oscillator. The site of the oscillator is unknown, but is likely to be associated with the cerebello-rubro-thalamo-cortical pathways.<sup>1</sup> Surgical treatment presumably either destroys the oscillator or interrupts the circuit elsewhere.

In the present case, the lesion occurred

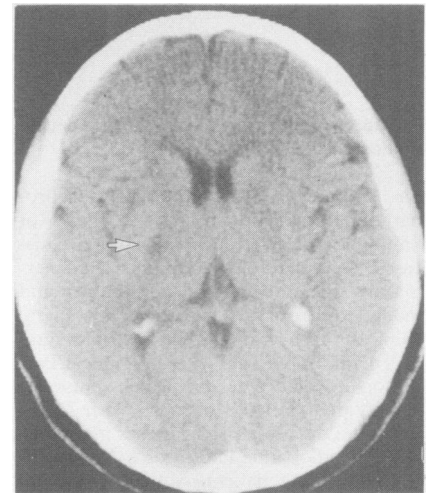


Fig CT scan showing infarction (arrowed) in the left internal capsule adjacent to the thalamus

naturally and was placed strategically; as near as can be determined from the CT scan, it was contiguous with the site of the nucleus ventralis intermedius. Clinical recovery from the effects of the infarct on its primary site, the internal capsule, was complete. It would seem, therefore, that the lesion produced in the thalamus, that is, at the edge of the infarct, was very small indeed, or was very subtle. Its effectiveness in curing the tremor suggests that the therapeutic part of surgical lesions lies in the most lateral part of the nucleus.

To our knowledge this is the only reported case of its kind. It lends further support to the effectiveness of surgically induced lesions in the management of severe ET.

RODERICK DUNCAN,  
IAN BONE,  
IAN D MELVILLE,  
*Institute of Neurological Sciences,  
Southern General Hospital,  
Glasgow G51 4TF*

#### References

- 1 Findley LJ, Koller WC. Essential tremor: a review. *Neurology* 1987;37:1194-7.
- 2 Ohye C, Hirai T, Miyazaki M, Shibasaki T, Nakajima H. Vim thalamotomy for the treatments of various kinds of tremor. *Appl Neurophysiol* 1982;45:275-80.
- 3 Cooper I. Heredofamilial tremor abolition by chemothalamectomy. *Arch Neurol* 1962; 7:129-31.
- 4 Marsden CD. Benign essential tremor is not a single entity. In: Yahr MD, ed. *Current Concepts in Parkinson's Disease* Amsterdam: Excerpta Medica, 1983:31-46.

Accepted 1 December 1987

#### Bromocriptine therapy in striatonigral degeneration

Sir: Striatonigral degeneration is a neuropathological entity within the group of "multiple system atrophy" degenerative diseases. Neuropathologically it is characterised by severe atrophy of the putamen and moderate atrophy of the substantia nigra. Clinically the patient with striatonigral degeneration presents with an atypical Parkinsonian syndrome, in which muscular rigidity predominates over the other symptoms; the disease also progresses more rapidly than idiopathic Parkinson's disease.<sup>1-3</sup>

Most of the patients with striatonigral degeneration do not respond to levodopa therapy.<sup>4,5</sup> The use of lisuride or pergolide, both dopamine receptor agonists, has not

improved patients with multiple system atrophy.<sup>6,7</sup>

We treated a striatonigral degeneration patient with levodopa and bromocriptine. As far as we know, there are no previous reports on bromocriptine therapy for striatonigral degeneration. Our patient, a 69 year old Caucasian male, complained in 1981 of weakness of his right arm and right leg. There was a history of alcohol abuse; the family history did not include any neurologic disorders. Neurological examination at that time revealed a right central facial paresis, slight weakness of the right arm and leg, symmetrical deep-tendon reflexes and no Babinski signs. He exhibited cogwheel rigidity of the right arm and a short-stepped gait. EEG and CT were normal. The diagnosis was minor stroke and a mild, atypical Parkinsonian syndrome. In addition to acetosol the patient received amantadine which did not relieve his Parkinsonian symptoms. In 1983 his illness had progressed, the patient was more rigid and moderately disabled as far as walking was concerned (Hoehn and Yahr scale 3). He was put on a therapeutic levodopa regimen in the outpatient clinic but developed severe hypotension, which made hospitalisation necessary in December 1983. Clinically the patient obviously improved on levodopa; unfortunately within about one month his condition deteriorated again (Hoehn and Yahr scale 4-5). Levodopa was discontinued and bromocriptine (Parlodel 15 mg three times daily) was prescribed. He improved markedly and was, upon discharge, in good condition (Hoehn and Yahr scale 1-2). Ten months later he experienced exacerbation of his disease with progressive hypokinesia and rigidity, without tremor. From that time onwards all medication failed and the patient deteriorated slowly. He died in October 1985 of an aspiration pneumonia, 4 years after the onset of his Parkinsonian symptoms.

Postmortem examination revealed bronchopneumonia. The external appearance of the brain was unremarkable. There was a severe atrophy of the putamen and depigmentation of the substantia nigra. Microscopic examination revealed a marked neuronal loss with dense fibrillary gliosis in the putamen; an abnormal brown pigment had been deposited in the glial cells. There was a moderate neuronal loss in the substantia nigra; no Lewy bodies were found. The pons, medulla oblongata and cerebellum, showed no significant changes. The neuropathological diagnosis was striatonigral degeneration.

The diagnosis of striatonigral degener-

ation must be considered when a patient presents with rigidity as the initial symptom; there is no tremor and the rate of deterioration is more rapid than one would expect in idiopathic Parkinson's disease. Most striatonigral degeneration patients do not respond to levodopa. In our case, levodopa had a beneficial effect which, however, lasted for only one month. The patient improved surprisingly soon after the administration of bromocriptine and remained in a good condition for a period of 10 months.

There is no explanation for the fact that levodopa fails to be effective in striatonigral degeneration. Probably as a result of degeneration of putamen and substantia nigra, the drug is not able to reach enough dopamine-receptors to improve the Parkinsonian symptoms. Bromocriptine bypasses the degenerating presynaptic nigrostriatal neurons and acts directly on the post-synaptic receptors of the remaining neurons of the striatum in the striatonigral degeneration patient. If the diagnosis striatonigral degeneration is likely and there is no response to levodopa after a period of 3 months, we advise on the basis of our experience with one patient, medication with bromocriptine.

RB VAN LEEUWEN

WVM PERQUIN

*Department of Neurology,  
Westeinde Hospital,  
Lijnbaan 32, Postbox 432,  
2501 CK The Hague,  
The Netherlands*

#### References

- 1 Takei Y, Mirra SS. Striatonigral degeneration: a form of multiple system atrophy with clinical Parkinsonism. *Progress in Neuro-pathology, Vol II*. In: Zimmerman HM, ed. New York: Grune and Stratton, 1973;2:217-51.
- 2 Kan AE. Striatonigral degeneration. *Pathology* 1978;10:45-52.
- 3 Boudin G, Guillard A, Minol J, Galle P. Dégénérescence striato-nigrique. *Rev Neurol (Paris)* 1976;132:137-56.
- 4 Izumi K, Inoue N, Shirabe T, Miyazaki T, Kuroswa Y. Failed levodopa therapy in striatonigral degeneration. *Lancet* 1971;i: 1355.
- 5 Rajput AH, Kazi KH, Rozdilsky B. Striatonigral degeneration response to levodopa therapy. *J Neurol Sci* 1972;16:331-41.
- 6 Lees AJ, Bannister R. The use of lisuride in the treatment of multiple system atrophy with autonomic failure. *J Neurol Neurosurg Psychiatry* 1981;44:347-51.
- 7 Kurlan R, Miller CH, Levy R, Macik B, Hamill R, Shoulson I. Long-term experience with pergolide therapy of advanced Parkinsonism. *Neurology* 1985;35:738-42.

Accepted 1 December 1987