

Short report

Giant axonal neuropathy: observations on a further patient

MICHAEL DONAGHY, E M BRETT,† I E C ORMEROD,‡ R H M KING, P K THOMAS

From the Department of Neurological Science, Royal Free Hospital School of Medicine, the Hospital for Sick Children† and the National Hospital for Nervous Diseases,‡ London, UK

SUMMARY A further child with giant axonal neuropathy (GAN), abnormally curly hair and consanguineous parents is described. Of the 19 patients with GAN so far reported in the literature, six, including the present patient, have resulted from consanguineous marriages. This makes autosomal recessive inheritance of GAN highly probable. Our patient also exhibited cerebellar ataxia and signs of pyramidal tract damage; magnetic resonance brain imaging demonstrated abnormalities within the cerebellar and cerebral white matter. Myelinated nerve fibre density in the sural nerve was reduced to 6790/mm² at age 8 years and had fallen to 3812/mm² 16 months later, indicating that progressive axonal loss occurs in GAN.

Giant axonal neuropathy (GAN) is a progressive neurological disorder of childhood characterised by accumulations of neurofilaments within swollen axons.¹ Both the peripheral and central nervous systems are involved, the commonest clinical manifestations consisting of peripheral neuropathy, cerebellar ataxia, intellectual loss and pyramidal tract dysfunction.²⁻⁶ Abnormally curly hair is usual and reflects abnormal intermediate filament organisation in many cell types apart from neurons.^{1,3,7-9} The disorder is progressive; abnormalities are not detected clinically until 2 to 3 years of age and slow deterioration occurs with death during adolescence.^{6,10} Peripheral nerve morphology was reportedly normal in a child aged 2 years with typical giant axonal changes only becoming evident in a second biopsy at age 8.¹¹ Reports of parental consanguinity^{2,7,11,12} and of sibling occurrence^{5,12} make autosomal recessive inheritance likely.

This report of another patient with GAN has three purposes. Firstly, our patient is another with consanguineous parents which increases the likelihood that GAN is genetically determined. Secondly, central nervous system abnormalities were demonstrated by magnetic resonance imaging (MRI). Thirdly, sequential sural nerve biopsies demonstrated

increasing giant axonal changes and progressive loss of nerve fibres. A detailed analysis of axonal cytoskeletal abnormalities in this patient is contained in a separate publication.¹³

Case report

An Iranian boy developed progressive limb weakness, ataxia and tremor starting at 5 years of age. His parents, who are first cousins, and his older sister, are normal. Birth and early development had been normal; he had walked at 12 months. Examination at 8 years of age revealed tightly curled crinkly hair, body weight at the 10th centile and height under the 3rd centile for age. The gait and limbs were ataxic, nystagmus was present, the limbs were areflexic and weak distally without muscle wasting, and joint position and vibration sensation was grossly impaired. Further neurological deterioration was evident by age 9 and distal limb muscle wasting had developed.

At age 8 years the sensory action potential amplitude was 10 μ V in the radial nerve. No sural nerve potential was detectable. Motor conduction velocity in the ulnar and median nerves was 45 and 57 m/s respectively. The evoked compound muscle action potential in abductor digiti minimi was 2.6 mV (normal > 6 mV). Visual and auditory evoked potentials were normal.

Brain MRI showed areas of abnormal signal within the white matter. In the cerebral hemispheres these abnormalities were present in relation to the frontal horns of the lateral ventricles and along the margins of the bodies of the lateral ventricles, becoming more widespread in the parietal lobe white matter. Within the brainstem, abnormalities were present in the cerebral peduncles and cerebellar hemispheres (fig 1).

Address for reprint requests: Dr Michael Donaghy, University Department of Clinical Neurology, The Radcliffe Infirmary, Oxford OX2 6HE, UK.

Received 4 December 1987 and in revised form 18 February 1988.
Accepted 11 March 1988

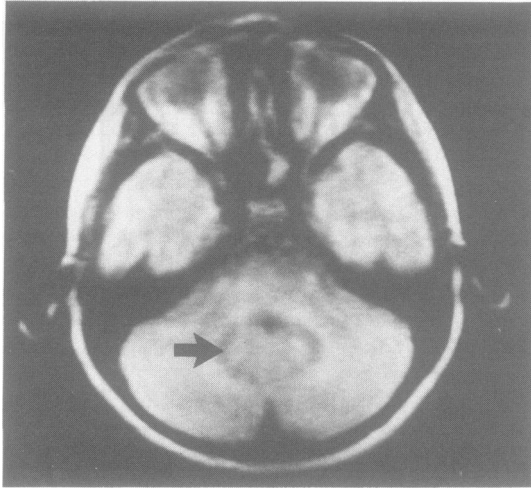


Fig 1 Axial spin echo MRI (TR 2000 ms, TE 40 ms). There are areas of abnormal signal seen symmetrically in the cerebellar hemispheres extending from the lateral aspect of the fourth ventricle curving laterally and posteriorly into the cerebellum. The abnormalities are of low signal (arrowed) with a surrounding zone of increased signal.

Morphological observations

Subtotal sural nerve biopsies on the right in June 1985 (age 8 years) and on the left in October 1986 were carried out at the ankle under local anaesthesia. The specimens were fixed in 3% glutaraldehyde, postfixed in 1% osmium tetroxide and embedded in Araldite. 1 μ m semithin sections for light microscopy were stained with thionin and acridine orange.¹⁴ Myelinated fibre density and size-frequency distributions were obtained using a Kontron Videoplan image analysis system connected to a Leitz Ultraphot.

Many myelinated fibres showed giant axonal changes, particularly in the second biopsy specimen (fig 2). All the giant axonal profiles in the first biopsy (aged 8 years) were thinly myelinated and the largest fibre diameter encountered was 19 μ m. By contrast the second biopsy (aged 9½ years) showed a population of demyelinated giant axons ranging in size from 10 to 50 μ m in addition to myelinated giant axons up to 22 μ m in diameter. The myelinated fibre size-frequency distributions of both biopsies showed loss of the 10 μ m diameter peak of the normal bimodal distribution (fig 3). Myelinated fibre density was reduced at 6790/mm² in the biopsy taken at the age of 8 years (normal 9400–11440/mm²).¹⁵ In the second biopsy 16 months later, myelinated fibre density had further fallen to 3812/mm².

Discussion

A total of 19 cases of GAN have been reported including the present patient.^{1–5 7 8 10–12 16–22} Of these, six have resulted from five consanguineous marriages^{2 7 11 12} and two affected children came from a sibship of three whose parents were unrelated.⁵

Four children with GAN have not exhibited the tightly curled hair which is generally a characteristic of the condition.^{5 12 16 17} Interestingly, of the two pairs of siblings reported with GAN, only one member of each pair has displayed the typical curled hair.^{5 12} Another Japanese patient with GAN had a sibling and numerous cousins who had tightly curled hair without neurological disease.² There can now be little doubt that childhood onset GAN is of autosomal recessive inheritance. These observations provoke the question as to whether the curly hair is determined by the same gene defect as the neuropathy, but this variability could reflect the pleiotropic effect of a single abnormal gene.

It is known that the central nervous system is affected in GAN,^{2–6 19} as it was in the present case. The MRI scan of the brain carried out in the present patient showed abnormal signal within the white matter of the cerebellum and cerebral hemispheres, and in the upper part of the brainstem. The pathological substrate for these imaging changes is unclear. Detailed necropsy study of the brain of the first patient described with GAN showed a combination of

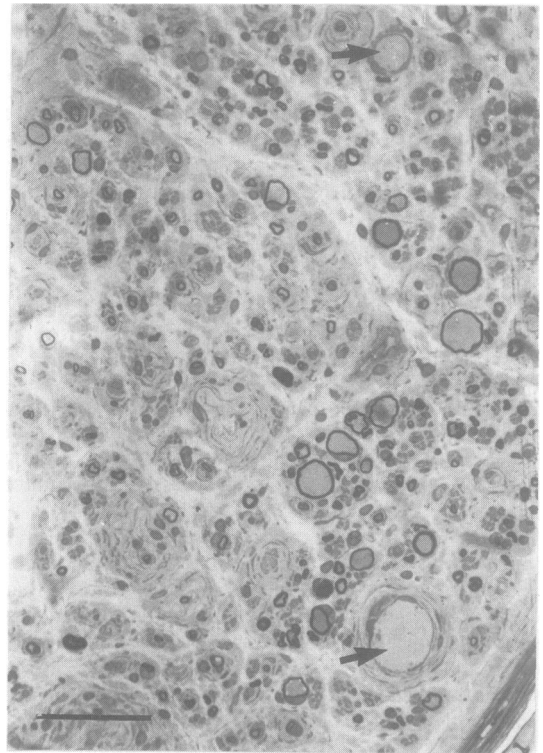


Fig 2 Transverse section of sural nerve biopsy (at age of 9½ yrs) showing frequent giant axonal swellings, some unmyelinated (arrows), and a reduced density of myelinated fibres (LM, thionin and acridine orange; bar = 50 μ m).

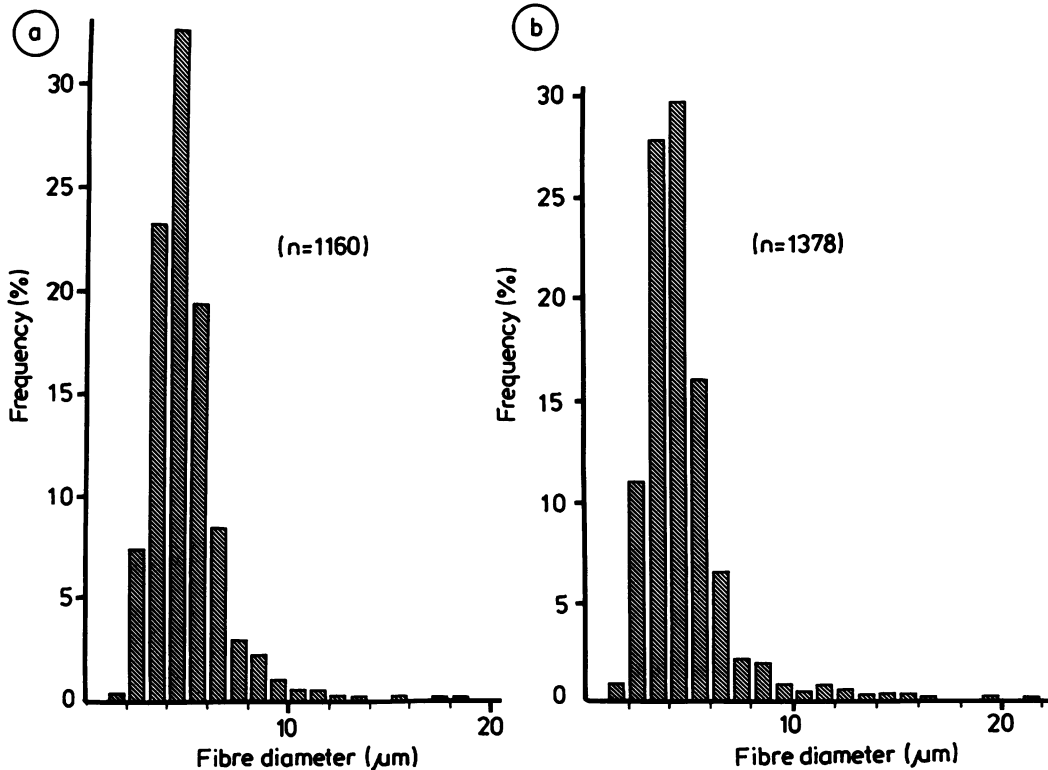


Fig 3 Size-frequency distributions of the myelinated fibres in the sural nerve aged 8 yrs (a) ($n = 1160$) and age 9½ yrs (b) ($n = 1378$). Occasional large diameter fibres, representing giant axonal profiles, are seen particularly in the histogram of the second biopsy. The normal bimodal distribution of fibre sizes is absent with loss of the 10 µm diameter peak and a shift of the normal 2-3 µm peak to 4-5 µm.

demyelination, giant axonal change and spheroid formation, astrocytic gliosis and, particularly common in the brainstem and cerebellar white matter, copious Rosenthal fibres.⁶

Slow progression of peripheral neuropathy in GAN is well recognised clinically and electrophysiologically.^{10 21} In the present patient, the sural nerve myelinated fibre density decreased over a 16 month period. This suggests that clinical progression is due to nerve fibre degeneration rather than to the development of conduction failure in nerve fibres distended with neurofilaments, with accompanying secondary demyelination. Like Igisu *et al*,² we found that it was predominantly the larger diameter myelinated nerve fibre peak at 10 µm which had been lost from the normal bimodal fibre size-frequency distribution. This does not necessarily mean that the larger diameter fibres are more vulnerable in GAN. Our detailed electron microscopic studies of this present patient's sural nerve biopsy show that many axons

appear to be of relatively small calibre, are packed with microtubules, and contain no neurofilaments.¹³ In such axons it is likely that neurofilaments had clumped focally within the axon and that other portions of the axon, lacking a neurofilamentous cytoskeleton, had become reduced in calibre; neurofilaments, the most abundant structural component of axons, are the main determinant of their diameter.²³ This mechanism would effectively shift the fibre diameter-frequency distribution towards smaller diameters. It would be partially counteracted by the presence of distended smaller diameter axon profiles containing accumulations of neurofilaments.

We are grateful to Miss J Workman and Mr J Muddle for technical assistance, to Mrs K Price for typing the manuscript, to the Multiple Sclerosis Society for the magnetic resonance scanner, and the Friedrich's Ataxia Group for financial support.

References

- 1 Asbury AK, Gale MK, Cox SC, Baringer JR, Berg B. Giant axonal neuropathy. A unique case with segmental neurofilamentous masses. *Acta Neuropathol (Berl)* 1972; **20**:237-47.
- 2 Igisu H, Ohta M, Tabira T, Hosokawa S, Goto I, Kuroiwa Y. Giant axonal neuropathy. A clinical entity affecting the central as well as the peripheral nervous system. *Neurology* 1975; **25**:717-22.
- 3 Peiffer J, Schlote W, Bischoff A, Bolthausen E, Müller G. Generalised giant axonal neuropathy. A filament forming disease of neuronal, endothelial, glial and Schwann cells in a patient without kinky hair. *Acta Neuropathol (Berl)* 1977; **40**:213-8.
- 4 Mizuno Y, Otsuka S, Takano Y, *et al.* Giant axonal neuropathy. Combined central and peripheral nervous system disease. *Arch Neurol (Chic)* 1979; **36**:107-8.
- 5 Jones MZ, Nigro MA, Barre PS. Familial 'giant axonal neuropathy'. *J Neuropathol Exp Neurol* 1979; **38**:324.
- 6 Kretzschmar HA, Berg BO, Davis RL. Giant axonal neuropathy. A neuropathological study. *Acta Neuropathol (Berl)* 1987; **73**:138-44.
- 7 Prineas JW, Ouvrier RA, Wright RG, Walsh JC, McLeod JG. Giant axonal neuropathy—A generalised disorder of cytoplasmic microfilament formation. *J Neuropathol Exp Neurol* 1976; **35**:458-70.
- 8 Kock T, Schultz P, Williams R, Lampert P. Giant axonal neuropathy: A childhood disorder of microfilaments. *Ann Neurol* 1977; **1**:438-51.
- 9 Pena SDJ. Giant axonal neuropathy: Intermediate filament aggregates in cultured skin fibroblasts. *Neurology* 1981; **31**:1470-3.
- 10 Dooley JM, Oshima Y, Becker LE, Murphy EG. Clinical progression of giant-axonal neuropathy over a 12 year period. *Can J Neurol Sci* 1981; **8**:321-3.
- 11 Gambarelli D, Hassoun J, Pellissier JF, Livet MO, Pinsard N, Toga M. Giant axonal neuropathy. Involvement of peripheral nerve, myenteric plexus and extraneuronal area. *Acta Neuropathol (Berl)* 1977; **39**:261-9.
- 12 Takebe Y, Koide N, Takahashi G. Giant axonal neuropathy. report of two siblings with endocrinological and histological studies. *Neuropediatrics* 1981; **12**:392-404.
- 13 Donaghy M, King RHM, Thomas PK, Workman JM. Abnormalities of the axonal cytoskeleton in giant axonal neuropathy. *J Neurocytol* 1988;(in press).
- 14 Sievers J. Basic two-dye stains for epoxy-embedded 0.3-1 μ sections. *Stain Tech* 1971; **46**:195-9.
- 15 Jacobs J, Love S. Qualitative and quantitative morphology of human sural nerve at different ages. *Brain* 1985; **108**:897-924.
- 16 Bolthausen E, Bischoff A, Isler W. Giant axonal neuropathy. report of a case with normal hair. *J Neurol Sci* 1977; **31**:269-78.
- 17 Jędrzejowska H, Drac H. Infantile chronic peripheral neuropathy with giant axons. Report of a case. *Acta Neuropathol (Berl)* 1977; **37**:213-7.
- 18 Larbrisseau A, Jasmin G, Hausser C, Brochu P, Geoffrey G. Generalised giant axonal neuropathy—A case with features of Fazio-Londe disease. *Neuropädiatrie* 1979; **10**:76-86.
- 19 Dubeau F, Michaud J, Lamarre L, Larbrisseau A. Giant axonal neuropathy. A complete autopsy study. *J Neuropathol Exp Neurol* 1985; **44**:355.
- 20 Carpenter S, Karpati G, Andermann F, Gold R. Giant axonal neuropathy. A clinically and morphologically distinct neurological disease. *Arch Neurol (Chic)* 1974; **31**:312-6.
- 21 Watters G, Karpati G, Carpenter S, Humphreys P, Andermann F. Giant axonal neuropathy (GAN)—A disorder of the central and peripheral nervous system. *Can J Neurol Sci* 1978; **5**:340-1.
- 22 Ionasescu V, Searby CH, Rubenstein P, Sandra A, Cancilla P, Robillard J. Giant axonal neuropathy: normal protein composition of neurofilaments. *J Neurol Neurosurg Psychiatry* 1983; **46**:551-4.
- 23 Hoffman PN, Griffin JW, Price DL. Control of axonal caliber by neurofilament transport. *J Cell Biol* 1984; **99**:705-14.