

cular lesion was documented by CT scan.<sup>3-5</sup> We report a patient with reversible hemiballism related to a CT scan documented lacunar infarct in the lateral part of the contralateral lenticular nucleus.

A previously healthy 57 year old man was admitted 12 hours after the sudden onset of uncontrollable, rapid and large amplitude movements of the right limbs. Proximal joints were mainly affected by stereotyped abduction-inward rotation movements at the shoulder and flexion-extension movements at the hip. Neurological examination revealed no other abnormality. The blood pressure was 170/110 mm Hg, equal in both arms. The heart was normal at clinical and electrical examination. Cervical arteries were normal at Doppler and echotomography. Treatment with haloperidol, 2 mg three times a day, was started on admission. The ballistic movements disappeared within 6 hours. The only residual anomaly was a slight muscular hypotonia of the right limbs. Three days after admission, haloperidol was discontinued without recurrence of the dyskinesia. Two unenhanced CT scans (6 mm thick slices) were performed on the 5th and 25th days after clinical onset. A small hypodense area in the lateral part of the left lenticular nucleus was suspected on the first CT scan. This hypodense area was larger and better defined on the second CT scan (fig). The patient was discharged on antihypertensive therapy and, at one year follow-up, he had no further symptoms.

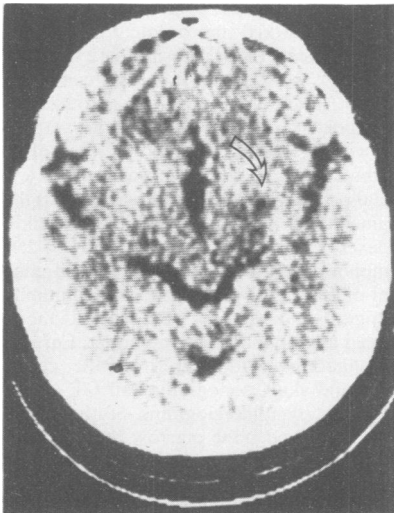


Fig Unenhanced CT scan (performed 25 days after onset): low density area in the lateral part of the left lenticular nucleus (arrow).

In this patient with hemiballism, CT scan disclosed a small low-density area in the lateral part of the contralateral lenticular nucleus. The increase in size of the hypodensity at two successive examinations was consistent with a lacunar infarct of the same date as the clinical symptoms. Review of the pathological data in cases of ischaemic hemichorea-hemiballism from the literature reveals that most of them were related to lacunar infarcts in the subthalamic nucleus,<sup>6</sup> in its afferent and/or efferent pathways,<sup>7</sup> in the striatum<sup>2</sup> or in the thalamus.<sup>6</sup> Therefore, hemichorea-hemiballism has been included in the group of clinical syndromes most commonly caused by lacunar infarcts.<sup>8</sup> In our experience, most patients with this syndrome have normal CT scans. However, the CT scan underestimates the extent of vascular lesions, at least as judged by magnetic resonance imaging, which will probably detect more often the lesion responsible for this syndrome.

Lacunar infarcts result from occlusion of perforating branches of the large cerebral arteries. The cause of the occlusion is most frequently lipohyalinosis or microatheroma, involving the walls of the perforating arteries,<sup>8</sup> two arteriopathies encountered in long-standing hypertension. However, hemichorea-hemiballism caused by embolisation from the heart<sup>6</sup> or by atheromatous disease of internal carotid or posterior cerebral arteries have been reported.<sup>7</sup> Transient hemichorea-hemiballism, as the main or sole manifestation of TIAs, has also been described in relation to basilar<sup>9</sup> or internal carotid<sup>10</sup> atheromatous disease. Consequently, assessment of a patient with this syndrome should be the same as for any other stroke, and should include requisite investigations to specify the mechanism of the causal vascular injury. Spontaneous outcome of hemiballism is unpredictable; dyskinesias may last days, months or even years.<sup>16</sup> Neuroleptic therapy usually induces a dramatic improvement in dyskinesias<sup>11</sup> but spontaneous recovery can be masked by this treatment. Therefore, neuroleptic therapy should be discontinued rapidly to detect whether or not recovery of dyskinesias have occurred.

JEAN-LOUIS MAS\*

MICHEL LAUNAY†

CHRISTIAN DEROUESNE\*

Clinique des Maladies du  
Système Nerveux\*

Service de Neuroradiologie,†

Hôpital de la Salpêtrière,

47 Bld de l'Hôpital,

75651 Paris, Cedex 13,

France

## References

- 1 Meyers R. Ballismus. In: Vinken PJ, Bruyn CW, Klawans HL, eds. *Handbook of Clinical Neurology*. Amsterdam: North-Holland Publishing Co, 1968;6:476-90.
- 2 Schwarz GA, Barrows LJ. Hemiballism without involvement of Luys Body. *Arch Neurol* 1960;2:420-34.
- 3 Melamed E, Korn-Lubetzki I, Reches A, Siew F. Hemiballismus: detection of focal hemorrhage in subthalamic nucleus by CT scan. *Ann Neurol* 1978;4:582.
- 4 Kase CS, Maulsby GO, De Juan E, Mohr JP. Hemichorea-hemiballism and lacunar infarction in the basal ganglia. *Neurology* 1981;31:452-5.
- 5 Saris S. Chorea caused by caudate infarction. *Arch Neurol* 1983;40:590-1.
- 6 Hyland HH, Forman DM. Prognosis in hemiballismus. *Neurology* 1957;7:381-91.
- 7 Martin JP. Hemichorea (hemiballismus) without lesions in the corpus luyisii. *Brain* 1957;80:1-12.
- 8 Fisher CM. Lacunar strokes and infarcts: a review. *Neurology* 1982;32:871-6.
- 9 Ganshirt H, Reuther R, Swiridoff F. Transitorischer hemiballismus als symptom der vertebro-basilären insuffizienz. *Nervenarzt* 1978;49:730-4.
- 10 Margolin DI, Marsden CD. Episodic dyskinesia and transient cerebral ischemia. *Neurology* 1982;32:1379-80.
- 11 Klawans HL, Moses H, Nausieda PA, Bergen D, Weiner WJ. Treatment and Prognosis of hemiballismus. *N Engl J Med* 1976;295:1348-50.

## Parkinson's disease in twins

Sir: Debate on the inheritance of Parkinson's disease continues. It is not uncommon for a patient to say that another family member has been similarly affected. However, Parkinson's disease is a common illness, particularly in those over the age of 60 years, and benign essential tremor which is often mis-interpreted as Parkinson's disease, is even commoner. Duvoisin *et al*<sup>1</sup> personally examined a large number of relatives of both patients and of their spouses, but found approximately equal numbers of secondary cases of Parkinson's disease in both groups. This evidence against any major genetic contribution to the aetiology of the disease was given strong support by a subsequent study of Parkinson's disease in twins.<sup>2</sup> When twins, one of whom had definite Parkinson's disease, were examined, only one of the 43 pairs of monozygotic twins was definitely concordant for Parkinson's disease, and none of 19 dizygotic pairs was concordant. Despite this evidence, however, others<sup>3</sup> have subsequently continued to suggest that inheritance plays a part in Parkinson's disease, at least in some fami-

lies. Accordingly, it is important to report further data on Parkinson's disease in twins.

An advertisement was placed in the newsletter of the Parkinson's Disease Society of the United Kingdom, requesting information on patients with Parkinson's disease who had a twin. Twenty-two twin pairs were identified. The diagnosis of Parkinson's disease in the index case of each twin pair was verified by communication with their general practitioner or neurologist. Criteria for accepting the diagnosis were the presence of typical clinical signs (tremor, rigidity and akinesia), the absence of features that might suggest an alternative diagnosis (severe dementia, disordered eye movements, postural hypotension or incontinence), and a definite response to levodopa treatment. Zygosity was assessed by asking the twins and their relatives whether they looked alike or dissimilar. The affected twin was asked whether their co-twin had any suggestion of a similar illness. If this was thought to be the case, the co-twin was approached by letter to describe the clinical features of their illness, and their physician was contacted for further information.

Of the 22 pairs of twins, one of whom was judged to have definite Parkinson's disease, 11 pairs were thought to be identical and 11 pairs non-identical. Amongst the 11 identical twin-pairs (mean duration of illness 9.3 years), only one affected twin reported that her co-twin had Parkinson's disease. The index case, a 76 year old lady, had had typical Parkinson's disease with tremor for the previous 5 years. Her identical sister also had Parkinson's disease, with tremor, for 3 years. Among the 11 non-identical twin-pairs (mean duration of illness 8.0 years), one affected twin reported that her co-twin had Parkinson's disease. A 60 year old female who had Parkinson's disease for the previous 18 years had a sister similarly affected for the previous 7 years. The remaining 10 identical twin pairs and 10 non-identical twin-pairs said that their co-twins were free of any symptoms or signs of Parkinson's disease.

There has not been the opportunity to examine these twin-pairs personally, so the results presented here must be tentative. However, amongst twins with Parkinson's disease, the reported prevalence of this illness in the co-twin was no greater amongst identical twin-pairs than amongst non-identical twin-pairs. These data may be added to those of Ward *et al.*<sup>2</sup> Amongst their 43 monozygotic twin-pairs, only one co-twin had definite Parkinson's disease; in a second twin-pair, the co-twin had possible Parkinson's disease on the basis of a history of hesitancy in speech and the finding of

variable cogwheel rigidity of one upper limb with a fine action tremor on examination. Thus, taken together, the total data suggest that amongst 54 identical twin-pairs, two (3.7%) or at most three (5.6%) were concordant for Parkinson's disease. In the study of Ward *et al.*, none of 19 dizygotic twin-pairs was definitely concordant for Parkinson's disease; in one twin-pair, the co-twin had severe dementia which had pre-dated the onset of Parkinsonism by 5 years, and the index case also was demented. Adding the data from the present investigation, amongst 30 non-identical twin-pairs, only one (3.3%), or at most two (6.7%) were concordant for Parkinson's disease.

It does not appear that the chances of a twin with definite Parkinson's disease having a similarly affected co-twin is any different amongst identical twin-pairs compared with non-identical twin-pairs. Similar findings have emerged from a study of Parkinson's disease twin-pairs in Finland (Martilla, personal communication). These data confirm and add to the conclusion of Ward *et al.*<sup>2</sup> "that the major factors in the aetiology of Parkinson's disease are non-genetic".

CD MARSDEN

*University Department of Neurology,  
and Parkinson's Disease Society  
Research Centre, Institute of  
Psychiatry and King's College  
Hospital Medical School,  
de Crespigny Park,  
London SE5 8AF, UK.*

#### References

- 1 Duvoisin RC, Gearing FR, Schweizer MD, Yahr MD. A family study of Parkinsonism. In: Barbeau A, Brunetti JR, eds. *Progress in Neurogenetics*. Amsterdam: Excerpta Medica, 1969:492-6.
- 2 Ward CD, Duvoisin RC, Ince SE, *et al.* Parkinson's disease in 65 pairs of twin and in a set of quadruplets. *Neurology* 1983;33:815-24.
- 3 Barbeau A, Roy M. Familial subsets in idiopathic Parkinson's disease. *Can J Neurol Sci* 1984;11:144-50.

Accepted 4 April 1986

#### **Lymphomatous meningitis appearing as Garin-Bujadoux-Bannwarth meningopolyneuritis**

Sir: We report a patient who developed lymphomatous meningitis without evidence of

lymphoma outside the nervous system. The initial clinical and cerebrospinal fluid (CSF) findings and elevated antibody titres against the Ixodes-ricinus-borrelia antigen led initially to the incorrect diagnosis of Garin-Bujadoux-Bannwarth meningopolyneuritis.

The 49 year old female patient was admitted in December 1984 with progressive lower back pain and radicular pain in the right S1 segment. One month later she developed weakness in both legs and occasional incontinence of urine. The patient had had no serious medical complaints prior to this illness, and in particular no symptoms of *Borrelia* infection. Examination revealed a slight weakness of the legs (more pronounced on the left side); the left patellar reflex was hyperactive and the right ankle reflex was absent. This first examination gave otherwise unremarkable results, but after 10 days the patient developed a left facial paresis. EEG, CCT, myelography and chemical blood analyses gave normal results. CSF examination showed 70 WBC/mm<sup>3</sup> (prevalently lymphocytes and few monocytes in Pappenheim staining), a blood brain barrier dysfunction with total protein of 116 mg/dl and intrathecal immunoreactivity with oligoclonal bands in isoelectric focusing. The titre of antibodies against Ixodes-ricinus-borrelia antigen was elevated to 360 units in serum (normal less than 100 units), and was negative in CSF. The patient was treated with penicillin G (20 mega units/day for 10 days) and prednisone (initially 80 mg/day, dose reduced with time, for 3 weeks) because of radicular pain. She showed a marked improvement in her radicular pain and facial paresis after 2 weeks of therapy. At this time CSF contained 43 WBC/mm<sup>3</sup> and a total protein of 61 mg/dl.

Two weeks after the end of therapy a relapse involving the recurrence of the left facial paresis and a hypaesthesia in the right segments C8 and S1 occurred. Both ankle reflexes were absent. Now CSF showed 254 lymphocytes/mm<sup>3</sup> and a total protein content of 136 mg/dl. Cytochemical and immunological analysis of CSF cells demonstrated a lymphoblastic lymphoma. Further investigations (radiographs of the chest, spine and skull, sonograms and CT of the abdomen, lymphangiograms of the lower extremities and bone marrow biopsy) gave no sign of lymphomatous infiltration outside the nervous system. However CCT now revealed a solid tumour in the posterior part of the corpus callosum with a diameter of 1.5 cm.

Neurological complications of non-Hodgkin's lymphomas resulting from metastatic invasion of the nervous system usually