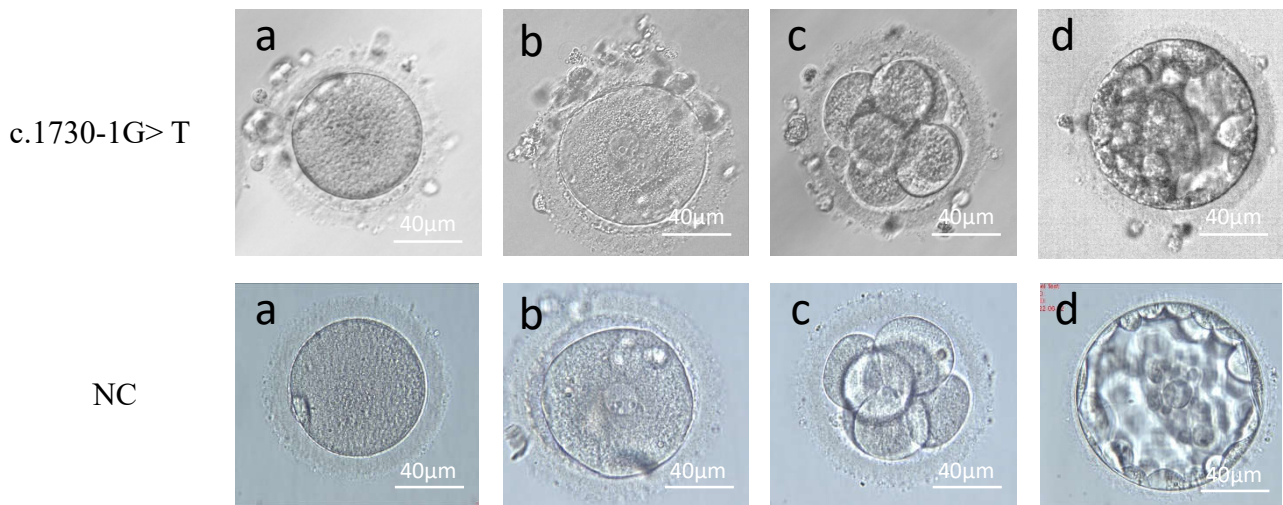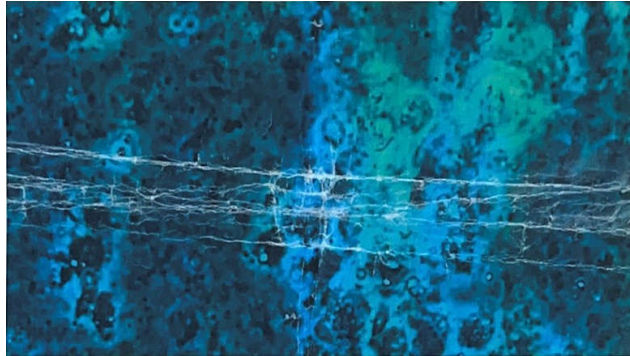


Supplement Figure I. Diagram of blastocyst formation.

Typical morphology of the ovum and implanted embryo from F1 II-1 and her husband. High-quality blastocyst formed after standard embryo culture. a. ovum; b. 2 pronuclear fertilization; c. 8-cell stage embryo; d. blastocyst stage embryo.

Typical morphology of the ovum and implanted embryo from normal control. a. ovum; b. 2 pronuclear fertilization; c. 8-cell stage embryo; d. blastocyst stage embryo.



Supplement Figure II. The report of testicular biopsy from F1 II-2. Microscopically, there were occasional spermatogenic cells and no mature spermatozoa.