

## DIATOMACEOUS EARTH SILICOSIS

BY

ENRICO C. VIGLIANI and GIACOMO MOTTURA

*From the Clinic for Occupational Diseases, University of Milan, and from the Pathological Institute, University of Pisa*

(RECEIVED FOR PUBLICATION, MARCH 31, 1948)

Diatomaceous earth and tripoli are hydrated amorphous silica minerals of organic origin, which are generally considered to be a variety of opal. The diatomaceous earth or diatomite (German: Kieselgur; Italian: farina fossile), are found in the lake deposits of innumerable diatom shells: it forms a very porous mass, sometimes loose and floury, sometimes compact and claylike, always very light—white, grey, or yellowish. Tripoli on the other hand is a marine sediment mainly composed of skeletons of radiolarii: it is more compact and generally light, often containing well-preserved fossils of fish and shellfish.

After quarrying, drying, and pulverizing, diatomaceous earth is marketed for a great variety of industrial purposes, including dynamite, refractory bricks, and filters for drinking water or wine or syrups; it is also used as an insulating material. Tripoli is less used but is especially valuable for polishing metals, precious stones, and the like.

Diatomite is chiefly formed of amorphous hydrated silica ( $\text{SiO}_2 \cdot n\text{H}_2\text{O}$ ) and in small part (2 to 6 per cent.) of basic oxides.

### Silicosis-Producing Power of Diatomaceous Earth

The great surface of the diatomaceous earth particles, and the greater water solubility of the hydrated amorphous silica of which they are formed, in comparison with quartz, are considered important silicosis-producing factors by those who hold the disease to be caused by the solution of silicon dioxide in organic fluids. Beger (1934) thinks that the speed and severity of the silicosis seen in abrasive soap factories depend on the solubility of the diatomaceous earth which is sometimes used for abrasive purposes.

Experimentally diatomite has shown a high silicosis-producing power. Podwysozki (1910) produced true granulomatous growths by introducing diatomite dust subcutaneously into animals. By

diatomite inhalation in rabbits Beintker (1935) and Siegmund (1934) obtained a formation of nodules very like those seen in human silicosis. In order to determine whether or not tripoli is capable of producing silicosis, McCord (1936) introduced 0.1 g. of tripoli in 2 c.cm. of physiologic saline into the peritoneal cavities of male guinea-pigs. At the end of thirty days all tripoli-injected animals were killed: in every instance extensive and characteristic proliferation was established. The nodules produced were typical of those for quartz silica and in all respects permitted the interpretation that the action of tripoli is the stimulation of a proliferative response.

Proliferative responses; cellular in type, were set up by Solowiev and Pinus (1928), by Policard (1936, 1940), (whose albino rats, after inhaling pure diatomite dust, showed an extraordinary monocytic reaction in the lung alveoli, without any evidence of fibrosis and widely differing from the type of reaction set up by quartz), and quite recently by Duvoir, Derobert, and Journet (1946).

In human pathology a case of diatomite silicosis was recorded in 1932 by Adler-Herzmark and Selinger (1932) in a worker who had been employed for eight years grinding and packing diatomite: the fibrosis, not exceeding in extent the palm of a hand, was slightly reticular in type and was limited to the lower parts of the lung near the hila. In the same year Legge and Rosencrantz (1932) published an investigation, unfortunately almost forgotten in the silicosis literature, on 118 workers of a diatomite quarry in the region of Santa Barbara, California, exposed to the inhalation of large quantities of dust. Eighty-one cases with radiographic abnormalities were discovered, including sixty with early stages of silicosis, fifteen with fairly advanced, and six with advanced stages. Eighty-six workers had clubbed fingers, but only eight showed generally impaired conditions: light and moderately advanced

silicosis were to be seen after one to two years' work ; in one case the silicosis was severe after less than five years' work.

Notwithstanding the observations of Legge and Rosencrantz and the ready demonstration of experimental silicosis from diatomaceous earth and from tripoli, these two substances are commonly held to be of little or no importance in producing silicosis in man. McCord (1936) points out, that in compensation cases in which silicosis has been falsely attributed to tripoli, qualified industrial hygienists have denied that tripoli may be a source of that disease. The chief basis for this attitude lies in the absence of evidence of characteristic silicosis in the skiagrams of workers long employed in industries utilizing diatomite or tripoli. Gardner's (1940) statement that amorphous silica is less silicosis-producing than crystalline silica contributed largely to the widespread opinion that diatomite dust is not very dangerous to human beings.

As a matter of fact, Gudjonsson (1934) failed to find silicosis in workers who for many years had quarried and pulverized diatomite, in spite of high dust production. In three workers who worked with diatomaceous earth Nuck (1934) failed to find radiographic evidence of silicosis ; also Beintker's researches on numerous workers extracting and working up diatomite in the German districts of Lüneburg and Hannover were negative. Later Nordmann (1943) reported that in the same district of Lüneburg Nuck discovered a silicosis-like pneumoconiosis among Kieselgur workers ; Nordmann himself published a set of six autopsy findings, which will be mentioned later : in these cases, however, the action of a considerable amount of quartz cannot be excluded. Middleton (1936) on *x*-ray examination of many workers who had been exposed for ten years to diatomite dust, found only two cases of slight fibrosis.

Quite recently Martin and others (1947) examined thirty-two workers exposed for many years to heavy concentrations of diatomite dust : only three showed an *x*-ray appearance of mild, initial pneumoconiosis of the asbestosis type, and of these only one had functional impairment : they concluded that, although a diatomite dust pneumoconiosis undoubtedly exists, it is much milder both radiographically and clinically than would have been expected from the high content of free silica in the diatomite.

Some radiographs of cases of pneumoconiosis produced by Fuller's earth (a mineral substance of indefinite composition, containing amorphous silica ( $\text{SiO}_2 \cdot n\text{H}_2\text{O}$ ) and thus somewhat resembling diatomite) were presented by Middleton at the Silicosis Conference in Geneva in 1938. One patient, with

thirty-five years' exposure to Fuller's earth dust, showed fine punctate nodulation with some aggregation of shadows ; a second, with thirty-nine years' exposure, showed shadows suggesting nodulation with a linear arrangement ; yet Policard (1940) inclined to explain the radiographic findings by the presence in the Fuller's earth of heavy metallic compounds arresting the *x* rays and producing shadows interpreted as fibrosis. Two other cases of pneumoconiosis from Fuller's earth are reported by Campbell (1940) : one patient died at the age of 56 after having worked continuously on the mill from 1908 to 1919. He had suffered from cough and dyspnoea during the last few years and was incapacitated eighteen months before his death. An autopsy was made by Dr. S. R. Gloyne. In the lower parts of the lungs there was extensive visible and palpable dust fibrosis, in the main of a cellular-reticular type and without the dense acellular whirls and nodules commonly found in fully developed silicosis. There were also dark masses in the upper parts of the lungs, but these were not examined microscopically.

#### Technical Data

We have been able to observe several cases of advanced silicosis caused by inhalation of diatomite dust among workers employed in the manufacture of filter candles. The two factories considered in the present work will be called respectively IG and ZA.

A brief description of the materials used and of the working procedure is given below.

Diatomite comes ready ground from the quarries of Monte Amiata, Tuscany. Its chemical composition is : silica ( $\text{SiO}_2$ ) 82% ; water 12.4% ; Alumina and iron oxide 4.2% ; chalk 0.55% ; magnesia 0.45%.

Filter candles are manufactured as follows. Diatomaceous earth is mixed with small quantities of charcoal and pure calcined magnesite, according to the required properties of the candles, generally in the following proportion : 25 kg. diatomite, 5 kg. charcoal, and 2 kg. magnesite. The mixture is thoroughly ground and parallelepipeds measuring  $35 \times 10 \times 10$  cm. are formed with the addition of water. They are dried in the open air and then turned to cylinders by hand, and calcined at  $1250^\circ \text{C}$ . After ignition, during which charcoal is burned out, the cylinders have a white or slight yellowish appearance, and are light, talc-like, very finely spongy, and easily broken. This first working process is carried out in IG factory only ; ZA factory receives the cylinders already calcined from the IG plant. In the second stage of the process, which is carried on in both factories in a department called "turning of the candles," the cylinders or candles are machine-turned until they reach the required diameter, which is different for the various types of candle (from 2 to 6 cm.). The candles are then perforated along their whole length with a boring

machine; the diameter of the hole is about equal to half the diameter of the candle, and it terminates from  $\frac{1}{2}$  to 3 cm. from one end. The candles are then fitted on a metallic support, and thereafter are mechanically limed and polished with emery paper, tested, sorted, dusted, and smoothed by hand, and finally sent to another department, where silvering is performed. Each candle is dropped into an aqueous solution of silver nitrate which penetrates into it and is then reduced to metallic silver by special treatment.

Turning, boring, liming, and finishing are always performed by dry methods and thus raise much dust: the very fine and light dust has a great tendency to float in the air and to pervade the whole department. Therefore not only the turners and finishers, but also the testers, the sorters, and the fitters—whose work is not in itself dust-producing—are exposed to the inhalation of dust.

### The Present Investigation

Workers in these two factories making filter-candles (basically similar to Chamberland and Berkefeld candles), who had worked in the turning department from more than one year, were x-rayed and examined in 1944, and from then on once a year. The more serious cases were admitted to the Clinic for Occupational Diseases of the University of Milan.

The turning department of IG plant is small, badly ventilated, extremely dusty, and lacking in fans. In 1944 there were in it five workers who had been employed for more than one year. Of these, two had normal radiographs, two had advanced silicosis, and one had advanced silicosis with open tuberculosis.

The turning department of ZA factory is large and modern and has many windows. Since 1944, when the first cases of silicosis were detected, the lathes and drills have been equipped with powerful exhaust, so that dustiness has been largely reduced. In 1945 dust counts carried out with the thermal precipitator gave the following results: near the grinding wheel without exhaust 500 p.p. c.cm.; near the lathe 450 p.p. c.cm.; in the middle of the department 400 p.p. c.cm. (dust counts performed with magnification of 200). The size of the dust particles ranged between 0.5 and 2  $\mu$ .

In 1944 in this department there were fifteen workers who had been employed for over one year. Five were normal, and ten showed silicotic lung changes, two reticular fibrosis, four reticular fibrosis with nodulation-like appearance, and four conglomerate silicosis.

In all, out of twenty workers radiographed in the two factories, thirteen were silicotic, of whom seven were in an advanced stage and one had open tuberculosis. From 1944 up to date, two workers have died, one of silico-tuberculosis and the other

of silicosis: several became incapacitated and were obliged to leave work; six were pensioned by the National Accident Insurance Institute.

### CASE REPORTS

**Case 1.**—A man aged 35, who worked for ten years as a candle turner in IG factory, has suffered for two years from shortness of breath on going upstairs and bicycling. He still continues to work, though he has dullness in the upper fields of the lungs, with high-pitched breath sounds, an erythrocyte sedimentation rate (Westergren) of 2 mm. in the first hour, and a Katz index of 2.5. Vital capacity is 2,500 c.cm., and breath-holding time 25 secs. The sputum contains no tubercle bacilli. The radiograph shows reticular-nodular fibrosis with large coalescence in the upper fields, especially in the infraclavicular zone and in the right middle field; the left lung root is raised; the lower zones of the lung fields show emphysema (fig. 1). The diagnosis is of nodular-interstitial coalescent silicosis.

**Case 2.**—A man aged 36, a raw candle turner for five years (not a dust-producing procedure), and a calcined candle turner for five years, in IG plant, has for one year suffered from dyspnoea on slight exertion, dry cough, pains in the chest, occasionally slight fever, and sometimes night sweats and loss of weight and appetite. He is of wasted physique (height 165 cm., weight 46 kg.). There is a dull percussion note over the upper lung zones, with sharp, almost tubular breathing. The blood sedimentation rate is 2 mm. in the first hour, the Katz index 2. The sputum contains no tubercle bacilli. The vital capacity is 3,000 c.cm., the breath-holding time 27 secs. The temperature is normal. The radiograph shows very intense reticular-micronodular fibrosis, especially in both subclavicular zones, where a tendency to conglomeration is seen. The left lung root is displaced toward the apex; both lower lung zones are emphysematous (fig. 2). The diagnosis is of micronodular silicosis with conglomeration in the upper fields.

**Case 3.**—A man aged 31, a candle turner in IG plant for seven years, up to 1942 went in for many sports, such as skiing, swimming, and climbing. In March, 1944, the temperature rose to 38° C., and he developed productive cough, marked dyspnoea on exertion, loss of weight, tiredness, and loss of appetite. Clinical findings in June, 1944, showed him to be of wasted physique with a pale, toxic appearance. There was dullness of the whole of the left lung, with bronchial breathing and numerous crackling rales in the scapulo-vertebral zone. The radiograph showed intense irregular fibrosis of the right lung, with reticulation, nodules and fluffy patches in the upper zones. The left lung showed nearly total opacity, except for the apex and the bases: in the middle field there was a large cavity. Death occurred in October, 1944; an autopsy could not be performed. The diagnosis was of coalescent silicosis with tuberculous cavitation of the left lung.

**Case 4.**—A man aged 42, a raw candle turner for two years, and then a calcined candle turner and approver for nine years in factory ZA, since 1944 has suffered from dyspnoea on exertion, cough with scanty sputum, and

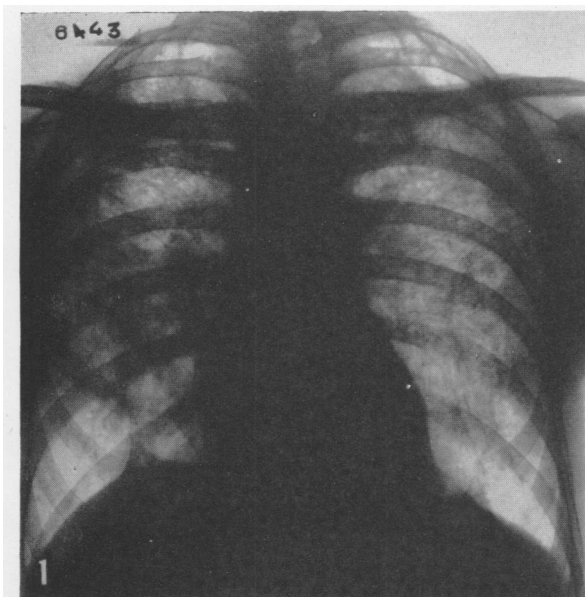


FIG. 1.—Case 1. Aged 35 : ten years a candle turner.

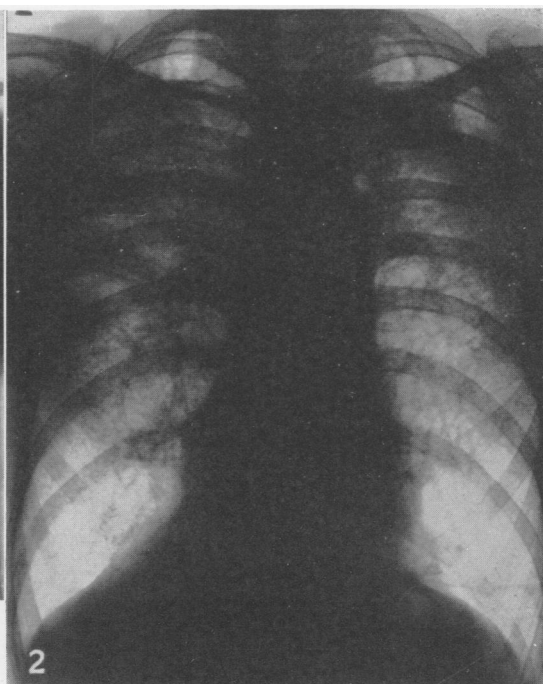


FIG. 2.—Case 2. Aged 36 : five years a crude candle turner and five years a calcined candle turner.

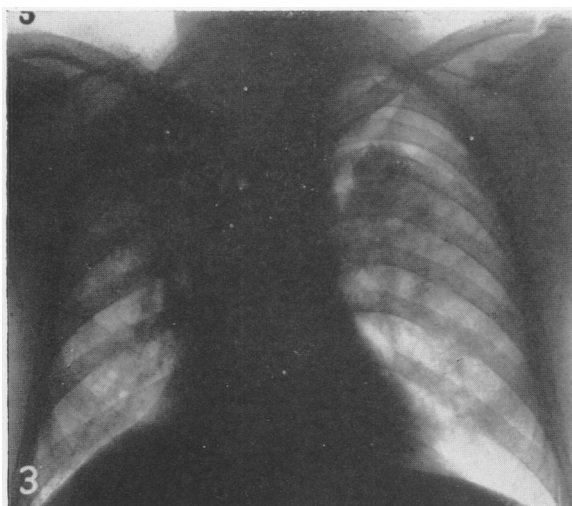


FIG. 3.—Case 4. Aged 42 : nine years a calcined candle turner and approver.

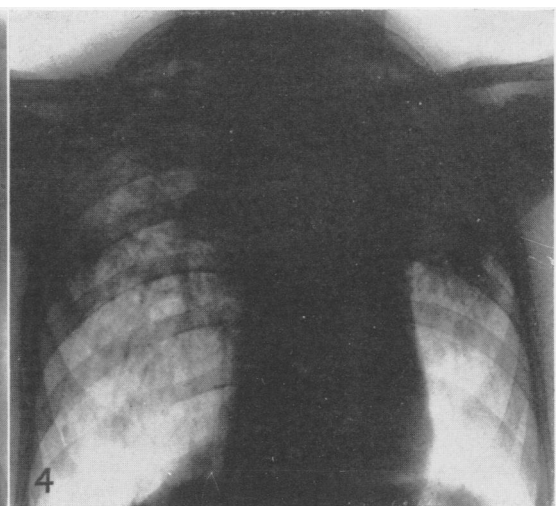


FIG. 4.—Case 5. Aged 60 : twelve years a candle driller.

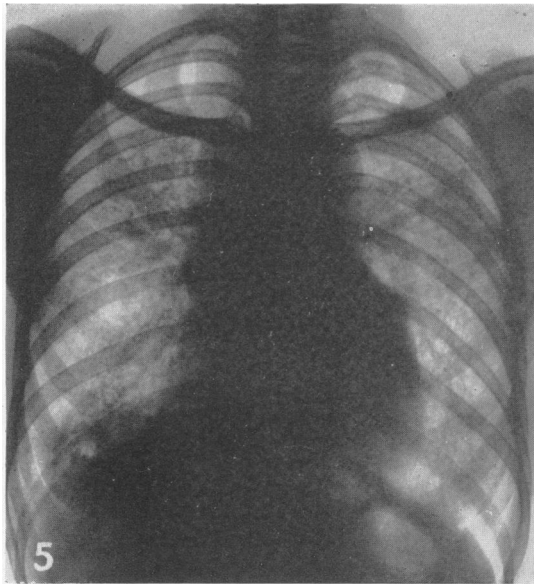


FIG. 5.—Case 6. A woman aged 45: four and a half years a candle fitter.

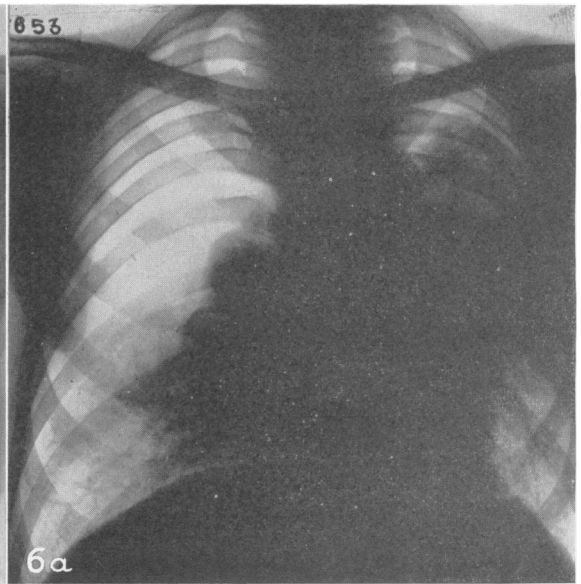


FIG. 6a—Case 7 Aged 41: eleven years a candle turner. Radiograph taken April, 1945.

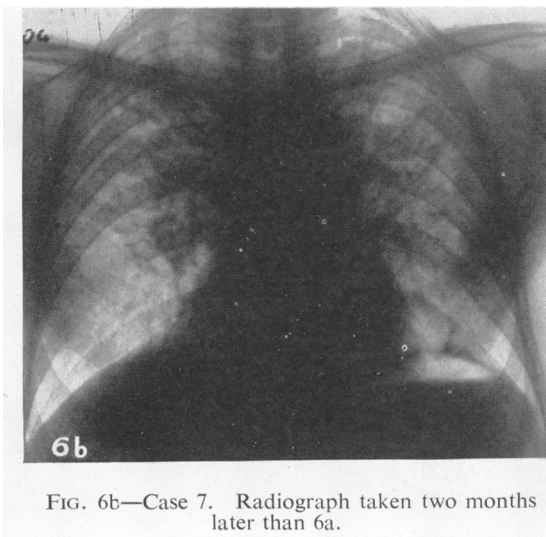


FIG. 6b—Case 7. Radiograph taken two months later than 6a.

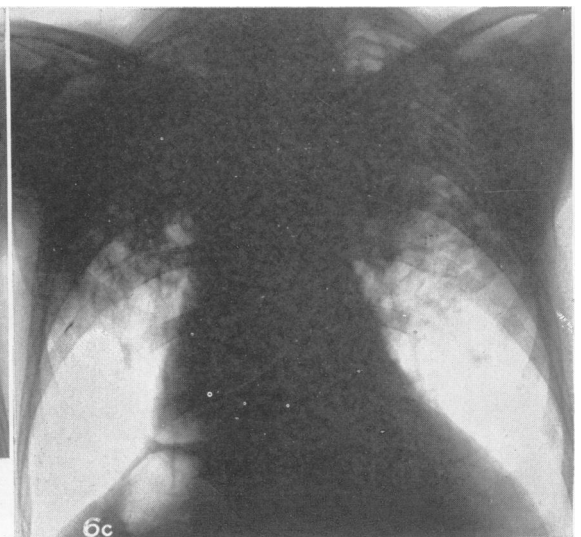


FIG. 6c—Case 7. Radiograph taken November, 1946

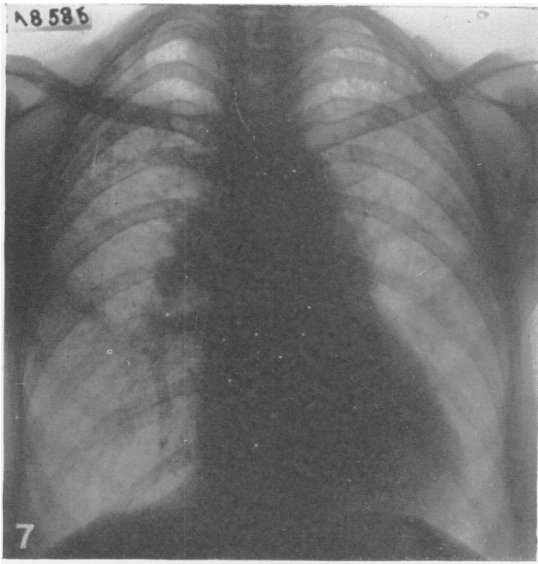


FIG. 7.—Case 11. A woman aged 50: seven years a candle fitter.

FIG. 8a.—X-ray diffraction pattern of crude diatomaceous earth, showing the absence of crystalline structure.

FIG. 8b.—X-ray diffraction pattern of diatomaceous earth calcined at 1,250° C., showing the spectrum of cristobalite.

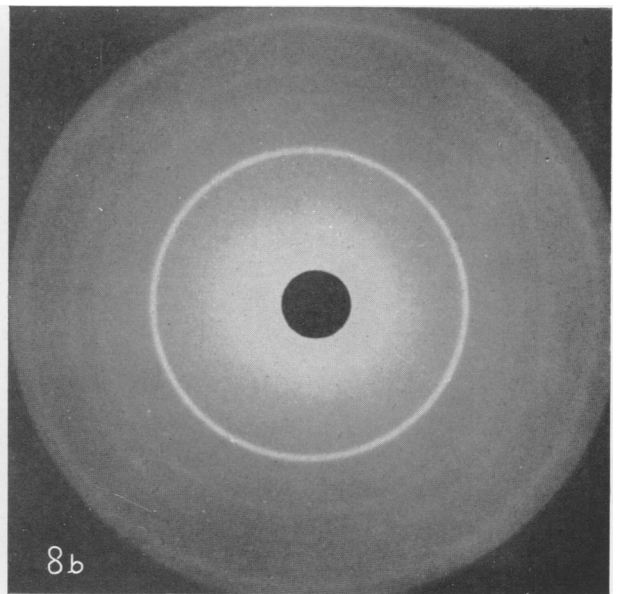
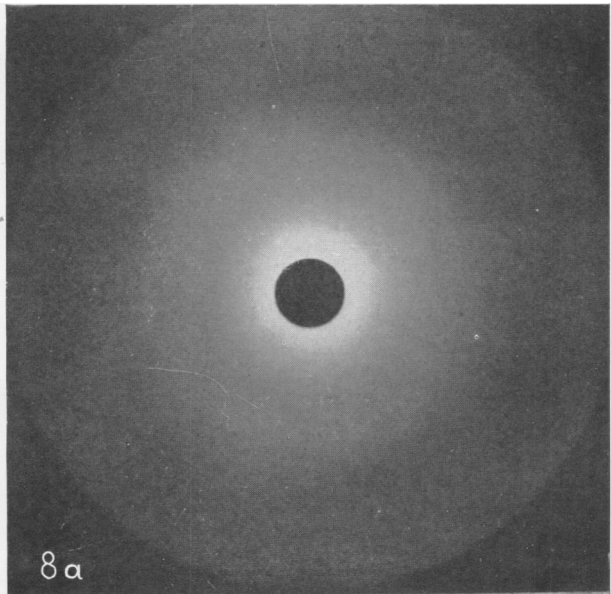
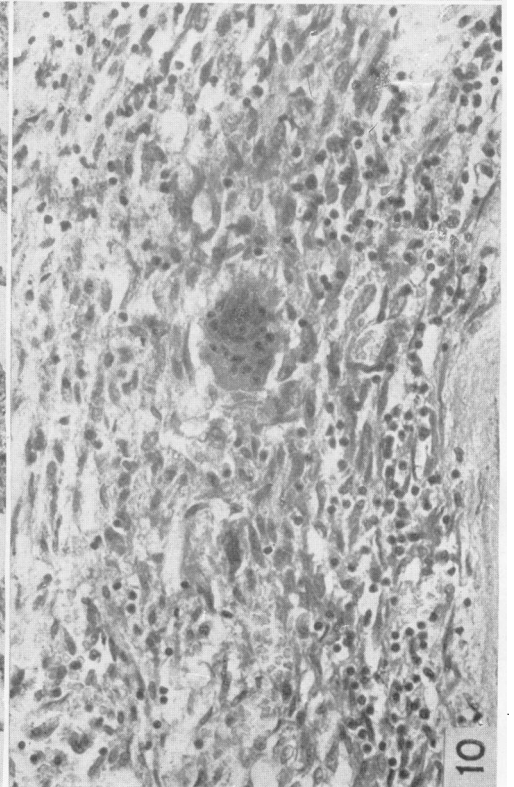
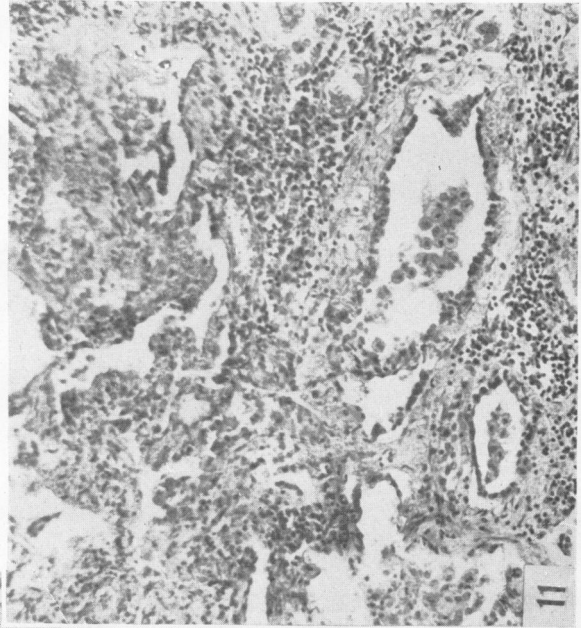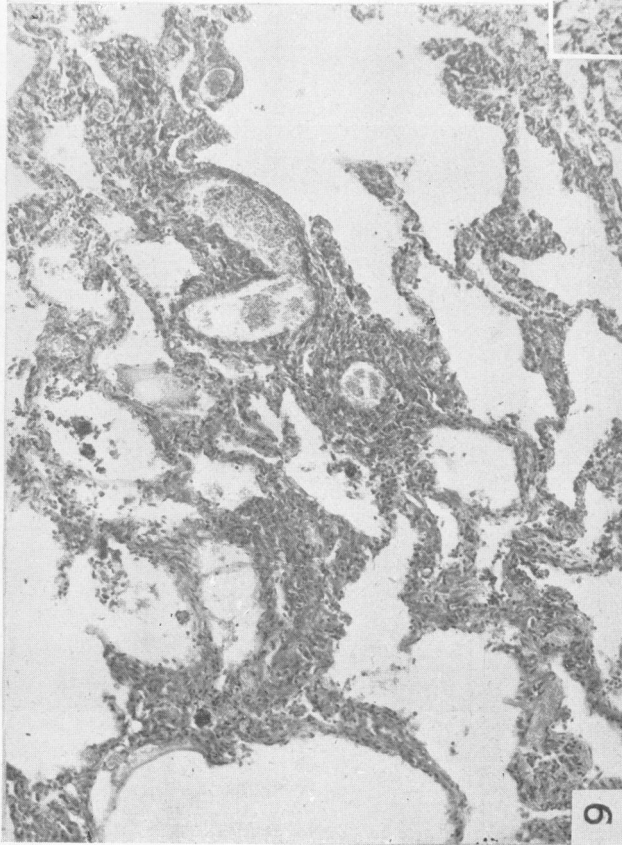
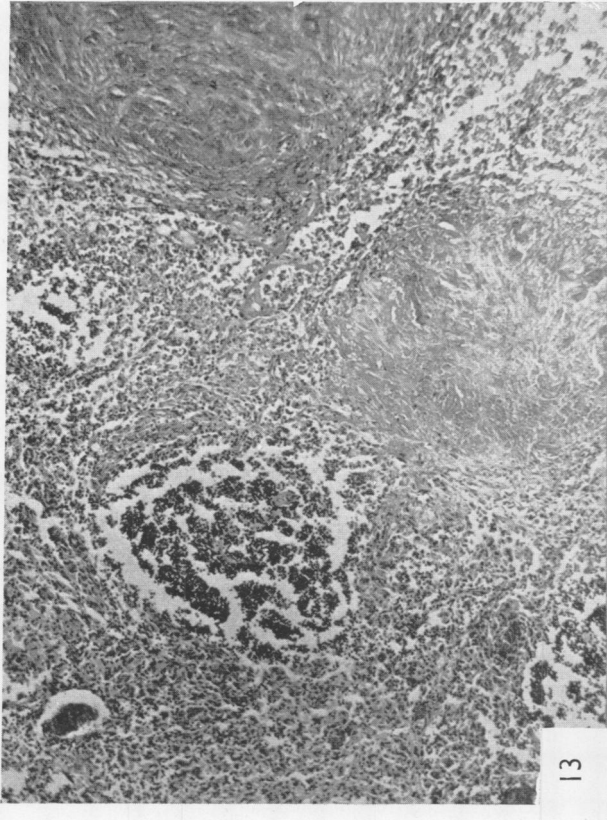


FIG. 9.—Lung: alveolar walls thickened by cellular hyperplasia.  $\times 100$

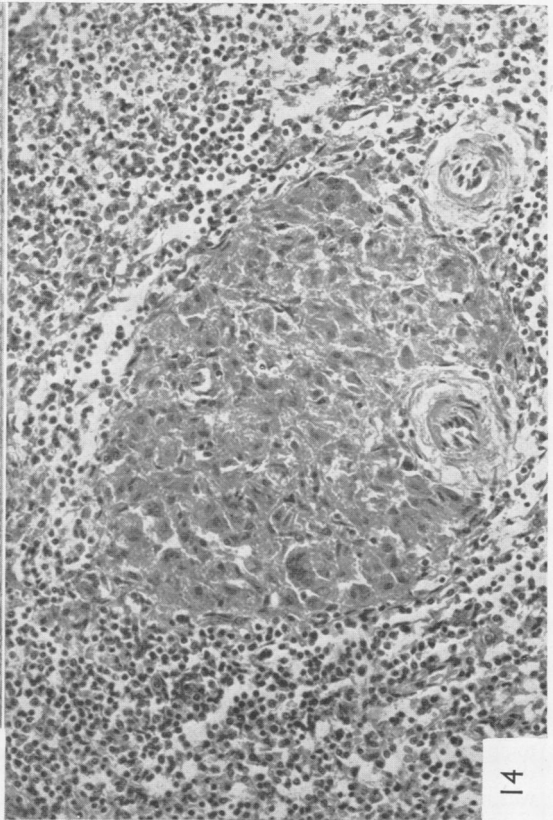
FIG. 10.—Lung: fibrotic area; granulomatous appearance with a giant cell.  $\times 300$ .

FIG. 11.—Lung: semi-consolidated area; bronchioli and air spaces with epithelial lining.  $\times 150$ .

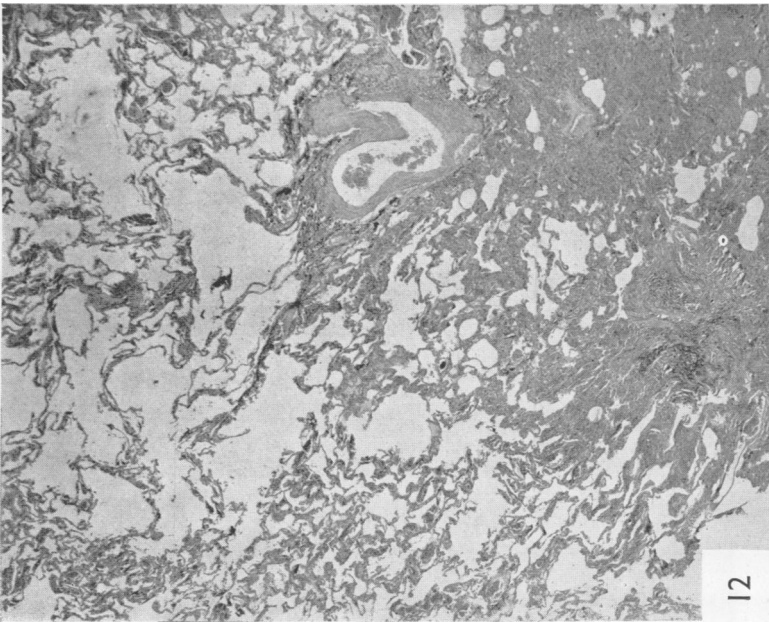




13



14



12

FIG. 12.—Lung : thickened alveolar septa ; emphysematous and consolidated areas.  $\times 15$ .

FIG. 13.—Lymph node : Lympho-reticular tissue islets surrounded with hyperplastic macrophages ; hyaline sclerosis.  $\times 100$ .

FIG. 14.—Spleen : heap of epithelioid cells connected with arteriolar branches of a Malpighian body.  $\times 200$ .



acute feverish bronchitis in the winter. In January, 1947, he suddenly had severe dyspnoea with cough and slight fever; he stayed at home for a month, then took up work again in spite of shortness of breath. In March, 1947, the clinical status was fairly good, though there was dyspnoea during the examination and slight cyanosis of the lips. The right lung had a flat percussion note in the upper zone, with very sharp breath sounds. The left lung had an impaired percussion note in the scapulo-vertebral zone, with very poor air entry. The radiograph revealed large fluffy shadows in the whole upper region and intense reticulation in the lower right field. There was pneumothorax at the left apex. The left lung showed fibrosis, especially in the upper zone. The upper mediastinum was poorly defined and displaced to the right (fig. 3). The diagnosis is of conglomerate silicosis with left pneumothorax.

**Case 5.**—A man aged 60, a calcined candle driller for twelve years in factory ZA, since 1943 has had progressive dyspnoea, and since 1944 persistent, unproductive cough. In 1943 he was sent to a sanatorium, from which he was dismissed after eleven months, with a diagnosis of silicosis. When examined in March, 1947, it was observed that his physique had become much worse since 1944. There was great wasting (weight 43 kg.), severe dyspnoea on minimal exertion, and persistent cough with scanty tenacious sputum, but no tubercle bacilli could be found in the sputum. There were clinical signs of coalescent fibrosis of the upper parts of the lungs, with dry, charkling rales. The erythrocyte sedimentation rate was 2 mm. in the first hour, and the Katz index 2. The tuberculin test was negative, and the temperature normal. The vital capacity was 1,000 c.cm., the breath-holding time 10 secs. The electrocardiogram was normal.

The radiograph showed marked pulmonary and pleural fibrosis of the upper left lobe, with rib contraction and displacement of the upper mediastinum towards the left; a golf-ball-like fibrotic conglomerate in the infraclavicular left zone; and marked emphysema in the lower half of the left lung, with many rainroads. There was coarse reticular fibrosis with coalescent nodules in the upper region of the right lung; and in the lower region more emphysema than fibrosis, with many rainroads. The heart was elongated and thin, displaced towards the left. There were pleural-diaphragmatic adhesions (fig. 4).

The diagnosis is of interstitial-nodular conglomerated silicosis, with fibro-thorax on the left side and marked emphysema.

**Case 6.**—A woman, aged 45, from October, 1940, to May, 1945, was a fitter in the candle-turning department: she worked near the lathe. From 1944 she experienced a feeling of weight in the shoulders, and in the winter suffered from bronchitis; there was loss of weight. After 1945 conditions became worse: she works now and then sweeping the factory offices. There is light dyspnoea at rest, persistent cough, and stabbing pains in the heart region. Examination in November, 1946, showed a wasted physique and slight cyanosis of the lips (height 153 cm., weight 39 kg., 30 breaths per minute, pulse 100). The chest was very thin, and there was

flatness of percussion note on both lungs except at the right apex and left base, where hyper-resonance was noted. Breath sounds were very sharp, with dry rales and rhonchi; at the right apex breath sounds were feeble. Hæmoglobin was 70, red cells 3,320,000 per c.mm., sedimentation rate 30 mm. in the first hour, and the Katz index 30. There were no tubercle bacilli in the sputum, and the temperature was normal.

The radiograph showed marked reticular and micro-nodular fibrosis, more severe at both infraclavicular zones and at the right base, where a tendency to conglomeration could be seen. The heart configuration was ill defined, the right lung root enlarged and thickened. Pneumothorax was present in the upper portion of the right pleural cavity (fig. 5). The diagnosis was of reticulo-nodular silicosis with right pneumothorax.

**Case 7.**—A man aged 41, a candle turner for eleven years, in factory ZA, since 1944 suffered from dyspnoea on exertion and cough. He lost 10 kg. in weight. There was some fever up to 38° C. (100.4° F.). In April, 1945, he had a sudden feeling of suffocation with spontaneous bilateral pneumothorax (fig. 6a). He recovered from the pneumothorax in two months (fig. 6b). After this he remained at home, almost always in bed, and often had bronchitis with fever, severe dyspnoea, and productive cough. By November, 1946, he had dyspnoea also at rest, very persistent cough, dyspepsia, and a feeling of exhaustion. He looked pale, wasted, and suffering (his height was 163 cm., his weight 42 kg., his respiration rate 24, and pulse 106 per minute). He breathed with difficulty and had very poor chest expansion. There were clinical signs of intense fibrosis of the upper half of the lungs with emphysema of the lower parts; also widespread musical rhonchi with prolonged expiration. The second heart sound at the pulmonary area was accentuated and reduplicated.

The radiograph showed very extensive fibrosis, reticular and patchy, shadowing almost homogeneously both upper halves of the lungs except the left apex. The lung roots were displaced toward the upper parts of the mediastinum. There was marked emphysema in the lower zones of the lungs (fig. 6c). On Jan. 10, 1947, there was suddenly extremely severe dyspnoea, faintness, and stabbing pains in the ribs, but no fever. Death occurred in two hours. The diagnosis was of conglomerate silicosis, with emphysema. (The autopsy is reported in the section on pathology.)

Other cases of silicosis are the following: *case 8*, a woman aged 44, a candle fitter for six years, who has moderately diffused reticular fibrosis; *case 9*, a woman aged 40, a candle finisher for five and a half years, who has marked diffuse reticular fibrosis with early nodulation in the lower parts of the lungs; *case 10*, a woman aged 48, a candle fitter for four years, who has reticular fibrosis with early nodulation; *case 11*, a woman aged 50, formerly fourteen years a cup turner in a pottery works (wet process), and now a candle fitter for seven years, who frequently has bronchitis in the winter, with productive cough, dyspnoea on exertion, and loss of weight. (the radiograph shows very marked reticular fibrosis with scattered little fibrotic patches (fig. 7)).

Case 12, a man aged 56, twelve years a candle washer, then twelve years manager of the candle-turning department, who has high blood pressure (200/115 mm. Hg.) and marked reticular fibrosis with micronodulation in the lower lung regions; case 14, a woman aged 40, ten years a candle finisher, who has moderately advanced reticulation, especially in the lower fields; and case 15, a man aged 56, who spent three years in a candle-turning department and has reticulation in the lower fields\*.

#### PATHOLOGY

Autopsy was performed on one of the patients (Case 7), who had been working eleven years exposed to calcined diatomaceous earth dust. The autopsy (Prof. Cattabeni), not mentioning lung findings on which we shall later make a fuller report, showed a conspicuous degree of consumption, the right heart dilated and hypertrophied, and multiple fibrous pleural adhesions with hæmorrhagic effusions under the pleuræ. Spleen, liver, and kidneys had signs of subchronic stasis. In the stomach was a scar from pyloric ulcer and congestive gastritis from stasis.

For our studies we had at our disposal both the lungs, many root and mediastinal lymph nodes, and part of the spleen. The pieces were fixed in 10 per cent. formol.

**Lung: Gross Findings.**—The lungs were both very much solidified, with fibrotic firmness in the cranial and middle parts. The condensed parts were not so hard and compact as in ordinary massive silicosis; they were blackish-grey in colour, with lighter grey stripes. They did not show any nodulation. Close to the condensed tissue in the middle parts could be seen many big emphysematous bubbles, generally subpleural; some up to 2 cm. in size, empty, with smooth walls. The lower middle zones had grown in firmness in a diffused and moderate way. Parts of the base were very emphysematous; touching them one could feel occasional irregular solidification. Root and mediastinal lymph nodes were not much enlarged; they were greyish-black, of hard, elastic firmness, juicy, and did not "shriek" when cut. Fragments of fibrotic tissue inoculated into four guinea-pigs failed to produce any evidence of tuberculosis after forty-five days.

**Histological Lung Findings** (figs. 9—12).—The whole lung parenchyma shows very intense congestion, especially in the capillaries. The air spaces were filled partly with iron pigments and very fine blackish-grey grains that did not react as iron. Most of the walls of

\* Another severe case came recently from a third factory manufacturing filtering candles. A man, aged 43, ten years a turner of calcined candles (1930—1940), since 1940 has suffered from cough, exertion dyspnoea, and progressive wasting. In October, 1940, he had empyema; since that year he has been repeatedly in tuberculosis sanatoria, but he has been without fever and without tubercle bacilli in the sputum. In July, 1947, his physique was wasted, his height 168 cm., and his weight 48 kg. There was dullness in the upper fields of the lungs, with very sharp breathing. The erythrocyte sedimentation rate (Westergren) was 4 mm. in the first hour, seven in the second; Katz index, 4. The Hb was 54, red cells 3,610,000 per c.mm., white cells 4,100. The vital capacity was 1,600 c.cm., and the breath-holding time 16 secs. The radiograph showed interstitial nodular fibrosis, with coalescence in the left subclavicular zone and intense emphysema at the left lower lobe. There were calcified lymph nodes at the right root, and costotomy at the tenth rib, with pleural adhesions at the right base. The diagnosis is of interstitial nodular silicosis, with coalescence and marked emphysema, the sequelæ of right emphysema.

the alveoli were quite thick owing to the great quantity of mononuclear cells with large cytoplasm, including very fine granules which could be demonstrated only with difficulty. These cells were irregularly accumulated; no distinct epithelial lining could be seen on the inner surface of the air spaces. Argyrophilic fibrils were present among these cells, but the collagenic ones were scarce; the elastic fibres were sometimes increased, sometimes decreased, the blood capillaries were filled with blood and appeared tortuous. The thickening of the air spaces where these met the consolidated segments was so conspicuous that the lumina were extremely reduced and sometimes they even disappeared; there were large compact fields in which all air-space architecture has disappeared and had been replaced by continuous and homogeneous amounts of cells similar to the ones we had noticed in the septa. Among these cells an occasional giant cell was seen, with small nuclei arranged centrally or sometimes peripherally. There were no tubercle-like cell aggregations, and no caseation. In these compact fields the sclerotic character was manifest: there were no elastic fibres; the numerous argyrophilic fibrils yielded to collagenic ones and to hyaline masses. A few remaining air-spaces included in the sclerotic fields were lined with cubic epithelium with gland-like appearances. In the most compact areas very few cells were scattered among the strands of fibrotic and hyalinized connective tissue.

The areas less affected by the cellular infiltration and by the sclerosis showed evidence of emphysematous dilatation of alveolar ducts and of the alveoli.

The unstriped muscular cells both of the bronchi and small arteries were increased in quantity. The bronchial lumina contained a great quantity of desquamated columnar cells, mixed with mucus and accumulated in compact heaps, which obstructed the lumina of the minor bronchi.

**Histological Findings on the Regional Lymph Nodes of the Lungs** (fig. 13).—In the lymph sinuses there were great numbers of cells containing hæmosiderin. Outside the sinuses infrequent islets of unaltered lympho-reticular tissue were to be seen, but most of the tissue was formed by epithelioid cells distributed in a homogeneous way, round, polygonal, or short spindle-shaped, containing in their cytoplasm many greyish-black powdery granules. The reticulum, stainable with silver, was here plentiful. Also the blood capillary network was quite evident among these cells, and their walls were thickened and intimately associated with the reticulum itself. Reticulum and capillaries became, through gradual thickening and collagenification, a fibrous network whose cells were more sparse and ended by constituting coarse and hyalinized collagenous masses, sometimes with concentric lamellar arrangements of silicotic type. Small foci of calcification were sometimes seen. Among the epithelioid cells very rare giant cells, as described in the lung, were scattered without any tubercular aggregation or caseation.

**Spleen: Histological Findings** (fig. 14).—Sub-chronic venous congestion was marked. Around the periphery

or in the framework of some Malpighian bodies, closely connected with arteriolar branches, could be seen little heaps of epithelioid cells which were quite similar to those in the lymph nodes; the transparency of their cytoplasm was almost obscured by very fine and hardly visible grey granules. Signs of sclerotic evolution were almost completely lacking. There were no giant cells.

**Dust Storage in the Tissues.**—By incinerating (in an electric oven at 500° C.) tissue sections, stained or unstained, applied on the glass slide according to the Rüttner and De Quervain (1947) method, we obtained spodograms very rich in ash. Some points, chosen on the sections and marked by means of the nonius microscope, were afterwards looked for on the spodogram, before and after treatment in hot nitrohydrochloric acid. On microscopic examination most of the ash was seen to disappear after treatment in nitrohydrochloric acid; the remaining particles were formed of very fine grains, partly visible but only by means of lateral lighting; the grains did not show a clearly crystalline structure, nor any form referable to diatomaceous fragments. Only very seldom did we find in the lung spodograms—and only once in a section of lymph node—small cylindrical refracting sticks with ends as if cut off, nearly 1  $\mu$  thick and 3 to 8  $\mu$  long. Examination by means of the polarizing microscope showed some very infrequent bi-refringent small crystals; most of the grains were not of this kind.

This dust could not be clearly recognized as diatomaceous. It should be noted that calcined diatomaceous earth dust shows rare and slight traces of centric, feather-and-comb-like structures which are characteristic of the crude dust, but that it is made up of very small structureless grains.

Dust grains resisting nitrohydrochloric-acid treatment corresponded to the following principal histological spots: (a) *in the lungs* we saw a great quantity of dust on the thickened walls of the air spaces, in the consolidated masses, and in the free alveolar cells; (b) *in the lymph nodes* small particles of dust were everywhere, being very sparse in the lymphocytic tissue, but abundant in the epithelioid cells and in the sclerotic masses; (c) *in the spleen*, dust was usually sparse and made up of quite small particles, mainly stored in the nodes of epithelioid cells; the rest in the red pulp. The lymphocytic Malpighian bodies and the connective tissue of the trabeculæ and of the vessels were free.

#### Comment on the Pathological Findings

The lung changes occurred after eleven years' exposure to the calcined diatomaceous earth dust and in the final stage become a diffuse fibrotic and hyaline sclerosis fairly similar to that of the massive quartz silicosis. But we have noted some important differences from the usual quartz silicosis: lack of hyalinized single or conglomerated nodules, and different feature of the changes leading to sclerosis. These changes consist in a diffuse cellular thickening of the walls of the lung air spaces, produced by proliferation of dust phagocytes. This proliferation

becomes gradually so marked that it replaces every air space and initiates a massive granuloma which only in a very late stage becomes fibrotic. Emphysema, dilatation of blood capillaries, and hyperplasia of all the smooth muscle cells of the arterioles and bronchi are secondary phenomena.

The diffuse distribution of changes in the air spaces somewhat resembles that of asbestosis; in asbestosis, however, there is early sclerotic thickening of the alveolar walls; in our case, on the other hand, the thickening is only cellular, and sclerosis can be observed almost only where cellular proliferation has overwhelmed the alveolar architecture.

In the literature we know of only six anatomical records of pneumoconiosis from diatomaceous earth dust; these were described by Nordmann in 1943; they are quite different from ours, having the common features of quartz silicosis, with the only peculiarity that he found in the lungs diatomaceous fragments, either naked, or covered with sheets very similar to those of the curious bodies of asbestosis. The diatomaceous earth dust inhaled by Nordmann's workers was crude and contained large amounts of quartz and—in three cases—also asbestos. The fact that our patient had been working only with ignited and quite pure diatomite must be taken into account in interpreting the great difference in the findings.

Is it possible to consider the picture we have described as characteristic of the pneumoconiosis from ignited diatomaceous earth dust? On the basis of a single case such an affirmation would hardly be justifiable. But some considerations should be emphasized. The possibility that, as well as dust, a chronic infective process, tuberculosis, for example, might be involved in the ætiology of this case, can be ruled out by the negative clinical findings and the negative guinea-pig test with fibrotic lung tissue. The following morphological findings also counter such a view: the homogeneous diffusion and bilateral symmetry of the uniform granulomatous process; the lack of nodular structures and of evidence of exudative and caseous changes; the rather "foreign-body" appearance of the rare and isolated giant cells; and the constant association of granulomatous change with the presence of dust particles. If tuberculosis were involved, it would have to be an exceptional morphological modification of it produced by baked diatomaceous earth dust. But this is entirely a matter of conjecture.

The most remarkable and striking peculiarity of our case, in comparison with the well-known characters of quartz silicosis, is the prevalence of the phagocytic hyperplastic reaction of the tissues coming into contact with dust (that is, the walls of

lung air spaces and the lymphoreticular tissue of lymph nodes and spleen) giving rise to a granulomatous rather than a fibrotic type of silicosis.

#### X-ray Diffraction Studies

Severe cases of silicosis have been observed in two factories manufacturing diatomite filter candles. This fact is in contrast to the experiences of many writers who affirm that diatomite is not significant as a producer of silicosis, but may be explained by the fact that what has hitherto been studied is the effect of raw diatomite, or diatomite that has been dried up for a short time at 500 to 600° C. We, on the other hand, have examined workers exposed to the inhalation of diatomite calcined at 1250° C. for several hours. Crude diatomite is in fact considered as an amorphous variety of free silica, though Berkelhamer (1941) affirms that diatomaceous earth and opal, formerly considered truly amorphous, may give an x-ray diffraction pattern indicating some crystalline structure. Calcination is likely to cause a change in the physical structure of diatomite: this opinion was first put forward by Kyropoulos, who in 1917 found that after calcination amorphous gelatinous silica produces an x-ray diffraction pattern indicative of tridimite; lately Durkan (1946) stated that calcined diatomaceous earth contains both amorphous and crystalline silica giving the x-ray pattern of cristobalite. These statements needed control to decide whether the great danger of calcined diatomite dust inhaled in making filter candles may be attributed to its crystalline form. We have therefore studied raw diatomite, and diatomite calcined at 1250° C., with the x-ray diffraction method. A Micro-Metalix apparatus with Debye-Scherrer equipment, and a Siemens apparatus with Laue equipment, were used for this purpose. Raw diatomite, as marketed and used in industry (mainly dried at 500 to 600° C.), showed no crystalline structure (fig 8a.) Diatomite calcined for three hours at 1250° C. in presence of coal and magnesite, as used for filter candles, showed an intense cristobalite pattern (fig. 8b). Purified diatomite with small quantities of electrolytes added, and heated at 900° C. for one hour, began showing the most intense line of the cristobalite spectrum; at the sixth hour of heating the intensity of the pattern reached its maximum. No tridimite pattern was seen in our experiments.

Therefore the diatomite silicosis seen in the filter-candle workers is a cristobalite micro-crystalline silicosis: refractory brick workers too are exposed to cristobalite dust in steel factories, although this cristobalite is macro-crystalline. There are, indeed, some analogies in the radiological aspect of silicosis by calcined diatomite and silicosis of masons in the

furnaces of steel works. It is very likely that the different internal structure of crude and calcined diatomaceous earth dust is the cause of their differing liability to cause silicosis: this is the only reasonable explanation of why crude amorphous diatomite dust produces mild and seldom incapacitating silicosis, while calcined micro-crystalline diatomite dust is liable to produce severe and not infrequently fatal cases.

#### Conclusion

Several cases of malignant pneumoconiosis, two of which were mortal, have been observed in two factories manufacturing filter candles. The material employed contains 80 per cent. diatomaceous earth. Since the other constituents (alumina and ferric oxide) and the added magnesite have no fibrosis-producing action, the cause of the pneumoconiosis lies in the micro-crystalline silica content of the calcined diatomite, which gives the x-ray diffraction-pattern of cristobalite. Therefore, the term diatomite silicosis seems appropriate, although from a clinical, radiological, and pathological point of view this type of silicosis differs somewhat from the classical silicosis set up by quartz.

Bearing in mind that the small number of our observations does not allow definitive conclusions, the most important clinical features of the ignited diatomite dust silicosis appear to be:

1. A rather rapid development and severe course of the silicosis. Case 2 showed advanced silicosis after five years' exposure; case 3 died of silico-tuberculosis after seven years' work; case 7 had advanced silicosis after five years' exposure; case 8 died of silicosis after eleven years' work; the majority of workers showed radiological signs indicative of silicosis after four years' work in the candle-turning department.

2. A tendency—resembling what occurs in asbestosis—to general wasting in the advanced stages of the disease, although not complicated by infection. Case 7 weighed 42 kg; case 5 43 kg; case 6 39 kg; case 2 46 kg.

3. Tendency to spontaneous pneumothorax, owing to the presence of numerous emphysematous sub-pleural blebs, especially in the apex. Of seven cases of advanced silicosis, three cases showed a spontaneous pneumothorax, one of which was bilateral.

4. Absence of a typical nodular stage in the radiograph, as seen in classical simple silicosis, notwithstanding the high free silica content of the inhaled dust. The fibrosis set up by diatomaceous earth seems more diffuse than nodular. In the early stages it is finely reticular, the reticulation being sometimes sharp and lace-like, sometimes

blurred in appearance ; in the more advanced stages the reticulation is coarser, both because of the presence of thick strips leading toward the root lung, and the evidence of a perisclerotic and compensatory emphysema. In severe cases the shadows are patchy, irregularly shaped, sometimes fluffy ; the shadows are often conglomerated, and even massive in the subclavicular regions and in the middle fields, where the reticular and patchy design is sometimes obscured by a more or less extended blurred appearance, somewhat resembling ground glass.

Three cases showed markedly enlarged root and mediastinal lymph nodes.

In the only case that we have examined pathologically, the pathological changes gave a general impression of extraordinary intensity of formative stimulus possessed by the diatomite dust, which, through a very strong cellular reaction, set up a young and exuberant granulomatous tissue, diffuse in type, without nodular growths, and only partly transformed in dense fibrotic and hyalinized mass ; these changes, associated with marked emphysema, explain the particularly rapid course of the ignited diatomite silicosis.

The reason for the difference between the mild silicosis observed among the crude diatomite workers and the malignant silicosis observed among the ignited diatomite workers probably lies in the fact that the ignition at 1250° C. transforms the

amorphous silicon dioxide of the crude diatomite earth into micro-crystalline cristobalite, which seems to be a very powerful silicosis-producing type of free silica.

## REFERENCES

- Adler-Herzmark, J., and Selinger, A. (1932). *Arch. Gewerbepath.*, 3, 58.  
 Beger, P. J. (1934). *Med. Klinik*, 30, 1222, 1258.  
 Beintker, E. (1935). *Virchows Arch.*, 294, 546.  
 Berkelhamer, L. H. (1941). *J. industr. Hyg.*, 23, 163.  
 Campbell (1940). Quoted by Middleton, E. L. *Silicosis: Proceedings of the International Conference at Geneva*. I.L.O. Geneva, p. 134.  
 Durkan, T. M. (1946). *J. industr. Hyg.*, 28, 217.  
 Duvoir, M., Derobert, L., and Journet, H. (1946). "Recueil des Travaux de l'Institut National d'Hygiène." Masson : Paris. vol. 2, p. 580.  
 Gardner, L. U. (1940). *Industr. Med.*, 9, 45.  
 Gudjonsson, Sk. U. (1934). *Aerzt. Sachverst. Ztg.*, 40, 145.  
 Kyropoulos (1917). *Z. anal. Chem.*, 99, 197.  
 Legge, R. T., and Rosencrantz, E. (1932). *Amer. J. publ. Hlth.*, 22, 1055.  
 McCord, C. P. (1936). *J. Amer. med. Ass.*, 106, 913.  
 Martin, Vallaud, and Champeix (1947). *Le Médecin d'Usine*, 9, 295.  
 Middleton, E. L. (1936). *Lancet*, 2, 59.  
 —(1940). Three communications on the effect of mixed dust. Fuller's Earth Silicosis : *Proceedings of the International Conference at Geneva, Aug. 29—Sept. 9, 1938*. I.L.O. Geneva, p. 134.  
 Nordmann, M. (1943). *Virchows Arch.*, 311, 116.  
 Nuck. (1934). "Jahresbericht über die Tätigkeit der preussischen Gewerbemedizinäräte während der Kalenderjahres 1933," veroff. a.d. Gebiete d. Medizinalverwaltg., Schoetz : Berlin. p. 105.  
 Podwyszoeki, W. (1910). *Beitr. path. Anat.*, 47, 270.  
 Policard, A. (1936). *Bull. Histol.*, 13, 28.  
 —(1940). Silicosis : *Proceedings of the International Conference at Geneva, Aug. 29—Sept. 9, 1938*. I.L.O. Geneva, p. 22.  
 —(1940). Silicosis : *Proceedings of the International Conference at Geneva, Aug. 29—Sept. 9, 1938*. I.L.O. Geneva, p. 25.  
 Rüttner, J. R., and De Quervain, F. (1947). *Z. Unfallmed. Berufskr.*, 40, p. 75.  
 Siegmund, (1934). *Aerzt. Sachverst. Ztg.*, 40, 285.  
 Solowiev, B. M., and Pinus, A. A. (1928). *C.R. Soc. Biol. Paris*, 99, 546.