

**Imaging cerebral arteries tortuosity and velocities by transcranial *Doppler* ultrasound is a reliable assessment of brain aneurysm in mouse models**

Héloïse Lebas<sup>1</sup>, Alexandre Boutigny\*<sup>1,2</sup>, Clémence Maupu\*<sup>1</sup>, Jonas Salfati<sup>1</sup>, Cyrille Orset<sup>3</sup>, Mikael Mazighi<sup>1,4</sup>, Philippe Bonnin<sup>1,2</sup>, Yacine Boulaftali<sup>1</sup>

1. Université de Paris and Université Sorbonne Paris Nord, INSERM U1148, LVTS, 75018 Paris, France

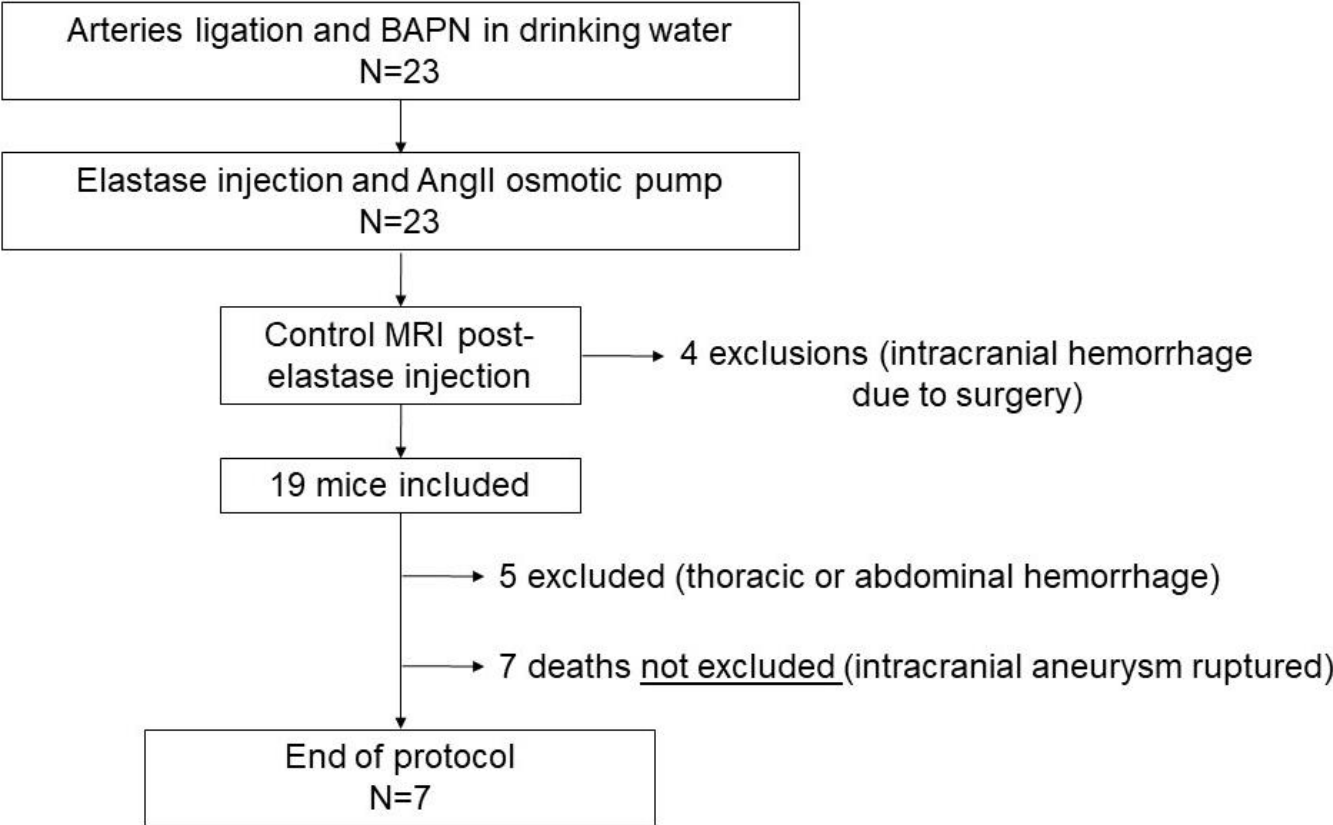
2. Service de Physiologie Clinique Explorations Fonctionnelles, AP-HP, Hôpital Lariboisière – F Widal, 75010, France

3. UMR-S U1237 "Physiopathology and Imaging of Neurological Disorders", Centre CYCERON, 14074 Caen, France

4. Département de Neuroradiologie Interventionnelle de la Fondation Rothschild et Département de Neurologie, Hôpital Lariboisière, Paris, France

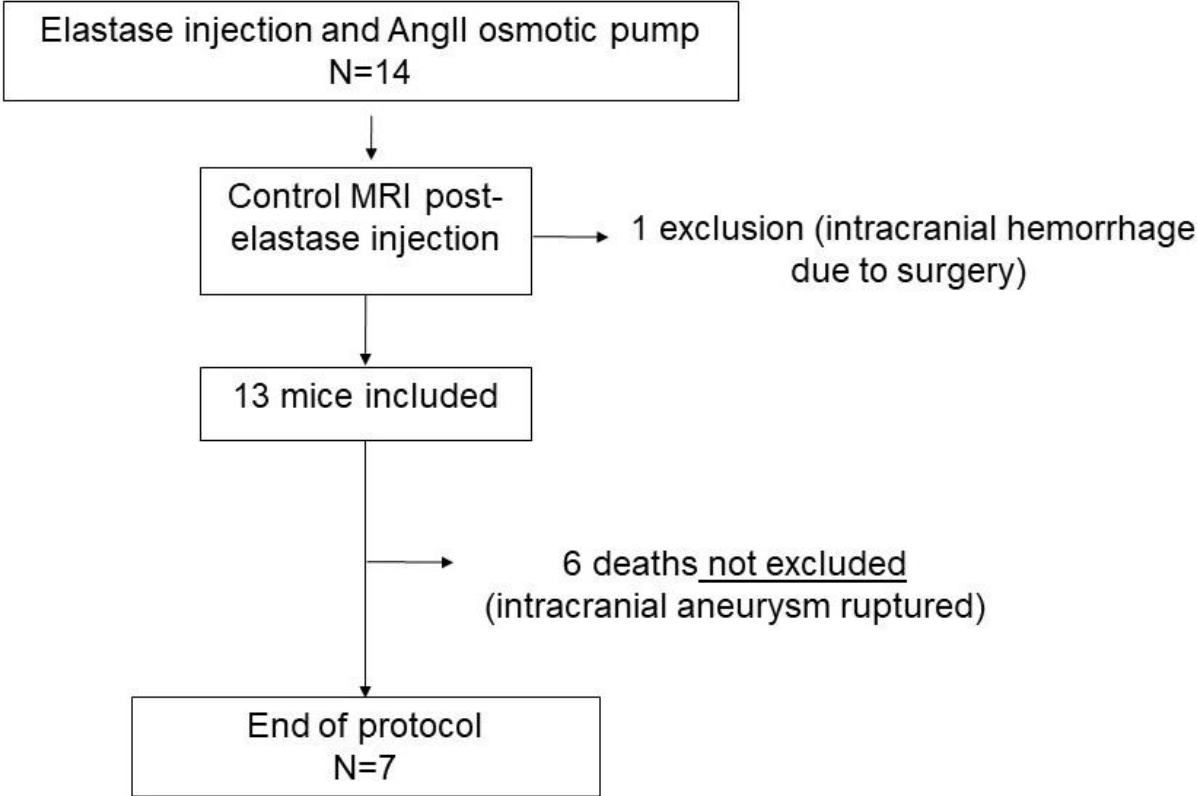
\* These authors contributed equally

Hoh's model



**Supplemental Figure 1:** Flowchart of Hoh's model depicting the numbers of animals used in the study and drop-outs

Hashimoto's model



**Supplemental Figure 2:** Flowchart of Hashimoto's model depicting the numbers of animals used in the study and drop-outs.