

Infantile cystoid maculopathy

MICHAEL T. TRESE AND ROBERT Y. FOOS

From the Department of Ophthalmology and the Department of Pathology, Jules Stein Eye Institute, UCLA School of Medicine, Los Angeles, USA

SUMMARY Three premature infants with no family history of eye disease showed bilateral cystoid maculopathy on post-mortem examination. These macular lesions are indistinguishable macroscopically from the macular lesions of sex-linked juvenile retinoschisis. Cystoid change was observed at various vertical retinal levels. The oldest child had a schisis cavity within the nerve fibre layer. All cases had reduced numbers of retinal ganglion cells and central nervous system (CNS) abnormalities. The authors believe these are the first reported cases of a cystoid macular lesion present at birth and the first description of the pathological features of a cystoid macular lesion in infants.

Cystoid macular change in infants is often a manifestation of hereditary eye disease.¹ With a hereditary cause in mind it has been postulated that these macular lesions exist at birth, yet such an observation has not been reported.² At necropsy we have observed cystoid maculopathy in 3 premature infants without a history of familial eye disease. Similar macular changes have been noted clinically since at least 1898,³ yet the histopathological features of this lesion in children have never been described. This paper presents these histopathological features and reports the existence of such a cystoid maculopathy at birth.

Materials and methods

The material for this study included both eyes from 3 infants examined at necropsy either at the UCLA Center for the Health Sciences or at the Los Angeles County Harbor General Hospital over a 15-year period. All eyes were taken within 2 to 6 hours of death.

Preparation, gross sectioning, macroexamination, and recording of findings were performed according to our routine methods.⁴ Microsections were prepared from celloidin-embedded eyes stained with haematoxylin-eosin and peroxidic acid Schiff technique and alcian blue to determine the location and contents of these spaces.

Case reports

CASE 1

A black infant boy weighing 820 g was born to a healthy 24-year-old woman. The pregnancy was unremarkable. Fetal heart tones were present on admission to hospital for delivery. Three generations of family members were contacted by telephone and letter, and no history of eye disease was found. Father and brother were examined and their eyes were found to be normal. Delivery was complicated by premature rupture of membranes. The child survived 11 days before succumbing to respiratory distress syndrome. Supplemental oxygen therapy was necessary to maintain a PO_2 of between 21 and 177 mmHg.

Significant systemic necropsy findings were restricted to immaturity of the white matter of the central nervous system.

Ocular examination. The right eye measured 14.2 mm (AP) \times 14.8 mm (H) \times 13.5 mm (V). The left eye measured 14.1 mm (AP) \times 14.5 mm (H) \times 13.6 mm (V). When incised, both eyes showed cystoid changes in the maculae (Fig. 1). The peripheral retina and vitreous cavity were unremarkable. On light-microscopical examination notable findings included bilateral cystoid change confined to the macula and involving predominantly the outer nuclear layers. These cavities were outlined by Müller cell pillars. The retinal ganglion cells were markedly reduced in number. The peripheral retina was unremarkable (Fig. 2).

CASE 2

This was a stillborn infant girl weighing 1.45 kg

Correspondence to Robert Y. Foos, MD, Jules Stein Eye Institute, UCLA School of Medicine, Los Angeles, California 90024, USA.

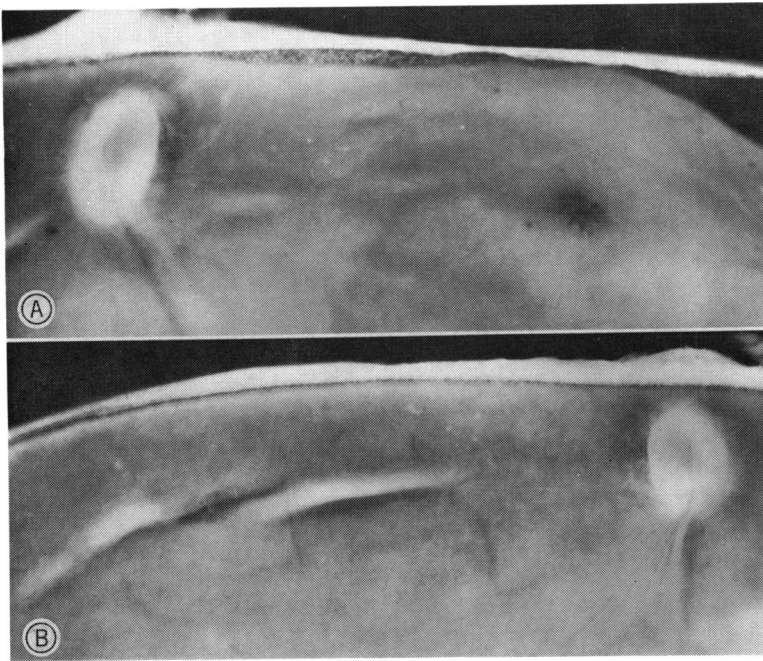


Fig. 1 Case 1. Macroscopic appearance of macular lesions. (A) Right eye showing multiple small cystoid change, radially arranged ($\times 18$). (B) Left eye showing a more subtle similar lesion than (A) ($\times 18$).

born to a healthy 29-year-old Hispanic woman. There was no family history of eye disease. The delivery was complicated by placental abruption.

Post-mortem examination revealed an anencephalic infant with a cervical meningocele, who was otherwise appropriately developed for her birth weight.

Ocular examination. The right eye measured 16.2 mm (AP) \times 16.8 mm (H) \times 16.6 mm (V);

the left eye 16.4 mm (AP) 16.8 mm (H) \times 16.6 mm (V). The 2 eyes were unremarkable with the exception of cystoid lesions in the maculae. The peripheral retina and vitreous cavity were unremarkable. Except for the macular lesions both eyes were unremarkable on microscopic examination. In the macula were moderately reduced numbers of ganglion cells and cystoid spaces that involved the inner nuclear layer. The Müller pillars were stretched

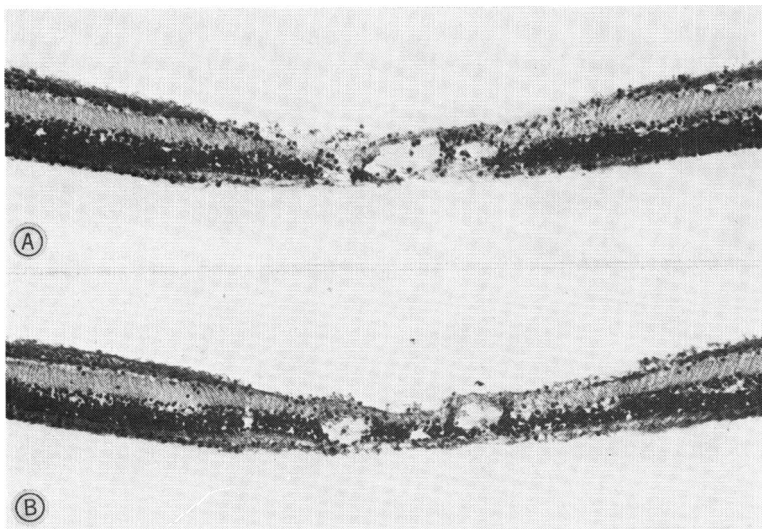
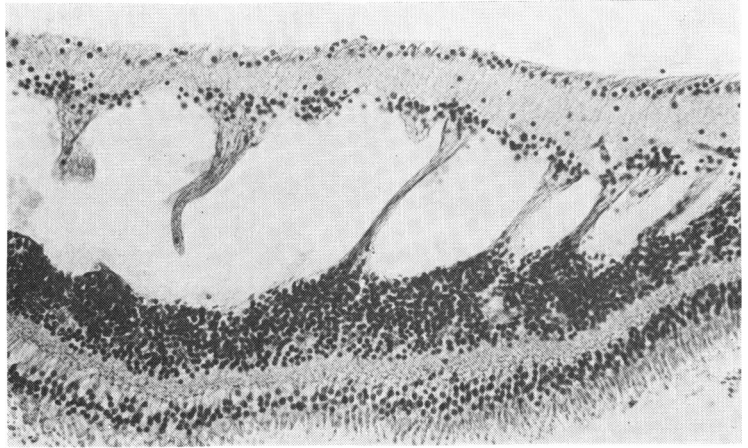


Fig. 2 Case 1. Microscopic appearance of macular lesions. (A) Right eye showing multiple cystoid spaces involving the outer nuclear layer (haematoxylin-eosin, $\times 142$). (B) Left eye showing less extensive cystoid maculopathy (haematoxylin-eosin, $\times 142$).

Fig. 3 *Case 2. Macula showing extensive cystoid change in middle retinal layers with stretched and seemingly broken Müller pillars on left. Note similarity to typical cystoid degeneration of peripheral retina (haematoxylin-eosin, $\times 146$).*



across these cavities (Fig. 3). The peripheral retina was unremarkable.

CASE 3

A white stillborn boy weighing 3.32 kg was born to a healthy 25-year-old woman. There was no family history of eye disease. Fetal heart sounds were present when the mother arrived at the hospital for delivery. The pregnancy and delivery were uncomplicated.

The necropsy showed hydrocephalus, spina bifida, and patent ductus arteriosus. The infant was otherwise normal for his birth weight.

Ocular examination. Both eyes were large. The right measured 21.2 mm (AP) \times 19.0 mm (H) \times 19.9 mm (V); the left eye, 21.1 mm (AP) \times 20.0 mm (H) \times 18.8 mm (V). Both corneas measured 9.8 mm (H) \times 11 mm (V). When incised both eyes showed large excavation of the optic nerve head. Central cystoid lesions and paracentral schisis cavities were observed within the macula in each

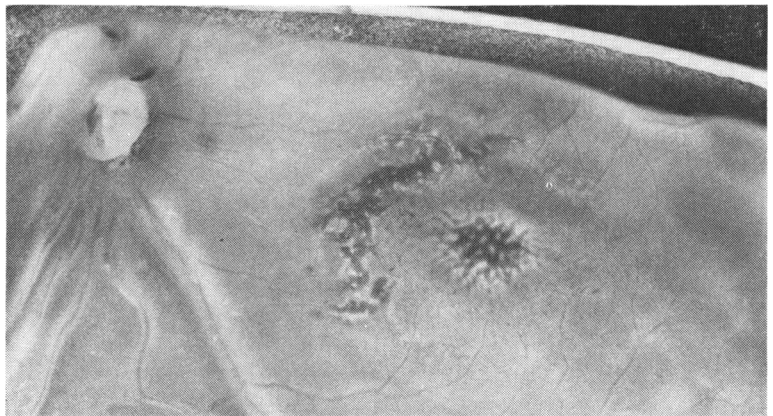eye (Fig. 4). The peripheral retina and vitreous cavity were unremarkable.

Both macular lesions in each eye were examined microscopically. The more central lesion showed cystoid change within the nerve fibre layer. A small amount of haemorrhage was contained in one of these spaces (Fig. 5A). The paracentral lesion was a large schisis cavity within the nerve fibre layer, which had lost the radial support of the Müller pillars (Fig. 5B). The number of ganglion cells was moderately reduced. The anterior chamber angles were dysplastic. The peripheral retina and vitreous were unremarkable.

Discussion

These 3 cases show cystoid changes in the maculae of both eyes. Cavitation was present at various retinal levels and in the oldest infant large schisis cavities were within the nerve fibre layer. Macroscopically these lesions are identical to the macular

Fig. 4 *Case 3. Macula of left eye showing central cystoid change with Müller pillars intact (white dots) and paracentral crescent-shaped area of macular schisis with loss of Müller pillars ($\times 17$).*



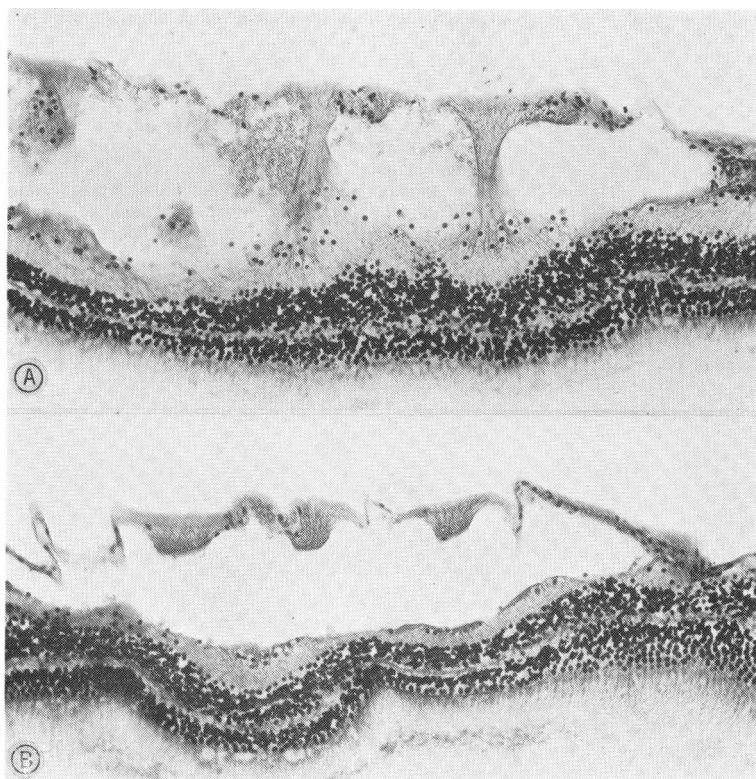


Fig. 5 Case 3. Macula of left eye. (A) Central lesion showing cystoid change within the nerve fibre layer and Müller pillars stretched across cavities. Note similarity to peripheral reticular cystoid degeneration (haematoxylin-eosin, $\times 114$). (B) Paracentral lesion showing loss of Müller pillars and formation of a large reticular-like (bullous) schisis cavity within the nerve fibre layer (haematoxylin-eosin, $\times 160$).

lesions of sex-X-linked retinoschisis, but in view of the negative family history of eye diseases this diagnosis is unlikely. Since 50% of patients with sex-X-linked retinoschisis have only macular lesions, however, the possibility of a spontaneous genetic mutation must be considered.⁵ Some authors consider that cystic macular change precedes peripheral retinoschisis.⁶

Yanoff *et al.*⁷ postulated that the underlying defect in sex-X-linked retinoschisis is in the inner cytoplasm of Müller cells, which allows retinoschisis cavities to form. In our cases the Müller cells are stretched and broken across cystoid/schisis cavities, adding support to the hypothesis of Yanoff *et al.* As in hereditary juvenile retinoschisis the retinal cavities in our cases contained no acid-mucopolysaccharide material. In all cases the peripheral retina was unremarkable.

It is well known that the peripheral retinoschisis lesions of sex-X-linked retinoschisis tend to affect the nerve fibre layer and cause large bullous thin-walled cavities extending into the vitreous.⁷⁻¹⁰ The macula of an affected child has never been described. Manschot¹¹ has described the eyes of a 60-year-old man who was a member of a family known to have the gene for X-linked retinoschisis, and these eyes showed wrinkling of the internal limiting

lamina and splitting of the nerve fibre layer with normal underlying retinal tissue. Our eyes showed reduced ganglion cells seemingly related to the patients' concomitant CNS changes.

Von Sallman¹² pointed out that generalised retinal cystoid changes and even splitting of the nerve fibre layer can be produced by prepartum compromise of the carotid jugular circulation in rhesus monkeys. These lesions, although extensive, did not involve the macula. In our cases there is no evidence, from the general necropsy data or from the ocular pathological findings to support an ischaemic aetiology for the selective macular lesions seen in these 3 infants. In all cases retinal ganglion cells were reduced in number. All children had central nervous system abnormalities, which may relate to the poorly developed ganglion cell layer. One case had a patent ductus arteriosus seemingly unrelated to the ocular changes. The authors have been unable to determine if these retinal and CNS lesions are meaningfully associated or if the CNS lesions only allow the fortuitous necropsy study of these eyes.

This work was supported in part by Public Health Service Grants EY-00725 and EY-00331 from the National Eye Institute, National Institutes of Health.

References

- ¹Deutman AF. *The Hereditary Dystrophies of the Posterior Pole of the Eye*. Assen, The Netherlands: Royal Vangorcum, 1971; 48-99.
- ²Kraushar MF, Schepens CL, Kaplan JA. Congenital retinoschisis. In: Tolentino FI, Schepens CL, Freeman HM, eds. *Vitreoretinal Disorders, Diagnosis, and Management*. Philadelphia: Saunders, 1976; 249-59.
- ³Haas J. Ueber das Zusammenvorkommen von Vernä-derungen der Retina und Chorioidea. *Arch Augenheilk* 1898; 37: 343-8.
- ⁴Roth AM, Foos RY. A system for the macroexamination of eyes in the laboratory. *Am J Clin Pathol* 1973; 59: 674-83.
- ⁵Krill AE. *Hereditary Retinal and Choroidal Diseases*. New York: Harper and Row, 1977; 2: 1044-62.
- ⁶Harris GS. Juvenile sex-linked retinoschisis. *Mod Probl Ophthalmol* 1969; 8: 363-70.
- ⁷Yanoff M, Kertesz E, Zimmerman LE. Histopathology of juvenile retinoschisis. *Arch Ophthalmol* 1968; 79: 49-53.
- ⁸Yanoff M, Fine B. *Ocular Pathology: A Text and Atlas*. New York: Harper and Row, 1975; 416-32.
- ⁹Hogan M, Zimmerman LE. *Ophthalmic Pathology: An Atlas and Textbook*. Philadelphia: Saunders, 1962; 535-7.
- ¹⁰Zimmerman LE, Naumann G. The pathology of retino-schisis. In: *New and Controversial Aspects of Retinal Detachment*. McPherson A, ed. New York: Hoeber, 1968; 400-23.
- ¹¹Manschot WA. Pathology of hereditary juvenile retino-schisis. *Arch Ophthalmol* 1972; 88: 131-8.
- ¹²Von Sallman L. The effect of intrauterine surgical proce-dures on the development of the primate eye. *Invest Ophthalmol* 1969; 8: 51-60.