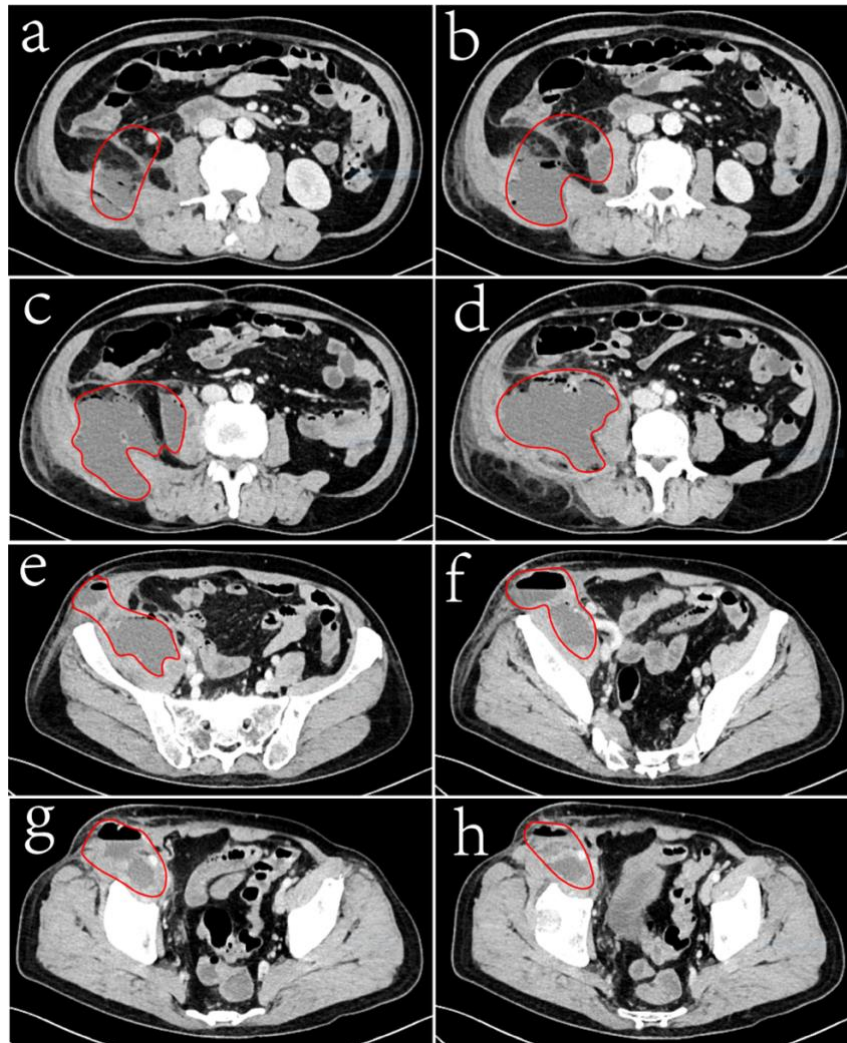


Supplementary Figure S1A Red circles show the extent and size of the iliopsoas abscess alphabetically.



Supplementary Figure S1B Colonic barium enema shows no contrast medium spillage from the appendiceal stump in alphabetical order.

