

## Corneal graft rejection: a new rabbit model and cyclosporin-A

P. A. HUNTER, A. GARNER, K. R. WILHELMUS, N. S. C. RICE,  
AND B. R. JONES

*From the Department of Clinical Ophthalmology, the Institute of Ophthalmology, and Moorfields Eye Hospital, London*

**SUMMARY** In order to test the efficacy of topically applied cyclosporin-A in preventing corneal allograft rejection, existing rabbit models were modified to produce a new model in which the allograft reaction could be consistently initiated solely as a result of corneal transfer without any additional means of sensitisation. With this model, which reflects clinical corneal grafting more closely than many previous models, cyclosporin-A 1% drops applied to the recipient eye 5 times daily for 4 weeks inhibited corneal graft rejection. When cyclosporin-A 1% drops were applied to corneal allografts for 13 weeks, 44% of grafts remained clear 180 days after transplantation. No side effects were observed that could be attributed to topically applied cyclosporin-A.

Corneal grafts have been performed in animals ever since such surgery was first suggested in man.<sup>1</sup> Early attempts in animals to explore the feasibility of such operations produced a variety of results,<sup>2–4</sup> and much of the subsequent animal work was directed towards obtaining consistently clear grafts.<sup>5–8</sup> As materials and techniques improved, many workers achieved success rates of 75–100% in animal models,<sup>9–13</sup> and such work has laid the foundation for modern corneal graft surgery.

The recognition of the antigenicity of corneal tissue<sup>14</sup> and graft rejection in man<sup>15</sup> has led to the development of new animal models in order to further understanding of the allograft reaction in man. Because of the difficulty in reproducing corneal graft rejection in animals by normal methods many of these experiments relied on additional means of sensitisation of the allograft, such as delayed skin transfer<sup>9,16</sup> or transfer of previously sensitised lymphocytes,<sup>17</sup> in order to produce a consistently high rejection rate. Another method used to encourage allograft rejection has been to promote vascularisation by the use of eccentrically placed lamellar grafts or delaying suture removal in centrally placed

penetrating grafts, but many such grafts fail to undergo rejection.<sup>18</sup> Xenografts have been found to have a consistently high rejection rate in animals,<sup>19,20</sup> and both allograft and xenograft models have been used to investigate methods of suppressing the immune response by means of drug therapy.<sup>19,21–23</sup>

Cyclosporin-A (CyA) administered by intramuscular injection has been reported to suppress the allograft reaction in a rabbit model which relied on additional skin transfer in order to sensitise the animal,<sup>24</sup> though when applied topically to the recipient eye in the same model it had no effect.<sup>25</sup> CyA, however, may have potentially serious side effects when administered systemically in man,<sup>26</sup> and these would limit its use in clinical corneal grafting. It also appears that CyA acts early in the immune response and to be effective should be given at the time and place of sensitisation,<sup>26,27</sup> which is not possible by topical application in existing models of the corneal allograft reaction.

We therefore set out to develop a new model of corneal graft rejection in which the allograft reaction is initiated solely as a result of the transplanted corneal tissue without any additional means of sensitisation. This would enable CyA to be delivered as a topical agent to a site where it may be effective. A new model is described together with the results of its use with various schedules of CyA treatment.

Correspondence to Mr P. A. Hunter, FRCS, Department of Clinical Ophthalmology, Moorfields Eye Hospital, City Road, London EC1V 2PD.

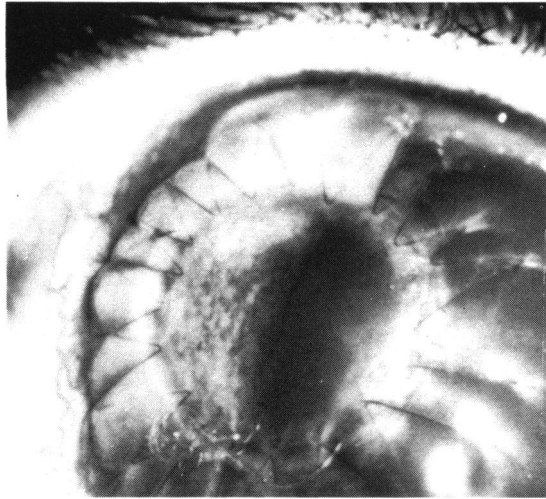


Fig. 1 Rabbit autograft (day 4) sutured with continuous 10/0 monofilament nylon showing iris detail and dilated pupil edge through the clear graft.

### Materials and methods

Outbred strains of Dutch and New Zealand white rabbits weighing between 0.7 and 3.8 kg underwent partial penetrating corneal grafts either as pairs for allografts (one of each type of rabbit) or singly for autografts. Preoperatively, the animals were given intravenous pentobarbitone sodium (60 mg/ml) in doses varying between 0.8 and 2.5 ml according to their weight and response to the anaesthetic. Topical anaesthetic drops (proparacaine HCl 0.5%) were instilled into their right eyes together with drops of cyclopentolate 1% and phenylephrine 10% to achieve maximal dilatation of the pupil. 1 ml of heparin (5000 units/ml) was given intravenously to each animal in order to prevent clotting of the secondary aqueous. All operations were performed under an operating microscope.

#### OPERATIVE TECHNIQUE

After fixation of the eye by means of 4/0 silk sutures to 2 recti muscles a 6 mm trephine was used to perform a partial penetrating keratoplasty placed eccentrically in the upper temporal quadrant of the right cornea of each animal. The graft was positioned in such a way that a 1–2 mm margin of host cornea was visible at the point where the graft came nearest to the limbus. After the anterior chamber was entered with the trephine, the incision was completed with corneal scissors. The corneal discs were then interchanged and held in place initially with 4 interrupted 10/0 monofilament nylon sutures which were removed at

the end of the operation. A continuous 10/0 monofilament nylon suture was then used to secure the graft with the knot placed on the side of the graft nearest the limbus in order to encourage vascularisation, with no attempt being made to bury the knot (Fig. 1). The anterior chamber was not artificially reformed; thus the iris was left in contact with part of the corneal wound to promote the formation of synechiae and subsequent deep corneal vascularisation. At the end of the procedure chloramphenicol ointment was placed on the operated eye at the same time as some animals received their first dose of CyA. Autografts were performed in an identical manner except that the discs were sutured back into the same animal.

#### POSTOPERATIVE MANAGEMENT

All animals received atropine 1% drops and chloramphenicol ointment daily until the removal of the corneal suture on the 14th day. On the first postoperative day slit-lamp examination was carried out and the following points were noted: the clarity of the graft and host cornea, anterior chamber depth and reaction, extent of corneal/iris adhesions, and any evidence of lens damage. Subsequent daily slit-lamp examinations were performed to assess the rate of the clearing of the graft, the progression of vascularisation, and any evidence of uveitis or allograft reaction.

#### CORNEAL REVASCULARISATION

In order to investigate the mechanism of graft tolerance in 6 animals whose corneal grafts had remained clear for longer than 6 months silver nitrate was applied to the corneal surface at the graft-host interface. A series of small burns were produced with a crystal of silver nitrate leaving the central graft area unaffected. The procedure was repeated after an interval of 2 days, and the animals were observed for signs of vessel reactivation and evidence of allograft rejection in the central graft area.

#### DIAGNOSIS OF THE ALLOGRAFT REACTION

The appearance of one or more of the following clinical signs was taken to indicate the onset of the allograft reaction<sup>28</sup>: (1) the clouding of a part or all of the corneal stroma in a graft which had previously been clear; (2) epithelial rejection line; (3) endothelial rejection line.

Graft survival was then recorded in days from the date of surgery until the first day on which any of these signs appeared. Usually the progression of the allograft reaction was observed for a few days in order to confirm the diagnosis before the animal was killed. The whole eye was then removed and placed in 10% formal saline.

#### HISTOLOGICAL METHODS

After fixation the globes were opened either parallel to the antero-posterior axis to provide sections of the whole eye, or, more usually, the anterior segment alone was processed. Sections of paraffin-embedded material cut so as to include the limbal and central margins of the eccentrically located graft were stained with haematoxylin and eosin and by the periodic acid-Schiff sequence. In 2 instances in which punctate opacities were observed in the donor cornea frozen sections were prepared for the demonstration of lipid by means of oil red O and Sudan black stains.

#### CYCLOSPORIN-A

A number of rabbits in the study were treated on a coded basis with either intramuscular CyA for 2 weeks (18 rabbits) or CyA 1% in arachis oil applied topically to the recipient eye 5 times daily for an initial period of 4 weeks (30 rabbits). In the intramuscularly treated group 8 rabbits received a dosage of 25 mg/kg for 2 weeks, as this dose had been used in previous studies.<sup>22,23</sup> This was later reduced to 15 mg/kg in the remainder of the group in an attempt to minimise side effects. In the topically treated group 9 rabbits continued treatment for a total of 13 weeks, but on a reducing dosage (twice daily for 5 weeks then once daily for 4 weeks). Out of the control group (33 rabbits) 14 rabbits received topical arachis oil drops 5 times daily, thus acting as a simultaneous control group for those animals receiving topical CyA in a fully coded trial.

#### EXCLUSION FROM RESULTS

Nineteen out of 88 rabbits were excluded from the

Table 1 *Surgical factors leading to exclusion from results in 19 out of 88 rabbits undergoing penetrating keratoplasty*

	No. of rabbits
Flat anterior chamber	7
Endothelial damage	3
Lens damage	3
Postoperative hyphaema	2
Anaesthetic deaths	2
Infected graft	1
No iris adhesions	1

Table 2 *Late deaths occurring in 9 out of 69 rabbits undergoing penetrating keratoplasty according to type of graft and treatment*

Group (total rabbits in group)	No. of deaths	% Deaths/group
Autografts (7)	—	0
Allografts—controls (25)	1	4%
Allografts—topical CyA (24)	2	8.4%
Allografts—systemic CyA (13)	6	46.2%

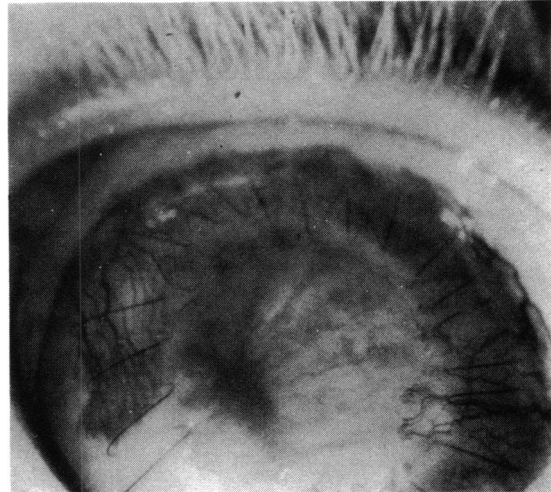


Fig. 2 *Rabbit allograft (day 14) showing a clear graft with ingrowing vessels around suture line.*

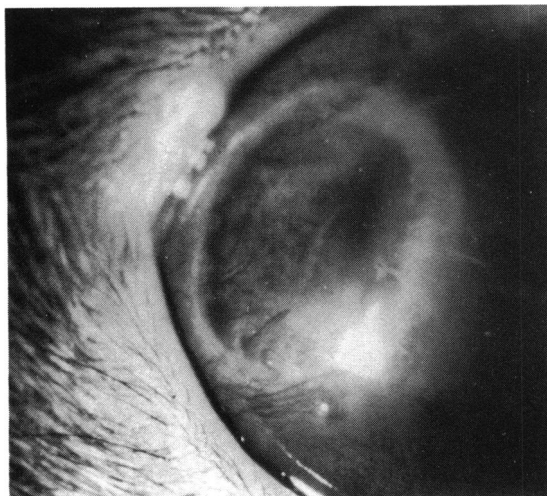
analysis of results because of complications in the immediate postoperative period (Table 1) and 9 rabbits because they failed to survive to a point where their grafts underwent rejection (Table 2).

#### Results

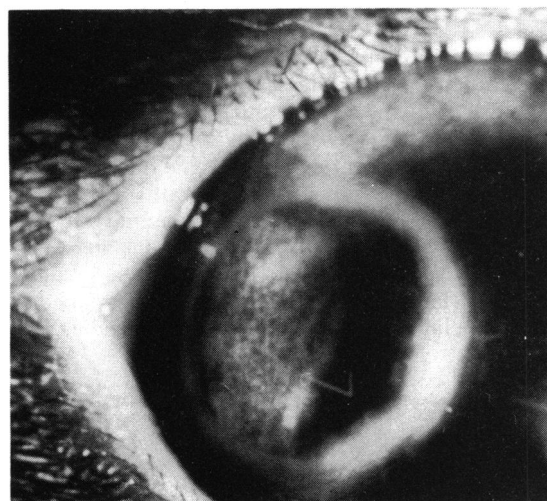
All allografts in the control groups (including those that had received topical arachis oil to the recipient eye) underwent rejection. In the groups treated with CyA the onset of rejection was delayed in 24 animals and failed to occur in the remaining 5 after 180 days. The autografted group retained clear grafts for periods longer than 6 months. These results are described below.

#### CLINICAL COURSE

After transplantation all grafts cleared between the first and seventh day except in the part which was adjacent to the site of iris/graft adhesions. These involved between 90° and 180° of the circumference of the graft lying closest to the limbus. In addition a rim of oedema persisted along the suture line in the donor and host cornea. This oedema was thought to be related to retraction of Descemet's membrane or to endothelial trauma at the time of surgery. Superficial vessels started to grow from the limbus and reached the graft/host interface by the end of the first week, after which they progressed around and into the graft. By the time of the removal of the suture on the 14th postoperative day they usually involved three-quarters of the graft's circumference (Fig. 2). Deeper vessels arising from the iris also invaded the graft to a lesser degree.



3a



3b

Fig. 3 Rabbit autograft (the same animal as Fig. 1) showing (a) a clear graft with vascular ingrowth (day 18) and (b) a clear graft with scar tissue at the graft/host interface and complete regression of vessels (day 46).

In those animals undergoing autografts or allografts treated with CyA, after the removal of the suture vessels continued to grow around the host/graft interface where some residual oedema persisted (Fig. 3a). Then during the third and fourth weeks the vessels gradually became less active and by the fifth or sixth week were visible only as 'ghost' vessels (Fig. 3b). This complete regression of vessels was not observed in the control groups, as the rejection process supervened during this period.

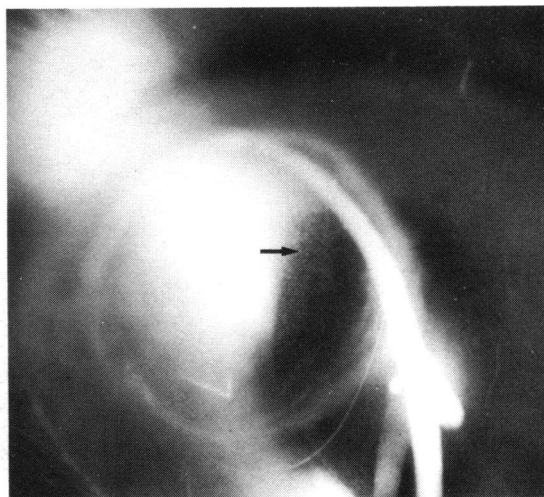


Fig. 4 Rabbit autograft (day 44) viewed with slit illumination showing superficial stromal punctate opacities (arrowed) in an otherwise clear graft.

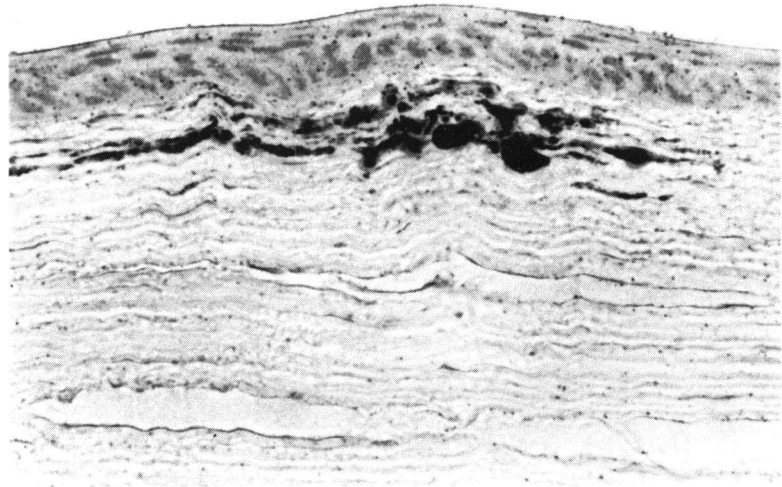
A small number of rabbits developed collections of punctate opacities close to ingrowing vessels in the superficial stroma of an otherwise clear cornea. These later tended to coalesce and assume a refractile appearance, suggesting the presence of lipid. They were not thought to represent any part of the immune reaction, because they occurred in both host and graft and, in 2 cases, in autografted rabbits (Fig. 4). Histologically several small extracellular deposits of lipid were demonstrable in appropriately processed sections of the donor cornea immediately beneath the epithelium (Fig. 5). There was no sign of leucocytic infiltration, and the lipid was presumed to have originated from the adjacent intracorneal blood vessels.

The histology of all the autografted corneas showed healing, with negligible scar tissue formation and no retrocorneal fibrosis. Corneo-irideal adhesions were apparent in 5 of the animals, with some residual vascularisation in one, but there was no leucocytic infiltration, and the donor epithelium, stroma, and endothelium appeared healthy in every instance. There was therefore no evidence of rejection in any of the autografted animals.

#### ALLOGRAFT REACTION

All 3 clinical features by which the allografts reaction may be recognised in corneal grafts<sup>28</sup> were observed in each group of allografts (Table 3). The process of rejection seen in this series of allografts appeared to correspond almost exactly with previous descriptions of the allograft reaction in various corneal layers.<sup>28</sup>

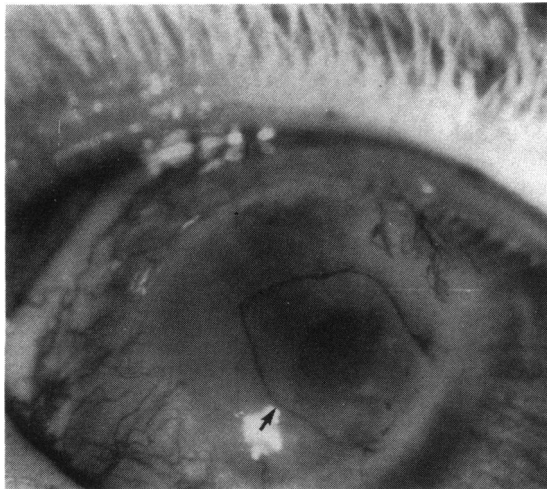
**Fig. 5 Rabbit autograft.** Immediately deep to the epithelium in the grafted cornea there are small extracellular deposits of lipid. (Frozen section: oil red O and haematoxylin,  $\times 385$ ).



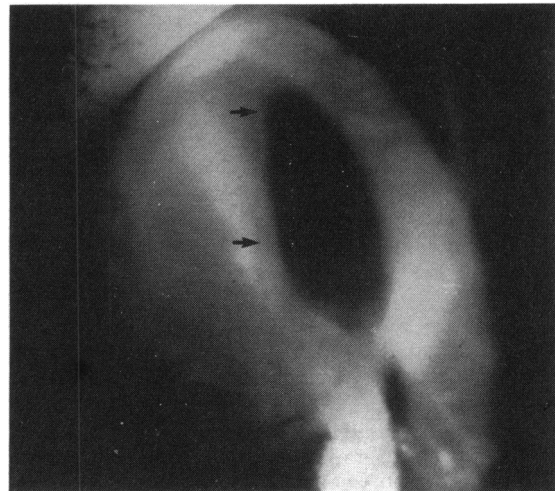
**Table 3** Types of corneal graft rejection seen in 60 rabbits undergoing penetrating keratoplasty

Group	Rejection			No rejection
	Graft oedema	Endothelial rejection	Epithelial rejection	
Autograft	—	—	—	7
Allograft (Control)	13	2	9	—
Allograft (Top.CyA)	4	6	7	5
Allograft (Syst.CyA)	1	3	2	1
Total	18	11	18	13

Graft rejection always started near invading blood vessels, usually at the site of maximal vascularisation, and progressed into previously clear cornea. In any one corneal layer the rejection process was usually established in the whole graft within 7 days of its onset, although in those animals treated with CyA the process took up to 14 days. Epithelial rejection lines could progress rapidly across the graft (Fig. 6) with only minimal disturbance in the anterior stromal layers, but this was then followed about one week later by the appearance of stromal or endothelial rejection (Fig. 7). Where the reaction was confined to the epithelium and anterior stroma, no evidence of



**Fig. 6** Rabbit allograft (day 38) treated with topical CyA drops from day 0 to day 28 showing advancing epithelial rejection line stained with methylene blue (arrowed).



**Fig. 7** Rabbit allograft (day 81) treated with topical CyA drops from day 0 to day 91 showing endothelial rejection line (arrowed) viewed partly by retroillumination.

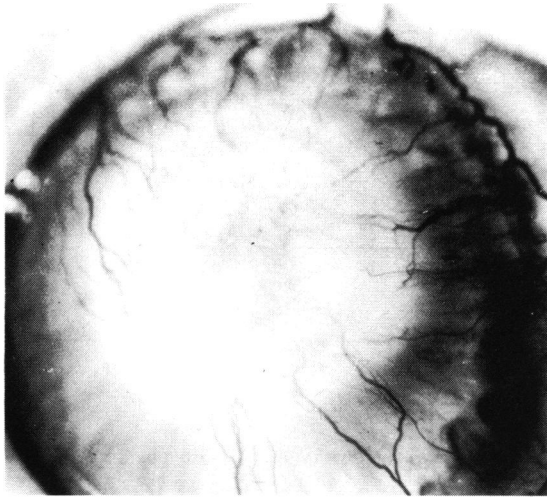


Fig. 8 Rabbit allograft (the same untreated control animal shown in Fig. 2) showing total rejection with opacification and complete vascularisation of the graft (day 28).

uveitis was seen. Even in those cases that developed endothelial rejection lines only a few cells were seen in the anterior chamber. Eighteen out of 60 clear grafts developed diffuse graft oedema (Fig. 8)

without endothelial or epithelial rejection lines, and this appearance was subsequently confirmed as being due to the allograft reaction on histopathological grounds.

On histological examination stromal vascularisation was observed in most control animals (21 of 24 eyes) and was best seen on the limbal side of the graft, where there was cornea-irideal adhesion. Inflammatory cell infiltration, mainly in the form of lymphocytes and plasma cells with a few neutrophil polymorphonuclear leucocytes, was associated with the vascular incursions and was a feature of all specimens. Scar tissue proliferation extending from the deep surface to create limited retrocorneal fibrosis at the graft margins was observed in half the specimens. Attenuation and loss of the endothelium of variable extent with attendant stromal swelling were present in slightly more than half the specimens (Fig. 9). Keratic precipitates consisting of mononuclear cells were seen in most corneas showing endothelial damage. Epithelial atrophy was apparent in the grafted corneas of most animals. All grafts in the untreated control group showed signs of immunological rejection.

All grafts in the control group underwent rejection by the 34th day, with the first graft being rejected on the 8th postoperative day (Figs. 10 and 11). The mean

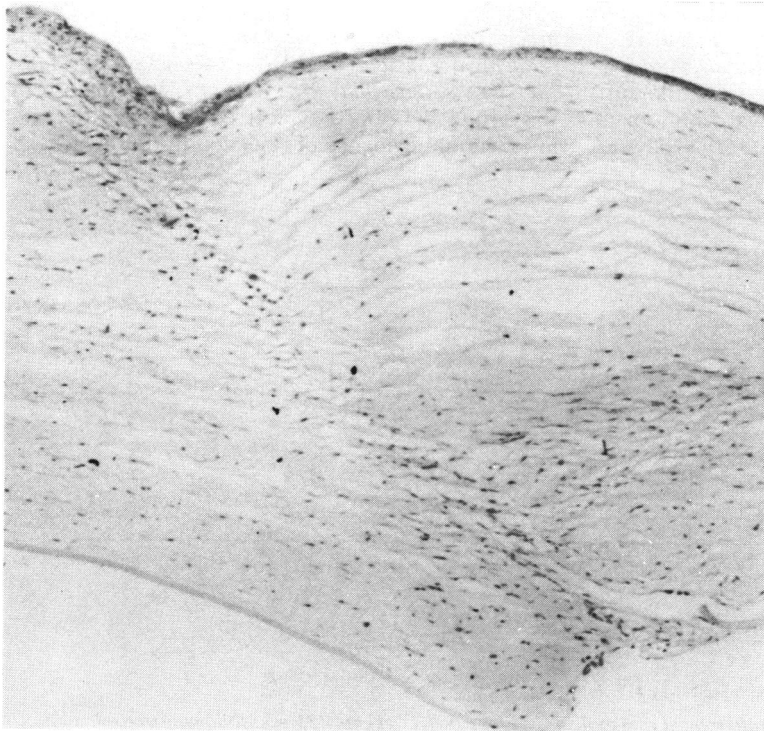


Fig. 9 Graft-host interface displaying absence of endothelium on Descemet's membrane of the donor tissue and a little leucocytic infiltration of the graft margin. (Haematoxylin and eosin,  $\times 107$ ).



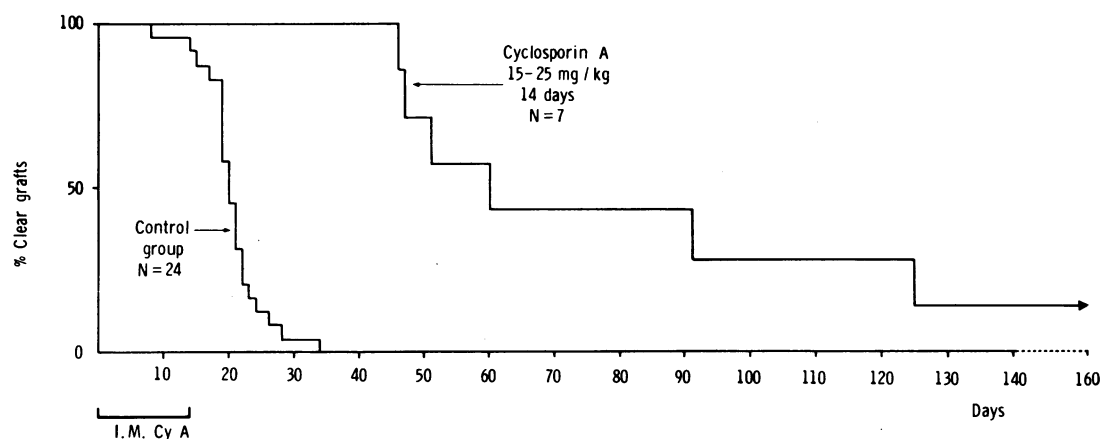


Fig. 10 Survival of rabbit corneal allografts treated with intramuscular CyA for 14 days following transplantation.

survival time of grafts in this group was  $20.78 \pm SD 4.80$  days. The earliest rejection occurred in a New Zealand white rabbit, in which rapid vascularisation of the graft was quickly followed by the appearance of an epithelial rejection line on the eighth post-operative day. No difference was found between Dutch and New Zealand white rabbits concerning the time or rate of rejection.

#### CYCLOSPORIN-A

The survival rates of 3 groups of corneal allografts treated with CyA are shown in the Figs. 10 and 11.

(a) Seven rabbits treated with Intramuscular CyA (15-25 mg/kg) for 2 weeks. Six of the 7 allografts showed a prolonged period of survival with a mean survival time of 98 days compared with 20.78 days for

the control group. ( $p < 0.001$ ). One graft in this group remained clear at 180 days (Fig. 10).

(b) Thirteen treated with topical CyA 1% in arachis oil to the recipient eye 5 times daily for 4 weeks. The first allograft in this group was rejected on day 31, 3 days after stopping treatment (Fig. 6), and the remainder had all been rejected by day 77, with a mean survival time of  $47.31 \pm 12.56$  days. Compared with the control group this gave a p value of  $< 0.001$  (Fig. 11).

(c) Nine rabbits treated with topical CyA 1% in arachis oil to the recipient eye for 13 weeks with a reducing dosage (5 times daily for 4 weeks, twice daily for 5 weeks, once daily for 4 weeks). Two allografts in this group developed typical endothelial rejection lines without evidence of rejection in the superficial

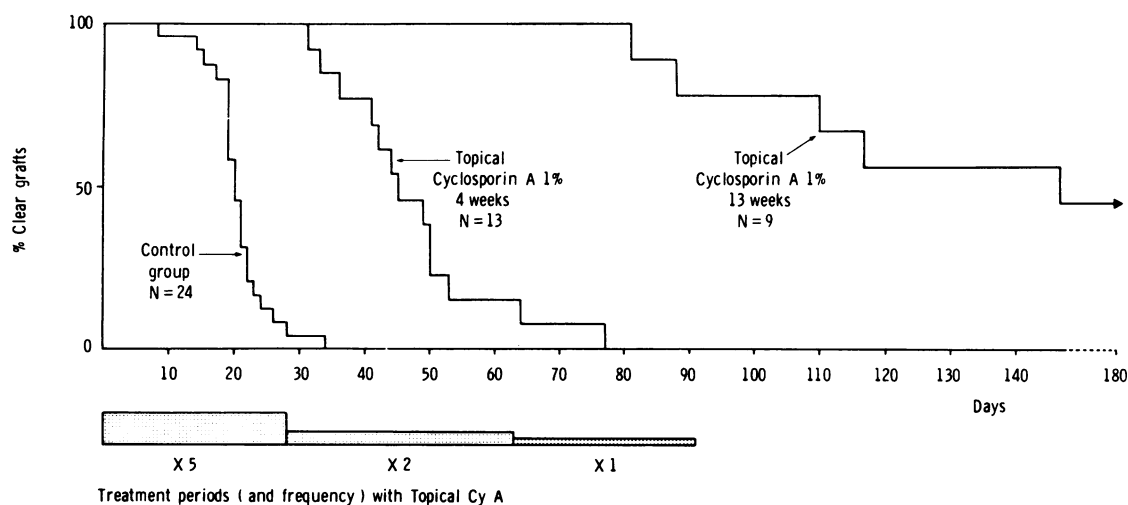


Fig. 11 Survival of rabbit corneal allografts treated with topical CyA for either 4 weeks or 13 weeks following transplantation.

stroma or epithelium before treatment was stopped (Fig. 7). These developed on days 81 and 88 respectively, more than 2 weeks after the treatment had been reduced from twice to once daily. Of the remaining 7 rabbits 3 rejected the grafts (days 110, 117, and 147), while the others remained clear for more than 180 days (Figs. 11 and 12).

On histological examination all animals killed after treatment with CyA for the prescribed period showed signs of rejection manifested by endothelial cell loss, stromal swelling, and reduced thickness of the epithelium. Leucocytes were conspicuous at the graft margins in virtually every case, and in most instances inflammatory cells with newly formed blood vessels had spread into the donor tissues (Fig. 13). There was no evidence of surgical failure, the graft margins being fully healed in all specimens.

#### EFFECT OF CORNEAL REVASCULARISATION ON GRAFT SURVIVAL

Six animals which had maintained clear corneal grafts for longer than 6 months had their corneas revascularised by means of silver nitrate. The group consisted of 1 autograft, 1 allograft treated with intramuscular CyA 15 mg/kg, and 4 allografts which had been treated with topical CyA for 13 weeks. All corneas initially developed mild central graft oedema which cleared within a few days, associated with marked vessel reactivation in the host and graft stroma.

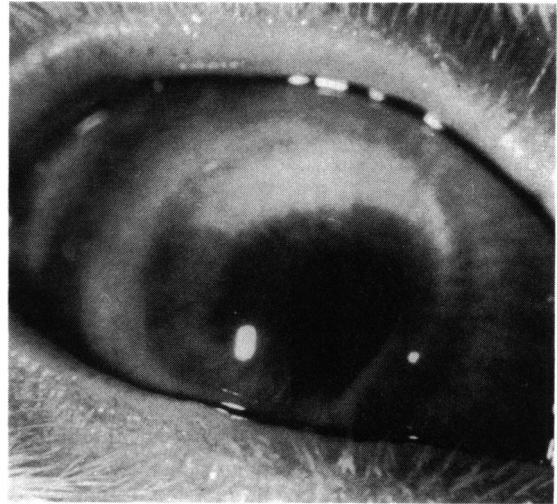


Fig. 12 Rabbit allograft (day 150) showing a clear graft following treatment with topical CyA from day 0 to day 91.

The autograft remained clear. The allograft which had been treated with systemic CyA developed a typical allograft reaction on the 12th day. Three out of the 4 allografts treated with CyA developed allograft reactions on the 14th, 24th, and 30th days, while the fourth developed a sustained inflammatory response lasting 5 weeks, though it later settled leaving a clear graft.

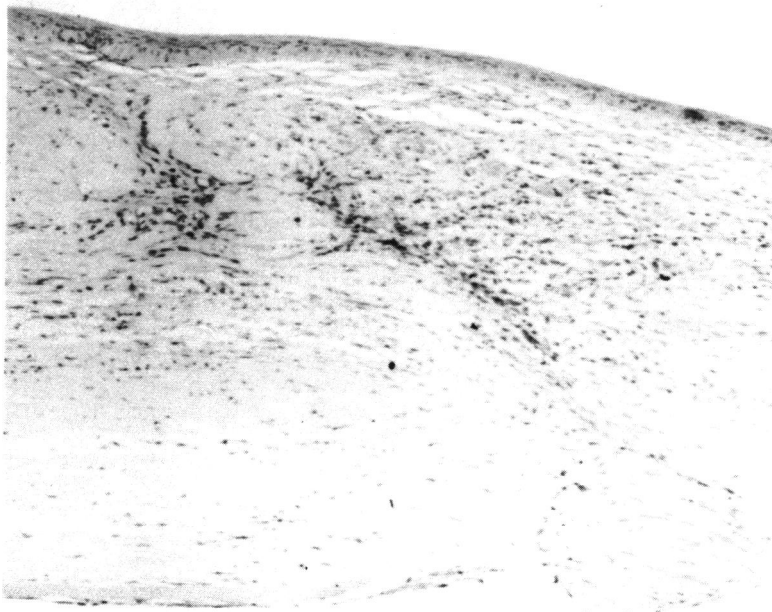


Fig. 13 Graft-host interface showing vascularisation and leucocytic infiltration of the stroma associated with graft rejection. The donor stroma (on the left) is swollen and the donor endothelium is atrophic. (Haematoxylin and eosin,  $\times 107$ ).



## SIDE EFFECTS OF CYCLOSPORIN A

(a) *Intramuscular CyA 15–25 mg/kg*. Nine out of 11 rabbits surviving for longer than 2 weeks lost weight, and the mean weight loss for the whole group during the first 2 weeks was 0.19 kg. All other groups of animals over the same period had mean weight gains which were as follows: autografts +0.175 kg, allografts (controls) +0.22 kg, allografts (treated with topical CyA) +0.07 kg. Although this weight loss was not statistically significant, it was a notable clinical feature of the animals treated systemically during the first 2–3 weeks. After stopping CyA treatment the rabbits later regained their initial weight by about the 5th week.

In the group overall, 6 out of 13 died before their grafts were rejected (Table 2), though one was killed for reasons that could not be related to the drug. The 5 deaths (42.6%) occurred on days 14, 15, 27, 35, and 83 among animals receiving both high (2 rabbits) and low (3 rabbits) dosages. The greater death rate in this group compared with controls and topically treated groups was significant ( $0.05 > p > 0.01$ , *t* test).

(b) *Topical CyA 1%*. Two out of 24 (8.3%) rabbits died before their grafts underwent rejection, which when compared with 1 death in the control group (4%) was not significant (Table 2). One death in the topically CyA-treated group was associated with a 2-day episode of diarrhoea occurring 10 days after treatment was stopped (day 38), and the other death occurred on day 25.

All rabbits in the groups treated with either topical CyA in arachis oil or arachis oil alone lost varying amounts of fur round the treated eye (Fig. 14). This fur loss appeared after about one week and remained while treatment was continued. However, within 4–5 days of stopping treatment the fur started to regrow in all cases. Conjunctival changes were confined to mild hyperaemia of the bulbar and palpebral conjunctiva in rabbits treated with both arachis oil alone and CyA 1% in arachis oil.

## Discussion

Although many possible mechanisms for the development of the corneal allograft reaction in man have been proposed,<sup>29</sup> the exact routes by which rejection may be brought about has not yet been established. Systemic mechanisms may be important in circumstances where the possibility of presensitisation by transplantation (HLA system) antigens exists, for example, from previous corneal grafts, pregnancy, or blood transfusions.<sup>30 31</sup> The role of the blood group antigens (ABO system), however, is less clear, and they would certainly not appear to represent a major factor in clinical corneal allograft rejection.<sup>32 33</sup> As a means of studying such 'second set' allograft

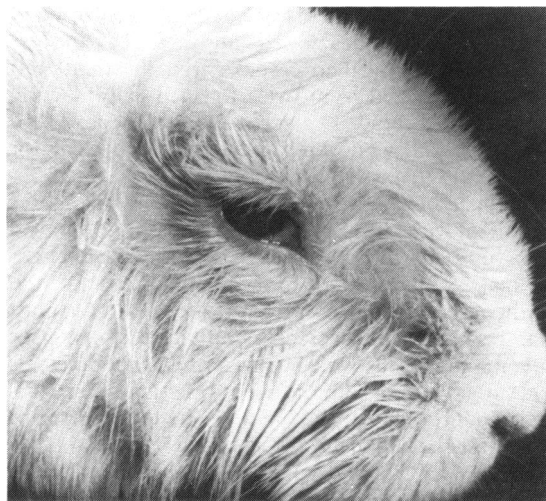


Fig. 14 Loss of fur around eye of New Zealand white rabbit treated for 4 weeks with arachis oil drops 5 times daily for 4 weeks (day 28).

reactions animal model utilising additional methods of sensitisation have been widely practised, yielding much valuable information.<sup>16 17 21–25</sup>

However, clinical corneal allograft reactions frequently occur where sensitisation would appear to have resulted only from the transfer of corneal tissue following a first graft, and to date no satisfactory 'single set' animal model has been reported. Animal models involving xenografts may induce morphological changes in lymph nodes throughout the body of a rabbit, whereas allografts in the same animal would appear to produce local lymphoid changes only.<sup>34</sup> There may therefore be fundamental differences between rejection of a xenograft and allograft, which makes comparison of xenograft models with clinical allografting difficult. Corneal allograft rejection by a 'single set' mechanism has been demonstrated in rabbits by means of lamellar grafts, but it was found that only 48% of grafts underwent rejection over a period of 2–6 weeks.<sup>35</sup> In another 'single set' model of allograft rejection involving penetrating grafts 72% of grafts took between 2 and 12 weeks to undergo rejection, leaving 28% unrejected at the end of this period.

The present model has several advantages over previous models. Firstly, 100% of untreated grafts were rejected over a period of 1–5 weeks, with a mean survival time of  $20.78 \pm \text{SD } 4.80$  days. As ingrowing vessels normally take 5–7 days to reach the graft, this may indicate that the model is a more severe immunological challenge than previous systems. Secondly, rejection appears to occur as a

result of a 'single set' allograft reaction, making it a closer analogue of the majority of clinical corneal graft rejections. Thirdly, it has been suggested that local immune mechanisms may be responsible for all or a substantial part of corneal allograft reactions,<sup>29, 36</sup> and these might be altered by the local use of immunosuppressive agents. The effects of the topical use of such agents might not be observed where a model depended on additional distant sites of sensitisation. Thus, when CyA was administered topically in a 'second set' model in which it was known to be effective systemically, it failed to prevent graft rejection,<sup>25</sup> yet when applied topically to the grafted eye in our 'single set' model it was able to inhibit rejection.

The ability of CyA to inhibit graft rejection when applied topically to the recipient eye for 4 weeks has already been reported, and these results have been discussed elsewhere.<sup>36</sup> In the present experiments graft survival was further prolonged by continuing the drug for a period of 13 weeks, though the fact that 2 grafts underwent rejection while still on therapy may suggest that the treatment frequency was reduced prematurely. Even so, 44% of grafts remained clear for periods of over 3 months after treatment was stopped. It is possible that specific immunological tolerance may be induced by CyA, as has been suggested by work in other organ transplantation models.<sup>37</sup> However, in this model, when the experiment was carried out to produce reactivation of the corneal blood vessels, 4 out of 5 allografts rapidly developed typical corneal rejection in spite of previous treatment with CyA. It would therefore appear that the most important factor in producing graft tolerance in this model was the regression of the corneal vessels while CyA treatment was maintained, during which time the relative immunological privilege of the cornea was restored.

No side effects that could be attributed to topical CyA were found. The previously reported<sup>25, 38</sup> transient loss of fur that occurred round the eyes of treated rabbits was found to be due to irritation by the arachis oil and subsequent scratching by the rabbit. By contrast with the rabbits treated with systemic CyA, which showed weight loss and a significantly increased death rate, the results to date indicate that topical CyA appears to be a safe drug, though this needs to be fully established by further detailed investigation.

It is hoped that the ability of topically applied CyA to inhibit corneal allograft rejection in a single-set rabbit model will enable clinical trials to begin shortly.

#### References

- 1 Darwin E. *Zoonomia or the Laws of Organic Life*. 1796: 2.
- 2 Reisinger F. *Baiersche Annalen fuer Abhandlungen, Erfindungen und Beobachtungen aus dem Gebiete der Chirurgie, Augenheilkunst und Geburtshuelfe*. Salzabech: 1824: 1: Ch. 15: 207-15.
- 3 Bigger SL. An inquiry into the possibility of transplanting the cornea with the view of relieving blindness (hitherto deemed incurable) caused by several diseases of that structure. *Dublin Journal of Medical Sciences* 1837; 11: 408-47.
- 4 Power H. On transplantation of the cornea. *Proceedings of IVth International Ophthalmological Congress 1872*. London: 1873: 172-6.
- 5 Tudor-Thomas JW. Transplantation of the cornea: a preliminary report on a series of experiments on rabbits, together with a demonstration of four rabbits with clear corneal grafts. *Trans Ophthalmol Soc UK* 1930; 50: 127-41.
- 6 Castroviejo R. Keratoplasty-microscopic study of corneal grafts. *Trans Am Ophthalmol Soc* 1937; 35: 355-85.
- 7 Stansbury F, Wadsworth JA. Corneal transplantation in rabbits. *Am J Ophthalmol* 1947; 30: 968-78.
- 8 Babel J, Bourquin JB. Experiment research with corneal heterografts. *Br J Ophthalmol* 1952; 36: 529-36.
- 9 Greaves DP. Experimental penetrating keratoplasty. *Trans Ophthalmol Soc UK* 1954; 74: 135-44.
- 10 Khoudadhoust AA. Penetrating keratoplasty in the rabbit. *Am J Ophthalmol* 1968; 66: 899-905.
- 11 Khoudadhoust AA. Lamellar corneal transplantation in the rabbit. *Am J Ophthalmol* 1968; 66: 1111-7.
- 12 McEntyres JM. Experiment penetrating keratoplasty in dogs. *Arch Ophthalmol* 1968; 80: 72-6.
- 13 Polak FM. *Corneal Transplantation*. New York: Grune and Stratton, 1977: Ch. 1: 3-11.
- 14 Billingham RE, Boswell T. Studies on the problem of corneal homografts. *Proc R Soc Lond (Biol)* 1953; 41: 392-406.
- 15 Paufigue L, Sourdille GP, Offret G. *Les Greffes de la Cornee*. Paris: Masson, 1948: 258-9.
- 16 Maumenee AE. The influence of donor-recipient sensitisation on corneal grafts. *Am J Ophthalmol* 1951; 34: 142-52.
- 17 Khoudadhoust AA, Silverstein AM. Local GVH reactions within the anterior chamber of the eye: the formation of corneal endothelial pocks. *Invest Ophthalmol Visual Sci* 1975; 14: 640-7.
- 18 Khoudadhoust AA, Silverstein AM. Studies on the nature of privilege enjoyed by corneal allografts. *Invest Ophthalmol Visual Sci* 1972; 11: 137-48.
- 19 Lorenzetti DWC, Kaufman HE. Experimental production of graft reactions with suppression by topical steroids. *Arch Ophthalmol* 1966; 76: 274-81.
- 20 Basu PK. Studies on the mechanism of corneal graft reaction using simplified systems. *Proceedings of the 2nd International Corneo-plastic Conference, 1967*. Oxford: Pergamon, 1969: 163-72.
- 21 Polak FM. Effect of azathioprine (Imuran) on corneal graft reaction. *Am J Ophthalmol* 1967; 64: 233-44.
- 22 Polak FM. Inhibition of immune corneal graft rejection by azathioprine (Imuran). *Arch Ophthalmol* 1965; 74: 683-9.
- 23 Fleming JC, Reid FR, Wood TO. Prevention of immune graft rejection after corneal transplantation. *Am J Ophthalmol* 1979; 88: 97-101.
- 24 Coster DJ, Shepherd WFI, Chin-Fook T, Rice NSC, Jones BR. Prolonged survival of corneal allografts in rabbits treated with cyclosporin A. *Lancet* 1979; ii: 688-9.
- 25 Shepherd WFI, Coster DJ, Chin Fook T, Rice NSC, Jones BR. Effect of cyclosporin-A on the survival of corneal grafts in rabbits. *Br J Ophthalmol* 1980; 64: 148-53.
- 26 Editorial. *Lancet* 1979; ii: 779-80.
- 27 Markwick JR, Chamber JD, Hobbs JR, Pegrum GD. Timing of cyclosporin-A therapy for abrogation of HVG and GVV responses in rats. *Lancet* 1979; ii: 1037.
- 28 Silverstein AM, Khoudadhoust AA. Transplantation immunobiology of the cornea. In: *Corneal Graft Failure*. CIBA Foundation Symposium; Amsterdam: Associated Scientific Publishers, 1973: 105-25.

- 29 Jones BR. Present knowledge and problems of corneal graft failure. In: *Corneal Graft Failure*. CIBA Foundation Symposium. Amsterdam: Associated Scientific Publishers. 1973: 349-54.
- 30 Stark WJ, Taylor HR, Bias WB, Maumenee AE. Histocompatibility (HLA) antigens and keratoplasty. *Am J Ophthalmol* 1978; **86**: 595-604.
- 31 Ehlers N, Ahrons S. Corneal transplantation and histocompatibility. *Acta Ophthalmol (Kbh)* 1971; **49**: 513-27.
- 32 Foster CS, Allansmith MR. Lack of blood group antigen A on human corneal endothelium. *Am J Ophthalmol* 1979; **87**: 165-70.
- 33 Salisbury JD, Gebhardt BM. Blood group antigens on human corneal cells demonstrated by immunoperoxidase staining. *Am J Ophthalmol* 1981; **91**: 46-50.
- 34 Polack FM. Corneal graft rejection: clinico-pathological correlation. In: *Corneal Graft Failure*. CIBA Foundation Symposium. Amsterdam: Associated Scientific Publishers. 1973: 130.
- 35 Khoudadoust AA, Silverstein AM. The survival and rejection of epithelium in experimental corneal transplants. *Invest Ophthalmol Visual Sci* 1969; **8**: 169-79.
- 36 Hunter PA, Wilhelmus KR, Rice NSC, Jones BR. Cyclosporin-A applied topically to the recipient eye inhibits corneal graft rejection. *Clin Exp Immunol* 1981; **45**: 173-7.
- 37 Green CJ, Allison AC, Precious S. Induction of specific tolerance in rabbits by kidney allografting and short periods of cyclosporin-A treatment. *Lancet* 1979; **ii**: 123-5.
- 38 Coster DJ. Factors affecting the outcome of corneal transplantation. *Ann R Coll Surg Engl* 1981; **63**: 91-7.