

Irreversible visual loss in Waldenström's macroglobulinaemia

EDGAR L. THOMAS, R. JOSEPH OLK, MAURIE MARKMAN,
HAYDEN BRAINE, AND ARNALL PATZ

From the Retinal Vascular and Oncology Centers, The Johns Hopkins Hospital, 600 North Wolfe Street, Baltimore, Maryland 21205, USA

SUMMARY A patient with Waldenström's macroglobulinaemia presented with visual reduction in both eyes. The fundusoscopic and angiographic demonstrations of venous engorgement ('string of sausages'), retinal haemorrhages at all levels, retinal and disc oedema, and serous detachment of the maculas were consistent with this diagnosis. The cryoprecipitation of the immunoglobulin at a temperature slightly below body temperature precluded routine blood studies and plasmapheresis. Plasmapheresis was ultimately performed without difficulty with the patient and equipment at 88°F (31°C). Despite marked improvement in the fundusoscopic and angiographic appearance of the retina, perfoveal capillary nonperfusion and serous elevation of the macula persisted. Even when the maculas flattened in both eyes, no visual recovery occurred. Early diagnosis, even on a clinical basis when laboratory studies cannot be performed, and early plasmapheresis to reduce serum viscosity are warranted to prevent intravascular occlusion in the perfoveal capillary bed, deposition of immunoglobulin in the retina, and transudation in the subretinal space.

Intravascular hyperviscosity in Waldenström's macroglobulinaemia produces a pattern of retinal changes including increased diameter and 'string of sausages' appearance of the retinal veins; dot, blot, and flame-shaped haemorrhages; retinal and disc oedema; and serous retinal detachment.¹⁻⁶ Fluorescein angiography shows microvascular changes such as the formation of microaneurysms, especially in the perfoveal area, and discrete areas of capillary nonperfusion.²

The high intravascular concentration of IgM (molecular weight 600 000 to 1 000 000) is produced by a single B-cell line, and accounts for the elevated intravascular volume that dilates the venous and capillary beds of the retina.³ Retinal haemorrhages and oedema result from compromise of the retinal microvasculature and platelet dysfunction produced by coating with IgM.⁷ This immunoglobulin may also cryoprecipitate, making laboratory determinations and therapeutic plasmapheresis technically difficult.

This report describes a patient with Waldenström's macroglobulinaemia and cryoglobulin formation.

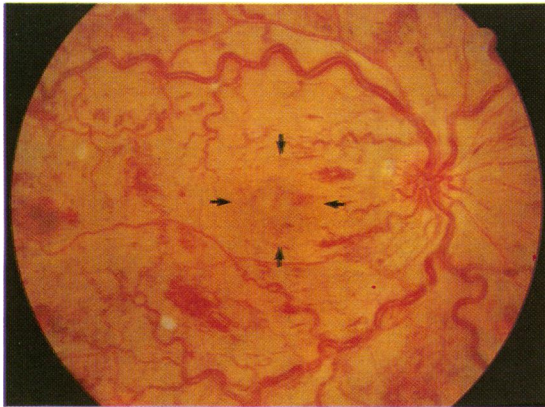
Accurate diagnosis and treatment were hindered by rapid cryoprecipitation of this patient's whole blood at room temperature; the delay resulted in bilateral capillary closure in the perfoveal zone and chronic serous detachment of the maculas. Visual recovery did not occur after innovative plasmapheresis, which reversed all the retinal changes except capillary nonperfusion in the perfoveal area and pigmentary atrophy under the areas of previous serous macular detachments.

Case report

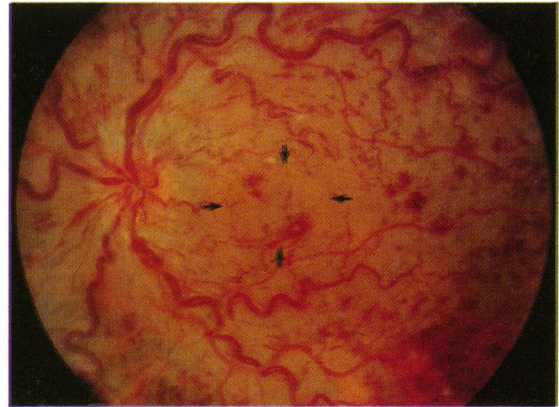A 48-year-old black male was admitted to the Johns Hopkins Oncology Center in January 1981 for the evaluation of serum hyperviscosity. The patient had noted increasing weakness, dizziness, and recurrent epistaxis in the 6 months prior to admission. Investigation of the bleeding at another hospital demonstrated an IgM kappa monoclonal immunoglobulin. Aspirin and Persantine (dipyridamole) were prescribed. The patient continued to experience intermittent bleeding and noted progressive blurring of vision, as well as occasional headaches.

When he was first seen in the Retinal Vascular

Correspondence to Edgar L. Thomas, MD, LSU Eye Center, 136 South Roman Street, New Orleans, LA 70112, USA.



1A



1B

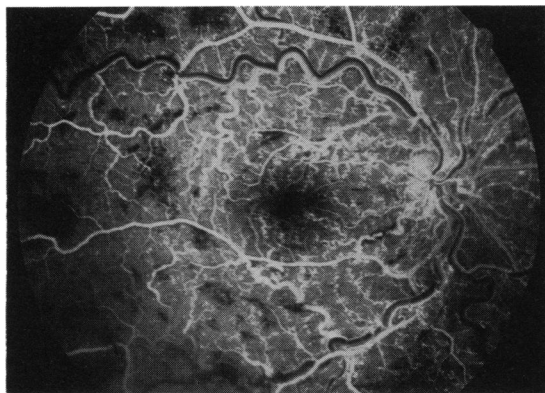
Fig. 1A Severe venous engorgement with diffuse retinal and disc oedema, flame-shaped and dot, blot haemorrhages, with a shallow serous detachment of the macula (borders marked with arrows). Right eye, January 1980. B Similar fundus changes with a less discrete serous elevation of the macula (borders marked by arrows). Left eye, January 1981.

Center at the Wilmer Institute, the best corrected visual acuity was 7/200 in the right eye and 5/200 in the left eye. The anterior segment and vitreous were normal. Fundus examination showed venous engorgement, 'sausaging' of veins, retinal haemorrhages at levels within the retina, oedema of the disc and retina, and serous detachment of the macula (Fig. 1A,B). Fluorescein angiography highlighted the venous and capillary bed abnormalities, especially microaneurysm formation and perfoveal nonperfusion. (Figs. 2A,B). Outside of the posterior pole, similar changes were more severe focally (Fig. 3).

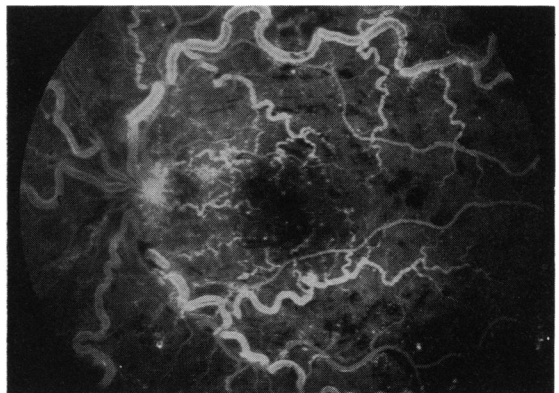
The patient had hypertension, and the liver, spleen, and several lymph nodes were enlarged. It was impossible to evaluate haematological or biochemical

parameters because the patient's blood was too viscous to be analysed. Subsequently, the patient's paraprotein was determined to be a cryoglobulin. A lymph node biopsy was nondiagnostic, but a bone marrow biopsy revealed focal aggregates of lymphocytes consistent with Waldenström's macroglobulinaemia.

Initial attempts at phlebotomy and replacement with saline did not improve the patient's symptoms. Subsequently he underwent plasmapheresis in his hospital room, which was heated to 88°F (31°C) in an attempt to prevent agglutination of the blood in the machine. The first serum viscosity that could be measured (2 February 1981) was 7.8 (normal 1.4–1.8) (see Table 1 footnote for meaning of these measure-



2A



2B

Fig. 2A Fluorescein angiogram shows moderate numbers of microaneurysms, diffuse capillary bed dilatation, and an increase in the size of the capillary-free zone. Early fluorescein leakage at the temporal aspect of the disc is seen. Left eye, January 1980. B Microaneurysms in the perfoveal zone are more prominent with slight enlargement of capillary-free zone. Left eye, January 1981.

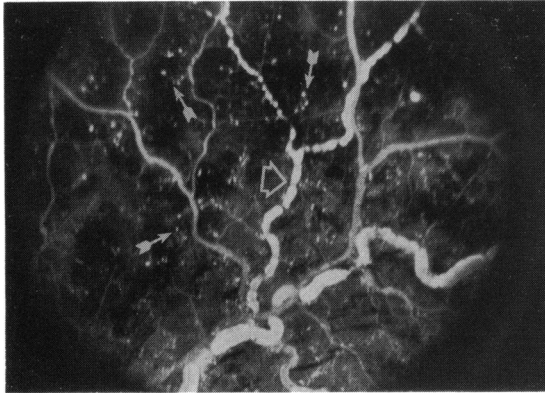


Fig. 3 Superotemporal arcade with marked venous 'sausaging' (open arrow) and moderate microaneurysm formation (closed arrows). Capillary nonperfusion is present in the areas surrounded by microaneurysms. Left eye, January 1981.

ments). After 2 sessions of plasmapheresis the viscosity decreased to 3.3 and the fluorescein arm-to-retina circulation time decreased from 22 to 13 seconds. In addition to further frequent plasmaphereses, which were performed at room temperature (Table 1), the patient was treated with cyclophosphamide and prednisone.

Five months after the start of treatment the visual acuities remained 7/200 in the right eye and 5/200 in the left eye. The severe venous changes, intraretinal haemorrhages, and disc oedema had resolved; however, persistent serous detachments of both maculas persisted (Figs. 4A,B).

Eight months after therapy the serous detachments had resolved. Persistent decreased perfusion in the perifoveal area and moderate pigmentary alterations under the previous areas of serous detachment were shown by fluorescein angiography (Figs. 5A,B). Visual acuity remained less than 20/200 in both eyes.

Discussion

A major complication of Waldenström's macroglobinaemia is the development of the hyperviscosity syndrome, characterised by fatigue, headaches, epistaxis, and visual impairment. Plasmapheresis to reduce the concentration of the circulating monoclonal IgM immunoglobulin is quite successful in relieving the symptoms and, if instituted early, in reversing visual disturbances.

This patient showed a sequence of anatomical alterations in the eye produced by intravascular hyperviscosity. Early diagnosis and management were complicated by the propensity of the macroglobulins (IgM) to cryoprecipitate within seconds at a

Table 1 Serum viscosity

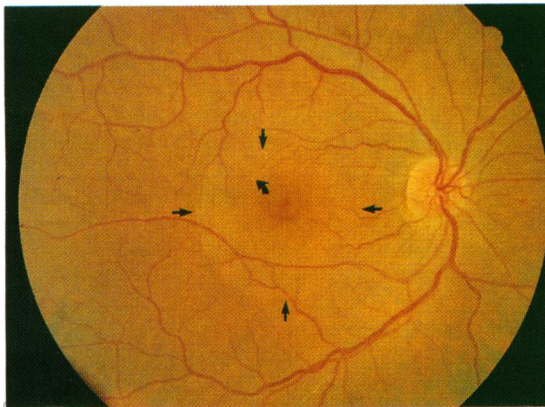
| Date (1981) of plasmapheresis | Date (1981) | Serum viscosity* |
|-------------------------------|-------------|------------------|
| At 88°C | | |
| 28 Jan. | | |
| 30 Jan. | 2 Feb. | 7.8 |
| 3 Feb. | | |
| | 4 Feb. | 3.3 |
| At room temperature | | |
| 6 Feb. | 10 Feb. | 3.4 |
| 12 Feb. | | |
| 19 Feb. | 19 Feb. | 4.0 |
| 26 Feb. | | |
| 10 Mar. | | |
| | 31 Mar. | 2.4 |
| 3 Apr. | | |
| 21 Apr. | | |
| | 28 Apr. | 2.9 |
| | 6 May | 5.3 |
| 7 May | | |
| 21 May | | |
| | 28 May | 2.4 |
| 4 June | | |
| | 9 July | 4.5 |
| 10 July | | |
| 17 July | | |
| | 29 July | 2.5 |
| 17 (2) Aug. | | |
| 3 Sept. | | |
| 10 Sept. | | |
| 17 Sept. | | |
| | 29 Sept. | 1.7 |

*Viscosity measured with the Ostwald-Viscometer relative to the viscosity of saline. Values less than 1.6 are within normal limits.

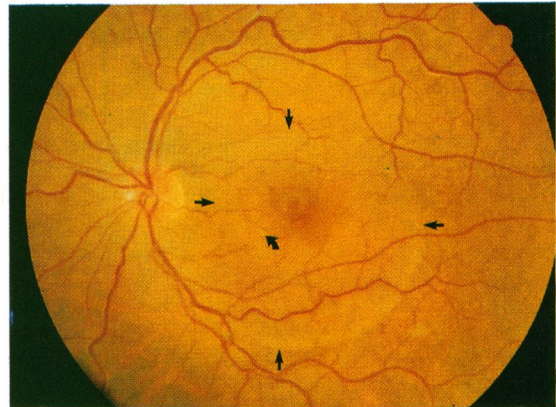
temperature slightly less than body temperature. The reduced vision and funduscopy and angiographic findings were the only criteria for diagnosis, since laboratory confirmation of increased intravascular viscosity could not be made until the patient had been subjected to plasmapheresis to remove the cryoglobulin.

Initial management with aspirin and Persantine at another hospital failed to preserve vision and may in fact have had no effect on platelet aggregation in this case, in which hyperviscosity resulted from large intravascular immunoglobulin molecules coating the platelets. When the patient was first seen at the Wilmer Institute, vision was reduced to 5/200 and 7/200 in the right and left eyes, respectively. The results of the funduscopy examination showed all of the classic findings of hyperviscosity retinopathy — 'string of sausages' change in retinal veins, haemorrhages at all levels in the retina, retinal oedema, and exudative (serous) retinal detachment.

Innovative plasmapheresis was serially performed with patient, equipment, and personnel working in a heated room with the ambient temperature above 88°F (31°C). The patient and equipment tolerated the procedure on many occasions, and ultimately enough



4A



4B

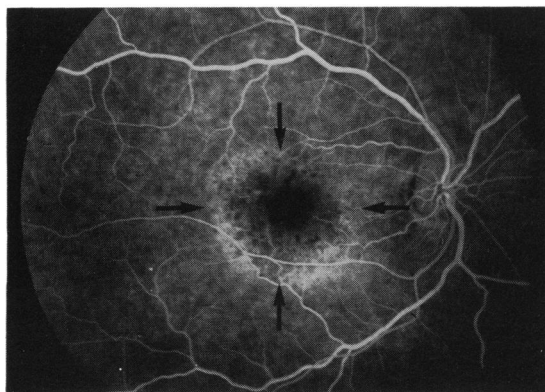
Fig. 4A Residual serous detachment of the macula (borders marked by straight arrows) persisted 4 months after plasmapheresis. Subretinal precipitates are seen (curved arrow). Right eye, April 1980. **B** Extensive serous detachment of the macula is present (borders marked by straight arrows). Subretinal precipitates are also seen (curved arrow). Left eye, April 1981.

of the intravascular cryoglobulin was removed so that further plasmapheresis could be performed at room temperature.

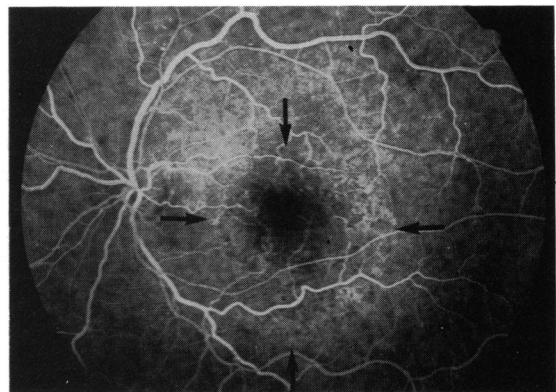
Fundusoscopic examination revealed improvement, with gradual decrease in venous tortuosity and engorgement, clearing of retinal haemorrhages, and decreased retinal oedema. Fluorescein angiography showed the same improvements, as well as clearing of almost all of the microaneurysms. The areas of non-perfusion also cleared except in the posterior pole, where persistence of an enlarged capillary-free zone was noted (Figs. 5A,B). Serous elevation of the maculas persisted for several months following clearing of the other retinal findings. Despite

flattening of the maculas with time, the patient's vision has not improved.

Several mechanisms may be responsible for the failure of visual recovery. Capillary occlusion of the perifoveal net was present on the initial fluorescein angiogram. Microvascular sludging and possible thrombosis may have begun several months prior to our examination. After plasmapheresis, with reduction of total intravascular volume and decrease in retinal oedema, no improvement in perifoveal perfusion occurred. Vascular remodelling of the macular and perimacular capillary bed has been described in sickle cell retinopathy.⁸ This retinal occlusion occurs, however, in arterioles rather than in



5A



5B

Fig. 5A Fluorescein angiography 7 months after plasmapheresis shows an area (outlined with arrows) of hyperfluorescence with atrophy of the pigment epithelium corresponding to the previous serous detachment, which has now resolved. Right eye, July 1980. **B** Resolution of serous detachment with area of decreased pigmentation (outlined by arrows). Minimal microaneurysms remain. Left eye, July 1981.

the capillary bed and venous circulation. No evidence of remodelling of the perifoveal capillary bed was found in this case. Microaneurysms were prevalent throughout the entire posterior pole in each eye. After plasmapheresis they were almost entirely absent in both eyes; apparently this microvascular change was reversible. In one report microaneurysms actually increased following plasmapheresis.² Mechanical obstruction of the capillary bed by aggregated blood components or true thrombus was apparently not reversed by plasmapheresis. Recanalisation of the thrombi did not occur.

Chronic serous detachment, though asymmetrical, was present for 5 months following plasmapheresis. This finding resembled idiopathic central serous retinopathy when the retinal vascular changes cleared and surrounding retinal and disc oedema resolved. The fluorescein angiographic examination, however, showed neither unifocal nor multifocal leaks in the pigment epithelium. Minimal late pooling of fluorescein in the serous detachment was seen. The chronicity of the detachment may have played an important role in the poor visual result in this patient. Prolonged serous detachment of the macula in central serous retinopathy is a recognised cause of visual reduction to levels less than 20/200.⁹

The pathophysiology of these detachments may be unique. A recent report of the immunofluorescent staining of the retina in a patient with Waldenström's macroglobulinaemia showed the presence of immunoglobulin in the superficial retina, centrally in the cystoid spaces, and surrounding the photoreceptors.⁵ Serous detachment of the macula was not reported; however, Bruch's membrane and the choroid were absent on the histopathological section. These authors postulated extravasation of immunoglobulin in the superficial retina. They did not suggest a trans-pigment-epithelial route for immunoglobulin deposition in the subneurosensory retinal space. In their study the presence of high concentrations of immunoglobulin around the rod and cone outer segments would make this a plausible route. If the serous macular detachment had been the result of immunoglobulin deposition with its concomitant

oncotic pressure, prolonged serous elevation would have been expected. The clearing of immunoglobulin by the retinal pigment epithelium may have been very slow, and the toxicity of immunoglobulin to the pigment epithelium may have further hindered this process.

Toxicity of the immunoglobulin produced by blocking the diffusion of nutrients to the outer segments, oncotic pressure dehydrating the intercellular volume of cells at all levels within the retina, and persistence of immunoglobulin in and about the retinal outer segments, preventing adequate apposition to the retinal pigment epithelium, may also account for the failure of photoreceptor recovery. Theoretically, if the temperature in the serous detachment were slightly less than core body temperature, cryoprecipitation might have occurred in the subsensory retinal space.

Dr Thomas and Dr Olk were recipients of HEED fellowships.

References

- 1 Waldenström J. Incipient myelomatosis or essential hyperglobulinaemia with fibrinogenopenia—a new syndrome? *Acta Med Scand* 1944; **117**: 216–47.
- 2 Rosen ES, Simmons AV, Warnes TW. Retinopathy of Waldenström's macroglobulinemia: photographic assessment. *Am J Ophthalmol* 1968; **65**: 696–706.
- 3 Grindle CFJ, Buskard NA, Newman DL. Hyperviscosity retinopathy. A scientific approach to therapy. *Trans Ophthalmol Soc UK* 1976; **96**: 216–9.
- 4 Schwab PJ, Okun E, Fahey JL. Reversal of retinopathy in Waldenström's macroglobulinemia by plasmapheresis. A report of two cases. *Arch Ophthalmol* 1960; **64**: 515–21.
- 5 Freidman AH, Marchevsky A, Odel JG, *et al*. Immunofluorescent studies of the eye in Waldenström's macroglobulinemia. *Arch Ophthalmol* 1980; **98**: 743–6.
- 6 Orellana J, Friedman AH. Ocular manifestations of multiple myeloma, Waldenström's macroglobulinemia and benign monoclonal gammopathy. *Surv Ophthalmol* 1981; **26**: 157–69.
- 7 Pachter MR, Johnson SA, Weblet TR, Traunt TR. Bleeding platelets and macroglobulinemia. *Am J Clin Pathol* 1959; **31**: 467–82.
- 8 Asbourian GK, Nagpal KC, Busse B, *et al*. Macular and perimacular vascular remodelling in sickling haemoglobinopathies. *Br J Ophthalmol* 1976; **60**: 431–453.
- 9 Gass JDM. *Stereoscopic areas of macular diseases*. St Louis: Mosby, 1977.