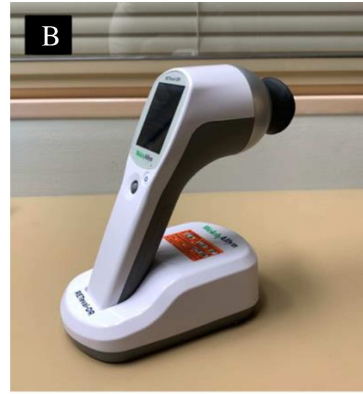
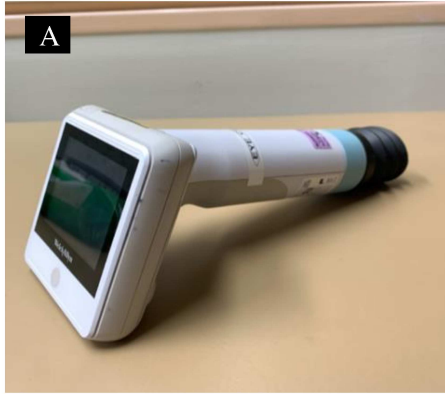
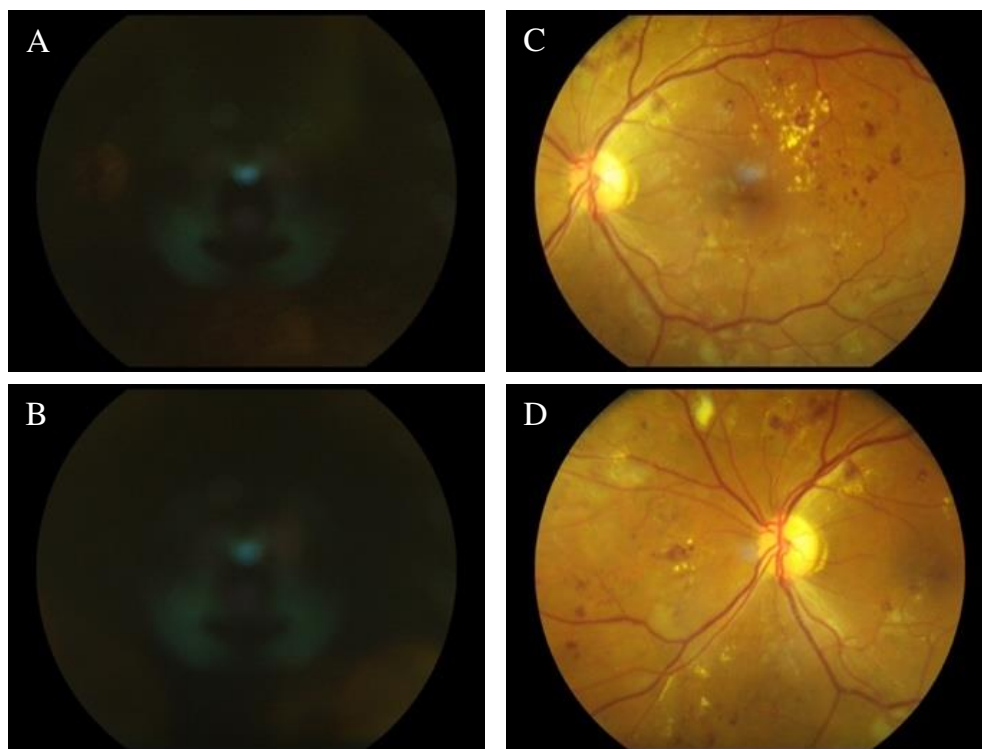
Supplementary Material

Supporting Figure 1: RetinaVue 100 device (A), RETeval device featuring a grey Ganzfeld dome (B)



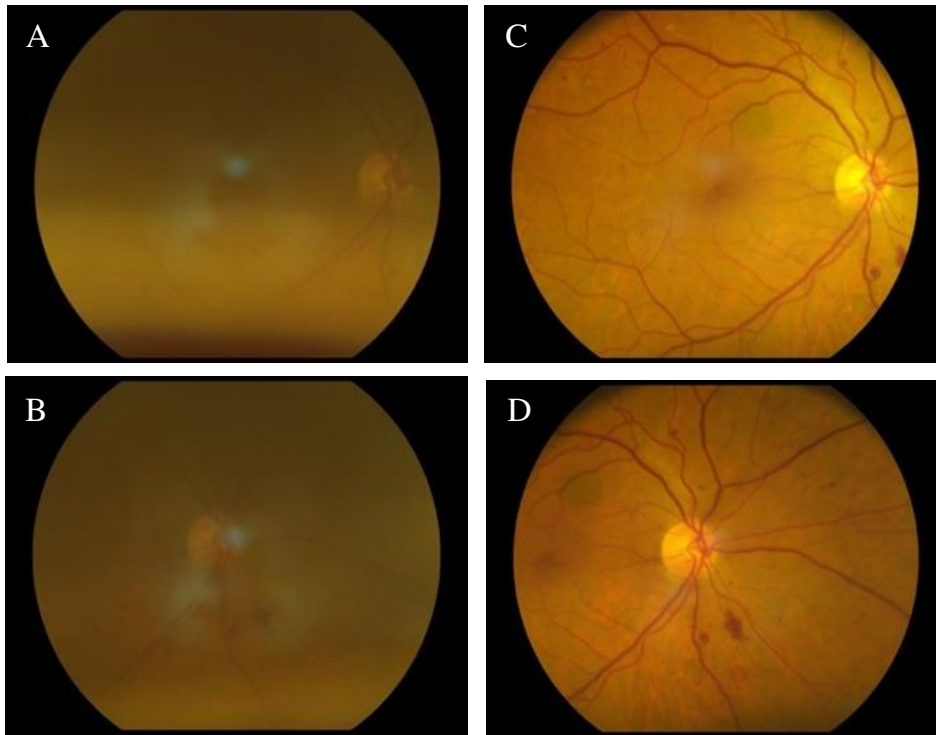
Supporting Figure 2: Non-Mydriatic vs Mydriatic Photographs (Case 1)

Non-mydriatic macula (A) and optic-disc (B) centred photographs, which are inadequate for diagnostic purposes vs. Mydriatic macula (C) and optic-disc (D) centred images of the same patient, revealing severe NPDR with hard exudates approaching the fovea



Supporting Figure 3: Non-Mydriatic vs Mydriatic Photographs (Case 2)

Non-mydriatic macula (A) and optic-disc (B) centred photographs, graded as Mild DR vs. Mydriatic macula (C) and optic-disc (D) centred images of the same patient, revealing severe NPDR



Supporting Table 1: Sensitivity and specificity results for VTDR, NPDR and Any DR

Criteria	Group	Rate (LCL, UCL)
VTDR	Sensitivity	13.7 (8.4, 20.5)
	Specificity	99.7 (99.0, 100.0)
	Accuracy	86.2 (83.8, 88.4)
NPDR	Sensitivity	21.7 (16.0, 28.4)
	Specificity	99.9 (99.3, 100.0)
	Accuracy	84.4 (81.9, 86.7)
Any DR	Sensitivity	20.2 (16.1, 25.0)
	Specificity	99.5 (98.7, 99.9)
	Accuracy	75.9 (73.2, 78.4)