

Histiocytosis X: an ophthalmological review

A T MOORE,¹ J PRITCHARD,² AND D S I TAYLOR¹

From the Departments of ¹Ophthalmology and ²Haematology/Oncology, Hospital for Sick Children, Great Ormond Street, London WC1

SUMMARY Of 76 children with histiocytosis X 18 had orbital involvement, and four developed additional neuro-ophthalmic complications. No instance of intraocular involvement was detected. Among those patients with ophthalmic involvement the main problems were bilateral or unilateral proptosis, ptosis, papilloedema, optic atrophy, and seventh nerve palsy. Only one patient developed a severe visual defect. Management of the ophthalmological complications depends not only on the extent of the orbital disease but also on the degree of systemic involvement. Overall management by a paediatric oncologist is mandatory.

Histiocytosis X is an uncommon multisystem disorder of unknown aetiology, which is characterised by accumulation of histiocytes in various tissues and which runs a variable clinical course. It is predominantly a disease of childhood but is occasionally seen in adults.¹ It has an affinity for the orbit. Ophthalmologists may be asked to see children with disseminated disease who develop proptosis during the course of their illness, but isolated orbital involvement is sometimes the presenting feature.

Histiocytosis X was a term first proposed by Lichtenstein in 1952² to cover three related disorders, eosinophilic granuloma, Hand-Schüller-Christian disease, and Letterer-Siwe disease, which he believed were different clinical expressions of a single nosological entity. 'Eosinophilic granuloma' was first coined by Lichtenstein and Jaffe³ to describe a single histiocytic lesion in bone, but it was later used to describe a condition where the histiocytic lesions, which may be multiple, were confined to bone. The original description of Hand-Schüller-Christian disease was of the triad of exophthalmos, bony defects of the skull, and diabetes insipidus. Strictly speaking this exact combination is rare,^{1,4,5} but the eponym is sometimes used to describe the chronic disseminated form of histiocytosis X involving both bone and soft tissues. Letterer-Siwe disease usually occurs in infancy with widespread soft tissue and visceral involvement with or without bony lesions, and it has a subacute, and sometimes fatal, course.

Newton and Hamoudi⁶ have correlated histo-

logical appearance with clinical prognosis and proposed a histopathological classification of histiocytosis X, but this has not gained widespread acceptance.⁷ As it is not possible to distinguish these three groups on histopathological appearance of involved tissues, and as there is considerable clinical overlap between the three conditions,⁸ it is now generally agreed that the generic term histiocytosis X should be used in preference to the eponymous subclassification.

We present here our experience with histiocytosis X and discuss the clinical features and management of the ophthalmological complications of this condition.

Material and methods

The case records of all children with histiocytosis X seen at the Hospital for Sick Children over a 26-year period from 1957 were reviewed for evidence of ocular or orbital involvement with histiocytosis X. Owing partly to changes in referral patterns half the patients had presented in the last six years.

Results

The records of 76 patients were examined. The age range was from birth to 12 years, and 30% were under the age of one year at presentation (Fig. 1). The majority of patients (39) had involvement of bone and soft tissue, while 26 patients had disease confined to bone, and in 11 patients there was soft tissue involvement only. There were no cases of

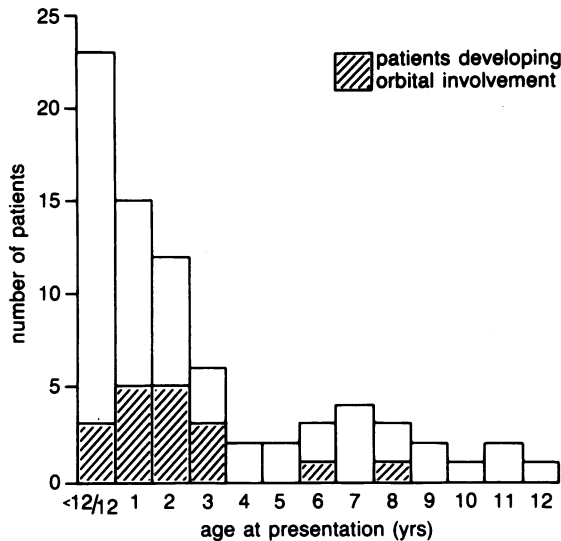


Fig. 1 Histiocytosis X. Age at presentation and orbital involvement.

orbital involvement in this latter group (Table 1). Three patients had diabetes insipidus at presentation, and a further nine patients developed it at a later stage. Classical Hand-Schüller-Christian disease, with bilateral proptosis, diabetes insipidus, and bony defects of the skull, was seen in only two patients.

Eighteen patients developed orbital involvement with histiocytosis X, half of these from the time of presentation. In 16 the diagnosis of histiocytosis X was confirmed by histopathology. Each of the two patients who did not have biopsies showed the typical clinical and radiological features of chronic disseminated histiocytosis X. Eleven patients developed unilateral proptosis, five developed bilateral proptosis, and two presented with unilateral ptosis in association with a localised orbital lytic lesion. Of particular interest are three patients who presented with isolated orbital involvement with histiocytosis X. Two of these patients showed spontaneous resolution of their disease after biopsy, and in the third case (case 2) the disease ran an unusually locally aggressive

course. None of these three cases has yet shown any additional manifestations of histiocytosis X, although the follow-up period is short (2½–3½ years).

None of our patients had evidence of intraocular involvement with histiocytosis X, but the eyes of infants with acute disseminated disease were not routinely examined if they were asymptomatic, and no eyes were examined at necropsy. Two patients with disseminated histiocytosis X and bilateral proptosis developed bilateral papilloedema. In one (case 3) there was cerebral involvement with histiocytosis X and raised intracranial pressure. Bilateral optic atrophy later ensued with severe loss of vision. In the second case necropsy showed extensive bilateral orbital involvement with histiocytosis X and gross cerebral oedema but no evidence of cerebral infiltration with histiocytes. One patient developed unilateral proptosis and optic disc swelling during his illness. The disc oedema, thought to be due to localised optic nerve involvement with histiocytosis X, resolved without sequelae after treatment with chemotherapy. One other patient developed a transient seventh nerve palsy. Only one patient in the series was left with a significant degree of visual handicap.

The following cases illustrate the variable clinical course of this condition.

ILLUSTRATIVE CASES

Case 1. This 15-month-old boy presented in January 1980 with a left ptosis and swelling of the left upper lid. His general health was otherwise good. Examination revealed a left ptosis and a palpable mass in the upper part of the left orbit (Fig. 2A). Eye examination was otherwise normal. X-rays of the left orbit showed an area of bone destruction at the superolateral aspect of the left orbit (Figs. 2B, C), and orbital CT scan showed a small extraconal mass at the lateral side of the left orbit. General examination, liver scan, bone scan, skeletal survey, bone marrow examination, and urinary osmolality were all normal. Biopsy of the lesion showed the typical histological appearance of histiocytosis X. No treatment was given, and the ptosis and orbital mass resolved over the next five months (Fig. 2D). X-ray examination at this time showed healing of the orbital lesion. He has remained well with no recurrence of histiocytosis X.

Case 2. This 8-year-old boy presented in March 1980 with a history of a left periorbital swelling present for two months. He had been born in England of Jamaican parents, and apart from frequent upper respiratory tract infections in childhood had been generally well. On examination the vision was 6/6 RE and 6/9 LE. A rubbery mass was palpable around the upper and lower orbital margins and extending over the lateral wall and down over the

Table 1 Orbital involvement in Histiocytosis X

	Patients with general involvement	Patients with orbital involvement
Group 1 Bone involvement only	26	6
Group 2 Soft tissue involvement only	11	0
Group 3 Bone and soft tissue involvement	39	12
Total	76	18

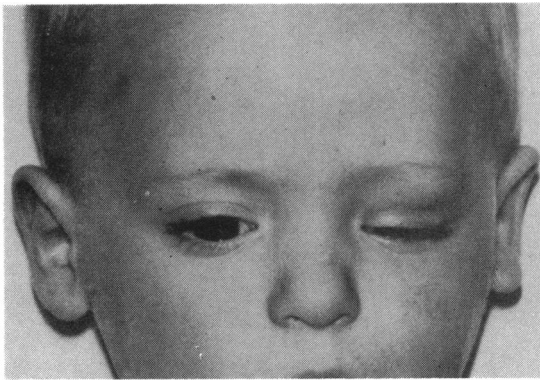

Fig. 2A

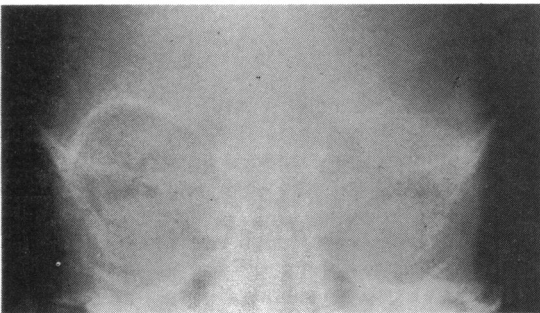


Fig. 2B

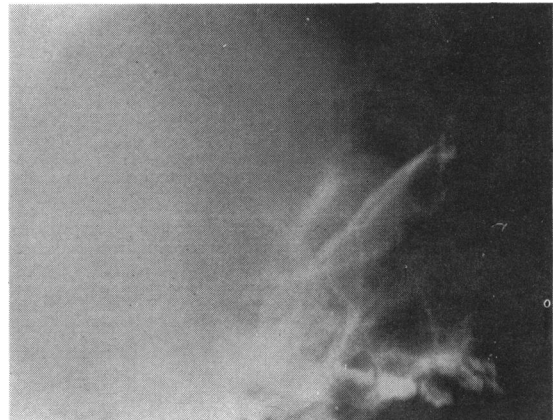

Fig. 2C

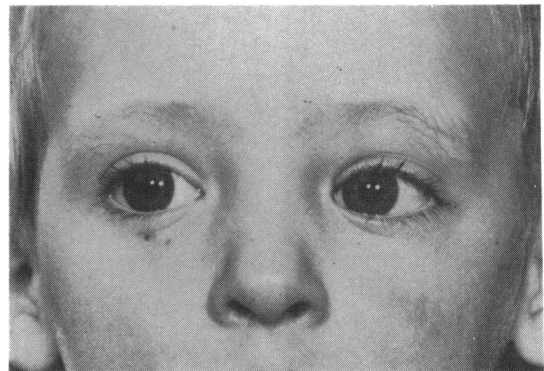

Fig. 2D

Fig. 2 Case 1. A: Left ptosis associated with orbital histiocytosis X. B and C: anteroposterior and lateral x-rays showing lytic lesion of left orbit with surrounding area of bony sclerosis. D: after resolution.

zygoma. There was 6 mm of left axial proptosis (Fig. 3A), but eye movements, pupil reactions, and fundus examination were normal. X-rays of the orbit showed a lytic lesion of the lateral wall, and CT scan showed a left orbital mass (Fig. 3B). A biopsy of the orbital mass showed the typical appearance of histiocytosis X. General examination, chest x-ray, skeletal survey, bone marrow, and urinary osmolalities were all normal.

Because there was no shrinkage after excision biopsy and because of the cosmetic appearance, the left orbit was treated in July 1980 with radiotherapy (1000 cgray). Initially there was a favourable response, but by the end of 1981 the mass had extended to involve the temporal fossa, and a large tumour mass was evident on the surface of the skin (Fig. 3C). The degree of proptosis and visual acuity was unchanged. In February 1982 the main part of the lesion was excised, and the underlying abnormal tissue curetted from the bone leaving a large defect in the lateral orbital wall and over the maxilla. Histology of the excised tissue again showed histiocytosis

X. Depo-Medrone 80 mg (methylprednisolone acetate), and Solu-medrone 100 mg (methylprednisolone sodium succinate) were injected into the residual tumour on four occasions over the next six months, and the tumour became smaller. When the patient was last seen in December 1982 the vision was 6/6 RE and 6/9 LE. There was 6 mm of left axial proptosis (Fig. 3D), but eye examination was otherwise normal. He has developed no further manifestations of histiocytosis X.

Case 3. This 2½-year-old Pakistani girl presented in July 1978 with fever and bilateral proptosis. There was bilateral axial proptosis, but eye examination was otherwise normal. There was a palpable mass on the vertex of the skull and over the left zygoma, an eczematous rash on the scalp, and a palpable liver and spleen. Skull x-ray showed several lytic lesions, and biopsy of one of the skull lesions showed histiocytosis X (Fig. 4). Chest x-ray and bone marrow examination were normal. Treatment was started with prednisolone and vinblastine, and when reviewed three months later she appeared to be

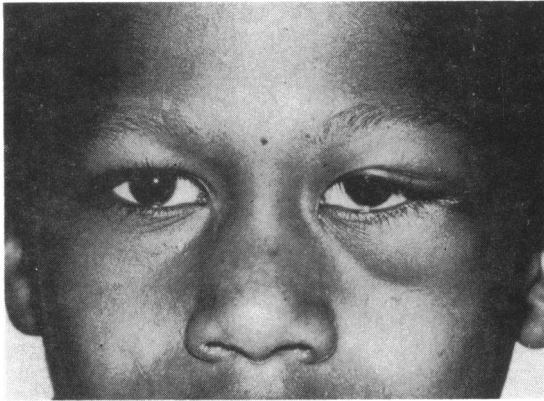


Fig. 3A

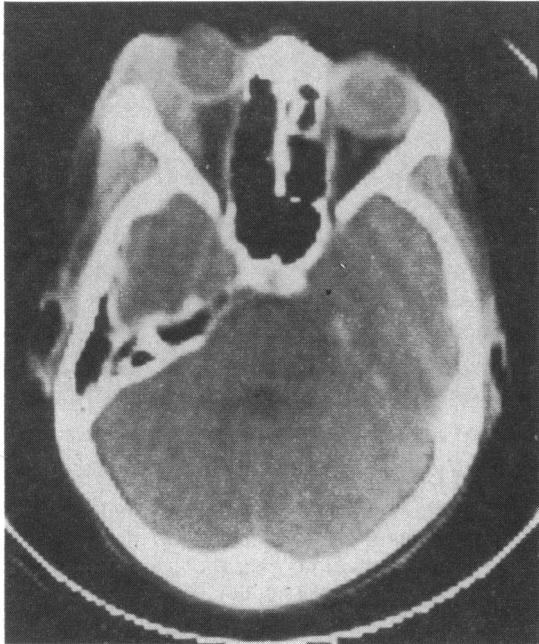


Fig. 3B

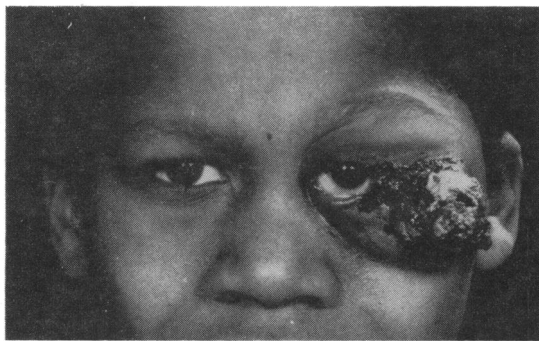

Fig. 3C

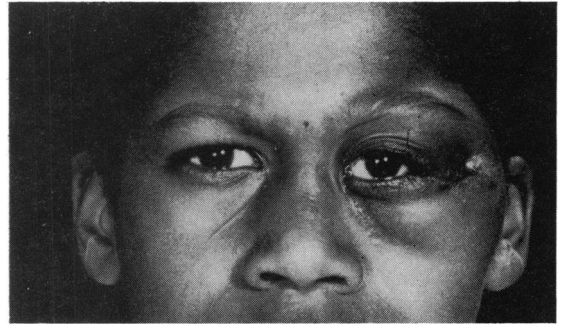

Fig. 3D

Fig. 3 Case 2. *Histiocytosis X* of the left orbit. A: At presentation. B: CT scan showing left orbital mass. C: Recurrence after radiotherapy. D: At last follow-up visit.

responding to treatment, and the proptosis was less marked.

Chemotherapy was stopped in March 1979, but this was soon followed by worsening of her bilateral proptosis and the appearance of new lesions of the skull and zygoma. Her pupil reactions and fundus examination were normal. CT scan showed bilateral soft tissue masses in both orbits with bilateral invasion of the middle cranial fossa. Chemotherapy was restarted, and both orbits, pituitary areas, and middle cranial fossa were treated with radiotherapy (1500 cgray). She returned to Pakistan, where treatment was continued with prednisolone, vinblastine, and, later, cyclophosphamide.

In May 1981 she returned to London for review. She had been drowsy and vomiting for one month. On examination the proptosis was more marked. There was a mass in the left upper lid, a left relative afferent pupil defect, and bilateral disc oedema. CT scan (Fig. 7) showed increased size of the orbital masses, dilated third and fourth ventricles, and oedema of both temporal lobes. She initially improved on dexamethasone, but when she was re-examined six months later there was again a left afferent pupil defect, but now there was bilateral optic atrophy thought to be secondary to raised intracranial pressure. CT scan showed bilateral orbital masses and low attenuation in both temporal lobes and posterior fossa. A ventriculoperitoneal shunt was inserted and a brain biopsy taken, which confirmed cerebral involvement with histiocytosis X. Post-operatively the vision deteriorated. There was no pupillary response to light, and there was bilateral optic atrophy. Electrodiagnostic tests showed a normal ERG but absent visual evoked response from each eye. The patient returned to Pakistan and we have no further follow-up.

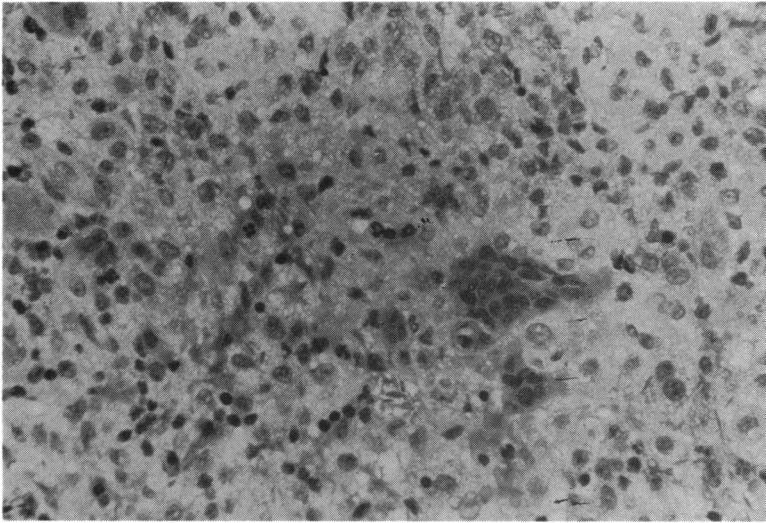


Fig. 4 Case 3. Skull biopsy specimen. Light microscopy of the biopsy revealed similar changes in all three illustrative cases. The infiltrate comprised a mixture of mononuclear histiocytes with indented nuclei and smaller numbers of multinucleate giant cells, eosinophils, neutrophils, and lymphocytes.

Discussion

Histiocytosis X is an uncommon cause of orbital tumour and is not mentioned in several series of paediatric orbital tumours.⁹⁻¹² Henderson¹³ found that histiocytosis X accounted for just 1% of a total of 764 orbital tumours seen in both children and adults at the Mayo Clinic over a 26-year period. All but one of these cases were in children under the age of two years. In a large series of paediatric orbital tumours Crawford¹⁴ found histiocytosis X represented 7% of

257 cases of proptosis seen in children under the age of 15 presenting at a large children's hospital. The variation in these figures probably reflects the referral pattern of the different centres. Ophthalmologists who work in hospitals with a regional paediatric oncology unit are more likely to see orbital histiocytosis X than, for example, those working in eye hospitals or neurosurgical units.

In patients with histiocytosis X orbital involvement is, however, common, and with some exceptions¹⁵⁻¹⁶ is usually seen in the chronic form of the disease⁵ especially 'Eosinophilic granuloma'.¹⁷⁻²⁴ The overall incidence of orbital involvement in larger series of patients with histiocytosis X is about 20%,^{5,25} but only half of these patients developed proptosis.^{14,26} In our series 23% of patients had clinical signs of orbital involvement, and most had proptosis. There may be radiological evidence of orbital involvement without any accompanying clinical signs, but proptosis is almost invariably associated with a lytic lesion of the orbital wall.^{1,5} In our study there were no cases of orbital involvement in patients whose disease was confined to the soft tissue (Table 1), suggesting that in histiocytosis X the orbital lesion usually arises in bone.

Intraocular involvement by histiocytosis X is rare. It is usually seen in infants with the subacute disseminated form and consists of infiltration of intraocular structures, especially the uveal tract, with histiocytes.²⁷⁻³⁴ This may be an incidental finding at necropsy,^{29,31,33} but some patients will present with ocular abnormalities during their acute illness.^{27,28,30,32-34} Mozziconacci *et al.*²⁷ reported on a 2-year-old girl with Letterer-Siwe disease who first developed choroidal infiltrates and later a total

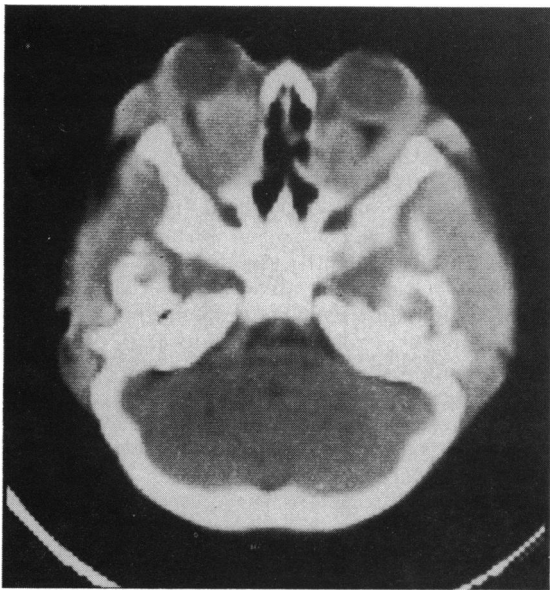


Fig. 5 Case 3. CT Scan showing bilateral orbital mass.

retinal detachment. The eye was subsequently enucleated, and histological examination showed infiltration of the choroid, retina, and vitreous with histiocytes. Rupp and Holloman³⁰ reported on a 3-month-old child with histiocytosis X who developed uveitis, iris infiltration, and spontaneous hyphaema during the course of her illness. Necropsy of the eye showed histiocytic infiltration of the uveal tract. Secondary open-angle glaucoma,²⁸ bilateral perforating corneal ulcers,²⁹ and posterior scleritis³² have also been reported.

In contrast, orbital involvement is rare in the acute disseminated form of histiocytosis X⁵ as confirmed in this study. It is usually seen in patients with the chronic disseminated form. Optic neuropathy and cranial nerve palsies are rare^{17,24} as the orbital mass is usually extraconal, and destruction of the orbital walls may result in orbital decompression. Beller and Kornbleuth,¹⁷ however, reported a 14-year-old boy who developed optic neuropathy and third, fourth, and sixth cranial nerve palsies. The optic nerve and chiasm may become involved by intracranial histiocytosis X, which has a predilection for the pituitary gland.³⁵ Papilloedema and secondary optic atrophy may result from raised intracranial pressure secondary to intracranial involvement with histiocytosis X.³⁶ Although orbital and pituitary involvement with histiocytosis X was commonly seen in our series, only four patients developed neuro-ophthalmic complications.

The diagnosis of histiocytosis X is ultimately confirmed by histopathological examination of biopsy specimens of involved tissues. In children with orbital involvement as part of systemic disease it is usually easier to take a biopsy specimen from another site such as the scalp, or a peripheral bony lesion. In isolated orbital involvement the diagnosis should be suspected when a child presents with periorbital swelling, ptosis, or proptosis, and there is evidence of a lytic lesion on *x*-ray, with or without a narrow zone of sclerosis (Fig. 2B). The radiological appearances are, however, variable³⁷ and may resemble Ewing's sarcoma, osteomyelitis, metastatic tumour—especially neuroblastoma or lymphoblastic leukaemia—or even fibrous dysplasia. The diagnosis may, therefore, be in doubt until histopathology is available. In children with isolated orbital involvement it is usually possible to take a biopsy specimen from the involved orbital bone without having to enter the orbit. The bone will be found to be infiltrated by soft yellow-brown material which is easily curetted. Orbital histiocytosis X must be differentiated from other histiocytic disorders which may involve the orbit, such as sinus histiocytosis,^{38,39} and juvenile xanthogranuloma (JXG). These conditions, however, usually remain confined to the orbital soft

tissues and do not involve bone, although JXG may rarely result in orbital bony destruction.^{40,41} If there are no other systemic features, it may be difficult to distinguish between orbital histiocytosis X and JXG clinically, but light and electron microscopy of a biopsy specimen are diagnostic.

Children whose disease is confined to a single system such as bone or skin have a good prognosis, though there may be a later recurrence in about one-third of cases.⁸ In patients with a single bony lesion biopsy and curettage may be followed by spontaneous resolution, as occurred in two of our patients. However, if there is marked proptosis, or a cosmetically unacceptable lesion of the orbital wall, or evidence of optic nerve involvement, a short course of systemic steroids or radiotherapy may be used in an attempt to induce remission. A radiation dose of 500–600 cgray is usually sufficient and a total dose of not more than 1000 cgray is recommended.⁴² There is no evidence that lesions which do not respond to 1000 cgray will respond to a higher dose, and because of the fear of radiation induced malignancy later in life this dose should be exceeded only in exceptional circumstances. An alternative approach to disfiguring lesions of the orbital wall is to remove the main mass of the lesion surgically, with curettage of the underlying bone. Intralesional steroids as used in Case 2 may also be tried.⁴³ The relative infrequency of optic nerve compression and the good response to radiotherapy or chemotherapy means that surgical exploration of the orbit is rarely necessary. In patients with disseminated histiocytosis X, orbital disease, causing proptosis, will generally respond to systemic chemotherapy, though local radiotherapy may be used in addition if there is progressive proptosis or optic nerve involvement. In view of the tendency to spontaneous regression, in both single system disease (as illustrated in case 1) and in multisystem⁴⁴ disease, we recommend a conservative therapeutic approach, including an initial period of observation, without specific therapy.

The most frequently used systemic agents are prednisone, vincristine, or vinblastine, and the epipodophyllotoxin VP16. The response rate to multi-drug regimens is no greater than to single or double agent therapy, and the complication rate is higher.⁸ Therefore, we commence chemotherapy, if it is needed, with prednisone alone, adding vincristine where the response to steroids is inadequate and using VP16 in resistant disease.

Recent investigations have shown a subtle immunological defect in patients with histiocytosis X. Osband *et al.*⁴⁵ found a relative suppressor cell deficiency in the peripheral blood mononuclear cells of patients with multiple organ involvement. This

finding has been confirmed in a separate group of children (including one of the patients reported here) with histiocytosis X limited to the skeletal system.⁴⁶ Though immunohistochemical studies confirm that the histiocytosis X disease process is characterised by abnormal accumulation of histiocytes, including Langerhans cells,⁴⁷ it is not yet clear whether suppressor cell deficiency is the cause of the disordered histiocytic proliferation or an unrelated 'secondary' effect. However, the presence of the same immunological abnormality in patients with both single system and multisystem disease adds weight to the clinical⁸ and histopathological⁷ evidence supporting Lichtenstein's 'unifying' concept of the histiocytosis X disorders.²

After demonstrating that the suppressor cell deficiency could be corrected *in vitro* by 'thymosin' (a crude extract of calf thymus), the Boston group administered this material intramuscularly to a group of children with newly diagnosed histiocytosis X.⁴⁵ The overall 'response rate' was 60%, a figure comparable with that achieved with chemotherapy. In London we have studied the effects of synthetic analogues (TP1 and TP5) believed to represent the active moiety of 'thymosin'. Though we confirmed that the reduced suppressor: helper lymphocyte ratio was corrected by TP1 or TP5 in the majority of patients, there was no clinical response to these preparations in five patients.⁴⁶ Because of the tendency to spontaneous remission in histiocytosis X⁴⁴ it is essential that future studies of novel forms of therapy, such as thymic hormones, include controlled, randomised trials.

The prognosis in histiocytosis X depends upon several factors: the age of onset, the extent of disease, and the presence or absence of organ failure. The prognosis is worse in infants, and death is rare in children who present after the age of 3 years.⁴⁸ Single system disease is associated with a good prognosis. Children with multisystem disease may die because of failure of key organs such as bone marrow, liver, and lungs. Though there is a significant morbidity in survivors, who may develop growth failure, diabetes insipidus, or respiratory problems, long-term visual problems are rare.

New cases of histiocytosis X presenting to the ophthalmologist are best managed in collaboration with a paediatric oncologist. Advice from other specialists such as ENT and orthopaedic surgeons may be needed for specific problems. Even if there is no clinical evidence of systemic involvement, chest x-ray, skeletal survey, bone marrow examination, lung and liver function tests, and early morning urine specific gravity are needed to assess the extent of the disease and will determine the appropriate treatment.

The authors thank the many colleagues who referred patients, especially Mr Peter Leaver (case 1), Mr John Wright (case 2), and Professor Otto Wolff. We also thank Dr John Pincott for reviewing the histopathology, and Heather Lucas and Paula Charles for secretarial help.

Mr Moore received financial support from the T.F.C. Frost Charitable Trust, and Dr Pritchard from the Leukaemia Research Fund.

References

- Enriquez P, Dahlin DC, Hayles AB, Henderson ED. Histiocytosis X: A clinical study. *Mayo Clin Proc* 1967; **42**: 88-99.
- Lichtenstein L. Histiocytosis X. Integration of eosinophilic granuloma of bone, "Letterer-Siwe disease" and "Schüller-Christian disease" as related manifestations of a single nosological entity. *Arch Pathol* 1953; **56**: 84-102.
- Lichtenstein L, Jaffe HL. Eosinophilic granuloma of bone with report of a case. *Am J Pathol* 1940; **16**: 595-604.
- Lucaya JL. Histiocytosis X. *Am J Dis Child* 1971; **121**: 289-95.
- Oberman HA. Idiopathic histiocytosis: a correlative review of eosinophilic granuloma, Hand-Schüller-Christian disease and Letterer-Siwe disease. *J Pediatr Ophthalmol* 1968; **5**: 86-92.
- Newton WA, Hamoudi AB. Histiocytosis: a histological classification with clinical correlation. In: Rosenberg HS, Bolande RP, eds. *Perspectives in pediatric pathology*. Chicago, Illinois: Year Book Publishers, 1973; **1**: 251-81.
- Risdall RJ, Dehner LP, Duray P, Kobrinsky N, Robison L, Nesbit Jr ME. Histiocytosis X (Langerhans' cell histiocytosis): prognostic role of histopathology. *Arch Pathol Lab Med* 1983; **107**: 59-63.
- Pritchard J. Histiocytosis X: natural history and management in childhood. *Clin Exp Dermatol* 1979; **4**: 421-33.
- Youseffi B. Orbital tumours in children: a clinical study of 62 cases. *J Pediatr Ophthalmol* 1969; **6**: 177-81.
- Porterfield JF. Orbital tumours in children: a report on 214 cases. *Int Ophthalmol Clin* 1962; **2**: 319-35.
- MacCarty CS, Brown DN. Orbital tumours in children. *Clin Neurosurg* 1964; **11**: 76-93.
- Templeton AC. Orbital tumours in African children. *Br J Ophthalmol* 1971; **55**: 254-61.
- Henderson JW. *Orbital tumours*. 2nd ed. Stuttgart: Dekker, 1980; 377-86.
- Crawford JS. Disease of the orbit. In: Crawford JS, Morin JD, eds. *The eye in childhood*. New York: Grune and Stratton, 1983: 331-64.
- Mortada A. Non-lipoid and lipid reticulo-endotheliosis of orbital bones. *Am J Ophthalmol* 1966; **61**: 558-60.
- Pearlstone AD, Flom L. Letterer-Siwe's disease. *J Pediatr Ophthalmol* 1970; **7**: 103-5.
- Beller AJ, Kornbleuth W. Eosinophilic granuloma of the orbit. *Br J Ophthalmol* 1951; **35**: 220-5.
- Truhlsen SM. Eosinophilic granuloma involving the orbit. Report of a case. *Am J Ophthalmol* 1954; **37**: 571-5.
- Chawla HB, Cullen JF. Eosinophilic granuloma of the orbit. *J Pediatr Ophthalmol* 1968; **5**: 93-5.
- Straatsma BR. Eosinophilic granuloma of bone. *Trans Am Acad Ophthalmol Otolaryngol* 1958; **62**: 771-6.
- Baghdassarian SA, Shamma HF. Eosinophilic granuloma of orbit. *Ann Ophthalmol* 1977; **9**: 1247-51.
- Nirankari MS, Singh M, Manchanda SS, Chitkara NL, Maudgal MC. Eosinophilic granuloma of the orbit. *Arch Ophthalmol* 1957; **58**: 857-61.
- Wheeler M. Exophthalmos caused by eosinophilic granuloma of bone. *Am J Ophthalmol* 1946; **29**: 980-4.
- Heuer HE. Eosinophilic granuloma of the orbit. *Acta Ophthalmol (Kbh)* 1972; **50**: 160-5.
- Bray PT. Histiocytosis X. In: Decley TJ, ed. *Modern radiotherapy and oncology. Malignant disease in childhood*. London: Butterworth, 1974: 372-94.

- 26 Sims DG. Histiocytosis X. Follow-up of 43 cases. *Arch Dis Child* 1977; **52**: 433-40.
- 27 Mozziconacci P, Offret G, Forest A, *et al*. Histiocytose X avec lésions oculaires. Étude anatomique. *Ann Pediat (Paris)*. 1966; **13**: 348-55.
- 28 Epstein DL, Grant WM. Secondary open angle glaucoma in histiocytosis X. *Am J Ophthalmol* 1977; **84**: 332-6.
- 29 Mittleman D, Apple DJ, Goldberg MF. Ocular involvement in Letterer-Siwe disease. *Am J Ophthalmol* 1973; **75**: 261-5.
- 30 Rupp RH, Holloman KR. Histiocytosis X affecting the uveal tract. *Arch Ophthalmol* 1970; **84**: 468-70.
- 31 Zimmerman LE. Ocular lesions of juvenile xanthogranuloma: nevoxanthoendothelioma. *Trans Am Acad Ophthalmol Otolaryngol* 1965; **69**: 412-42.
- 32 Heath P. The ocular features of a case of acute reticulo-endotheliosis (Letterer-Siwe type). *Trans Am Ophthalmol Soc* 1959; **57**: 290-302.
- 33 Anderson B, Margolis G, Lynn WS. Ocular lesions related to disturbance in fat metabolism. *Am J Ophthalmol* 1958; **45** (suppl): 23-41.
- 34 Lahav M, Albert DM. Unusual ocular involvement in acute disseminated histiocytosis X. *Arch Ophthalmol* 1974; **91**: 455-8.
- 35 Kepes JJ, Kepes M. Predominantly cerebral forms of histiocytosis X. *Acta Neuropathol (Berl)* 1969; **14**: 77-98.
- 36 Feinberg SB, Langer LO. Roentgen findings of increased intracranial pressure and communicating hydrocephalus as insidious manifestations of chronic histiocytosis X. *AJR* 1965; **95**: 41-7.
- 37 Takahashi M, Martel W, Oberman HA. The variable roentgenographic appearance of idiopathic histiocytosis. *Clin Radiol* 1966; **17**: 48-53.
- 38 Foucar E, Rosai J, Dorfmann RF. The ophthalmologic manifestations of sinus histiocytosis with massive lymphadenopathy. *Am J Ophthalmol* 1979; **87**: 354-67.
- 39 Friendly DS, Font RL, Rao NA. Orbital involvement in sinus histiocytosis. *Arch Ophthalmol* 1977; **95**: 2006-11.
- 40 Sanders TE, Miller JE. Infantile xanthogranuloma of the orbit. *Trans Am Acad Ophthalmol Otolaryngol* 1965; **69**: 458-64.
- 41 Gaynes PM, Cohen GS. Juvenile xanthogranuloma of the orbit. *Am J Ophthalmol* 1967; **63**: 755-7.
- 42 Smith DG, Nesbit ME, D'Angio GJ, Levitt SH. Histiocytosis X: role of radiation therapy in management with special reference to dosage levels employed. *Radiology* 1973; **106**: 419-22.
- 43 Cohen M, Zornoza J, Cangir A, Murray JA, Wallace S. Direct injection of methyl prednisolone sodium succinate in the treatment of solitary eosinophilic granuloma of bone. A report of nine cases. *Radiology* 1980; **136**: 289-93.
- 44 Broadbent V, Davies EG, Heaf D, *et al*. Spontaneous remission of multisystem histiocytosis X. *Lancet* 1984; **i**: 253-4.
- 45 Osband ME, Lipton JM, Lavin P, *et al*. Histiocytosis X: demonstration of abnormal immunity, T-cell histamine H2-receptor deficiency and successful treatment with thymic extract. *N Engl J Med* 1981; **304**: 146-53.
- 46 Davies EG, Lcvinsky RJ, Butler M, Broadbent V, Pritchard J, Chessells JM. Thymic hormone therapy for histiocytosis X. *N Engl J Med* 1983; **309**: 493-4.
- 47 Thomas JA, Janosy G, Chilosi M, Pritchard J, Pincott JR. Combined immunological and histochemical analysis of skin and lymph node lesions in histiocytosis X. *J Clin Pathol* 1982; **35**: 327-37.
- 48 Lahcy ME. Histiocytosis X: An analysis of prognostic factors. *J Pediatr* 1975; **87**: 184-9.