

Unilateral Kayser-Fleischer ring

J R INNES, I M STRACHAN, AND D R TRIGER

From the Royal Hallamshire Hospital, Glossop Road, Sheffield S10 2JF

SUMMARY A patient is presented who had unrecognised Wilson's disease. He had developed a clinically obvious Kayser-Fleischer ring in only one eye. The eye without the corneal ring had been injured in childhood and had a low intraocular pressure. Possible mechanisms for formation of a Kayser-Fleischer ring are reviewed and the lack of Kayser-Fleischer ring in this case is discussed.

Case history

The patient first noticed a slight tremor of his hand and slight unsteadiness of gait at the age of 35. These symptoms progressed very slowly, and he was first seen by a neurologist at the age of 52. Signs present at that time were unsteadiness, cerebellar dysarthria, and ataxia of the hands, the right more than the left. The right eye was blind and divergent, the result of a penetrating injury by a dart at the age of 7.

His past medical history revealed an episode of jaundice as a teenager and a urinary infection at the age of 40. Relevant family history was that his identical twin brother had died of hepatitis at the age of 47. He had also suffered from ataxia of a similar severity.

Hereditary ataxia was diagnosed.

The patient's condition gradually worsened until at

the age of 56 he was unable to walk without the aid of a stick. At the age of 60 he was admitted to hospital because of liver failure. He was jaundiced, had palmar erythema, spider naevi, and pigmentation. His liver was enlarged and he had ascites. He was anarthric and aggressive.

The eye findings were as follows: The right eye (Fig. 1) was divergent; there was a corneal scar which did not obscure iris detail. There was a dense cataract precluding a view of the fundus. The corneal periphery appeared normal, including the area at the limbus at 6 and 12 o'clock. The intraocular pressure was low, giving a measure of zero on the Goldmann applanation tonometer.

The left eye (Fig. 2) appeared healthy. The only abnormality was a brown ring 3 mm wide at the corneal periphery and extending around 360° of the circumference. The pigment lay at the level of Descemet's membrane and was diagnosed as a Kayser-Fleischer ring. Intraocular pressure was

Correspondence to Mr J R Innes, FRCS, Hull Royal Infirmary, Anlaby Road, Hull HU3 2JZ.

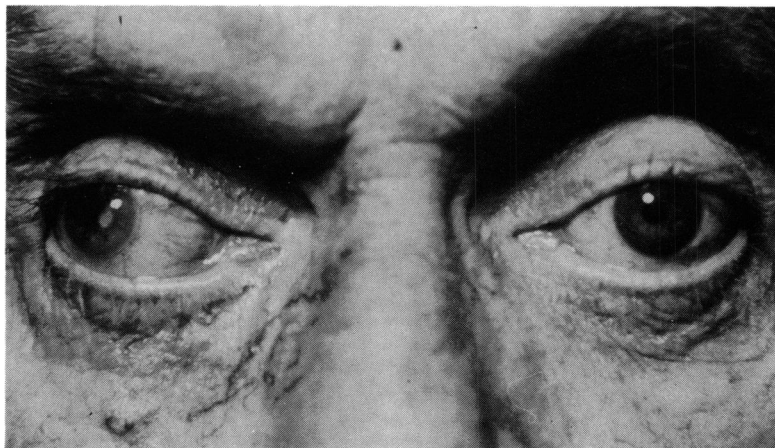

Fig. 1 Divergent right eye with no evidence of Kayser-Fleischer ring. Left eye has a dense Kayser-Fleischer ring.

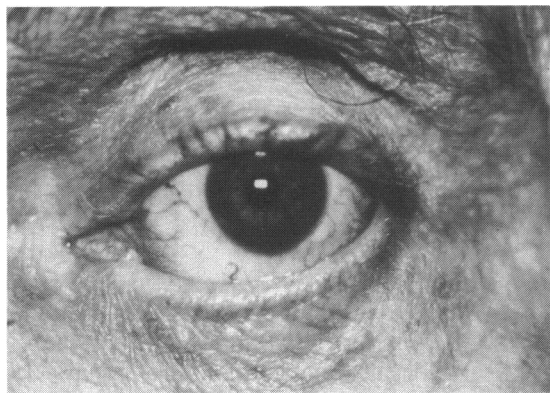


Fig. 2 Close-up of the left eye.

10 mmHg by the Goldmann applanation tonometer.

A percutaneous liver biopsy was performed, and this showed chronic aggressive hepatitis with cirrhosis. Special histochemical stains for copper were positive. The liver copper concentration was raised at 3.1 µg/mg (normal <1.0). The 24-hour urinary excretion of copper was 3.4 and 4.6 µmol on two consecutive days. There was a positive response to D-penicillamine, with copper excretion rising to 14 µmol per 24 hours. Apart from the serum ceruloplasmin level, which was normal at 0.22 g/l, these findings supported the diagnosis of Wilson's disease.

Unfortunately his liver further decompensated and he collapsed and died two weeks later of a pulmonary embolism. Histological study of the eye was not possible.

Discussion

The Kayser-Fleischer corneal pigment ring is said to be diagnostic of Wilson's disease (hepatolenticular degeneration).¹ It is not necessarily present in pre-symptomatic cases but is present in all cases of Wilson's disease with neurological involvement.² Corneal pigment rings have also been seen, however, in cases of primary biliary cirrhosis and chronic active liver disease not due to Wilson's disease³ and in cases of multiple myeloma.^{4,5} Corneal pigment rings should therefore not be regarded as pathognomonic of Wilson's disease in the absence of neurological symptoms.⁴

The corneal ring in Wilson's disease appears first as an arc in the corneal periphery from 10 to 2 o'clock, extending from the corneal margins centrally. This is followed by a similar inferior arc, the two then spreading round the circumference. The ring is densest peripherally, ending at Schwalbe's line, and rarely extends more than 5 mm centrally. The

variable position of Schwalbe's line is thought to be the reason for varying descriptions of Kayser-Fleischer rings as having, or not having, a clear ring of cornea peripherally.⁶ Copper is deposited in the inner part of Descemet's membrane in the form of granules which may,^{7,8} or may not,⁹ be in zones. It is this 'copper chelate' which accounts for Kayser-Fleischer ring. However, the cornea is also permeated by ionic copper. This accounts for the high concentration of copper in the cornea found by spectroanalytic study¹⁰ and for the lack of correlation between the appearance of a Kayser-Fleischer ring and the corneal copper as measured by x-ray excitation spectrometry.¹¹

Deposition of granular copper material has been attributed to cellular activity, the granule production being related to formation of basement membrane by endothelial cells.¹²

Kayser-Fleischer rings disappear in the reverse order to their formation on treatment with D-penicillamine¹³ and after liver transplantation.¹⁴

The direct source of copper for incorporation into Descemet's membrane is in dispute. It has been suggested^{4,15} that the limbal circulation could be the source, while others¹² regard the aqueous, which contains elevated levels of copper,⁴ to be the source. We believe the case we have described provides strong circumstantial evidence for the latter theory. The limbal circulation of our patient's right eye had not been disturbed, whereas his aqueous production was greatly reduced as shown by the extremely low intraocular pressure. We presume therefore that there was a much lower through-put of copper in the aqueous of his right eye, so that a Kayser-Fleischer ring did not form in this eye.

References

- 1 Walshe JM. The eye in Wilson's disease. *Birth Defects* 1976; **12**: 187-9.
- 2 Cairns JE, Walshe JM. *Trans Ophthalmol Soc UK* 1970; **40**: 187-90.
- 3 Fleming CR, Dickson ER, Wahner HW, Hollenhorst RW, McCall JT. *Ann Intern Med* 1977; **86**: 285-8.
- 4 Ellis PP. *Am J Ophthalmol* 1969; **68**: 423-7.
- 5 Lewis RA, Falls HF, Troyer DO. *Arch Ophthalmol* 1975; **93**: 1050-3.
- 6 Goldberg-. In discussion. *Birth Defects* 1976; **12**: 191.
- 7 Uzmann LL, Jakus MA. *Neurology* 1957; **7**: 341-5.
- 8 Harry J, Tripathi R. *Br J Ophthalmol* 1970; **54**: 794-800.
- 9 Johnson BL. *Am J Ophthalmol* 1973; **76**: 455-61.
- 10 Coleman SL, Sanders TE, Field BD. *Am J Ophthalmol* 1963; **56**: 297-9.
- 11 Belkin M, Zcimer R, Chajek T, Friedman G, Melamed E. *Lancet* 1976; **i**: 391-4.
- 12 Tso MOM, Fine BS, Thorpe HE. *Am J Ophthalmol* 1975; **79**: 479-88.
- 13 Sussman W, Scheinberg IH. *Arch Ophthalmol* 1969; **82**: 738-41.
- 14 Schoenberger M, Ellis PP. *Arch Ophthalmol* 1979; **97**: 1914-5.
- 15 Bron A. In discussion. *Trans Ophthalmol Soc UK* 1970; **40**: 191.

Accepted for publication 17 October 1985.