

Sport associated eye injury: a casualty department survey

CAROLINE J MACEWEN

From Glasgow Eye Infirmary, 3 Sandyford Place, Glasgow G3 7NB

SUMMARY A survey was performed of all patients attending the combined Glasgow Eye Infirmary and Western Infirmary Eye Casualty Department with sports injuries. During an 18-month period a total of 246 patients presented with such injuries. Football was responsible for 110 (44.7%), rugby for 24 (9.8%), squash for 19 (7.7%), badminton for 16 (6.5%), and skiing for 9 (3.7%), and 68 (27.6%) were caused by other sports. One hundred and sixty-two patients (65.8%) had superficial or surrounding soft tissue injuries, 54 (22%) had more severe anterior segment damage in the form of hyphaema or traumatic uveitis, 17 (6.9%) had retinal damage manifest as oedema or retinal tear with or without detachment, and two (0.8%) suffered severe disruption of the globe with subsequent loss of the eye in each case. Forty-six (18.7%) required inpatient care and 200 (81.3%) were treated as outpatients, of whom 104 required at least one follow-up appointment (42.3% of the total). I conclude that with increasing time available for leisure activities there has been a parallel increase in sport associated eye trauma.

Keeping fit by participating in sport is becoming more popular in all age groups. This has undoubtedly resulted in an improvement in general health, but it has also caused an increase in sporting injuries which has been termed the 'unthwarted epidemic'.¹ Despite the eye's protected position and its protective reflexes it is still vulnerable to injury, especially in sports which involve a small ball.² Squash racquets has aroused much interest for this reason.^{3–8} Badminton is also recognised as a racquet sport in which ocular injury may occur.^{4,7–9} Golf,¹⁰ hockey,^{11,12} tennis,¹³ and swimming¹⁴ have all been recorded as a source of eye trauma. Boxing by its very nature may cause facial and eye injuries.^{8,15–17} The problem of sport associated eye injury has been recognised and attention is now concentrated on methods of protection from and prevention of such injuries.^{18,19}

The aim of this study was to determine the incidence, mechanism, and outcome of eye injuries associated with various sports in the west of Scotland.

Materials and methods

All casualty records for the 18-month period 1 January 1985 to 30 June 1986 were examined retro-

spectively. The records of all sport associated eye injuries were identified, and details of age and sex, mechanism of injury, extent of injury, and outcome were all noted along with the sport involved. Despite its being a retrospective study the details of mechanism of injury were well documented. However, one aspect—namely, that of eye protection in use—was poorly recorded.

Results

A total of 246 cases of sport-associated eye injuries were identified. There were 213 (86.6%) male patients and 33 (13.4%) female patients. The average age was 24.8 years, range of 6–66 years (Fig. 1).

SPORT INVOLVED

The sport involved was association football in 110 cases (44.7%), rugby football in 24 (9.8%), squash racquets in 19 (7.7%), badminton in 16 (6.5%), skiing in 9 (3.7%), tennis in 7 (2.85%), swimming in 7 (2.85%), cricket in 6 (2.4%), golf and hockey in 3 (1.2%) each, and other sports in 42 (17.1%) (Table 1). Other sports included combat sports such as boxing, wrestling, karate, and judo; also in this group were netball, basketball, table tennis, jogging, horse riding, fishing, darts, water

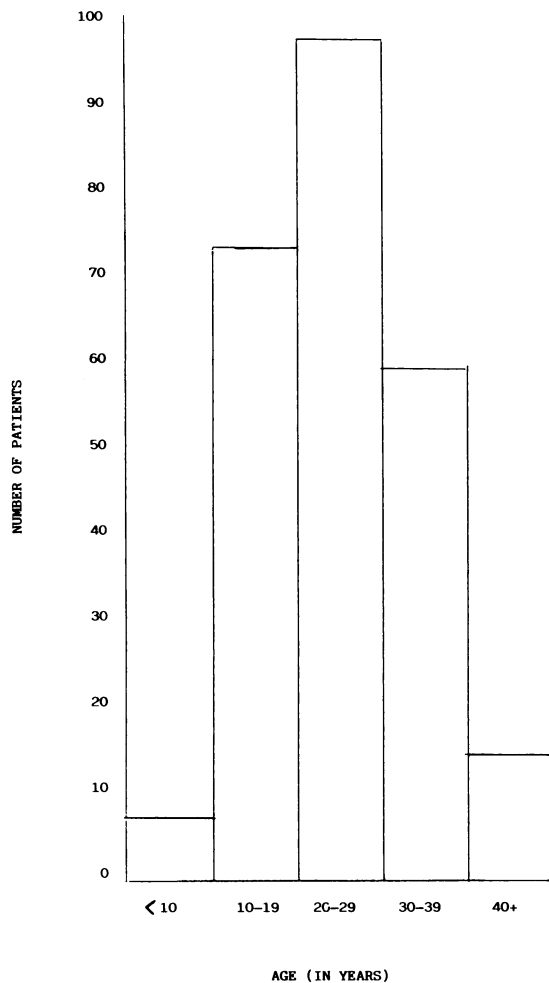


Fig. 1 Age distribution of injured patients.

skiing, sailing, shinty, and handball. No patient received an injury to more than one eye. One patient presented on two separate occasions during the study period, on each occasion with a superficial injury incurred while playing rugby football.

AETIOLOGY

The mechanisms of injury were well documented and may be divided into the following five categories (Table 2): ball to eye contact; racquet or bat to eye contact; body to eye contact; introduction of a foreign material into the eye; the participant may fall over, striking the eye or head.

Ball contact accounted for 118 (48%) of all injuries. This mechanism was most common in those sports played with a small ball, in particular the racquet sports (squash, badminton, tennis), golf, and cricket; however, the majority of football injuries were also sustained in this way. Body contact, either

Table 2 Mechanism of injury in relation to sporting activity

	Ball	Body	Racquet/ bat	Foreign body	Fall
Association football	65	35	NA	9	1
Rugby football	3	19	NA	2	-
Squash	15	-	3	1	-
Badminton	14	-	2	-	-
Skiing*	NA	2	NA	-	4
Tennis	7	-	-	-	-
Swimming	NA	5	NA	2	-
Cricket	5	-	1	-	-
Golf	2	-	-	1	-
Hockey	-	-	2	1	-
Others	7	11	2	20	2
Total	110 (48%)	72 (29.3%)	10 (4.2%)	36 (14.6%)	7 (2.8%)

*Three skiers had ultraviolet injury. NA = not applicable.

Table 1 Type of eye injury in relation to sporting activity

	Periorbital injury	Conjunctival haemorrhage or laceration	Corneal abrasion	Traumatic uveitis	Hyph- aema, aema, mydriasis iris tear	Hyph- aema, angle recession	Diffuse blunt trauma	Retinal oedema	Tear, detach- ment	Scleral rupture	Intra- cranial	Total
Association football	19	6	44	11	9	2	7	10	2	-	-	110
Rugby football	1	8	8	3	1	-	2	-	-	1	-	24
Squash	4	2	5	3	3	1	-	1	-	-	-	19
Badminton	3	-	3	4	2	4	-	-	-	-	-	16
Skiing	2	1	3	1	-	-	-	-	1	-	1	9
Tennis	1	1	2	-	-	2	-	1	-	-	-	7
Swimming	-	3	4	-	-	-	-	-	-	-	-	7
Cricket	5	-	1	-	-	-	-	-	-	-	-	6
Golf	1	-	1	-	-	-	-	-	1	-	-	3
Hockey	1	-	1	-	1	-	-	-	-	-	-	3
Others	7	6	19	2	5	-	-	-	1	1	1	42
Total	44	27	91	24	21	9	9	12	5	2	2	246

with self or opponent, accounted for 72 (29.3%), and entry of a foreign body into the eye was responsible for a further 36 (14.6%). Racquet or bat contact was responsible for 10 injuries (4.1%), and a fall striking the head or eye accounted for another 7 (2.8%). The remaining 3 (1.2%) injuries were all caused by ultraviolet light in skiers, leading to corneal epithelial oedema ('snow blindness') or herpetic keratouveitis.

OCULAR DAMAGE

The majority of injuries were superficial (65.8%), but a significant number of patients had intraocular damage (Table 1). Forty-six patients (18.7%) required admission to hospital, though one refused admission and further follow-up. The remainder were treated as outpatients; 96 (39%) were seen only at the initial presentation with a further 104 (42.3%) requiring outpatient follow-up.

There were 91 cases (37%) of corneal abrasion, and, of these, three subsequently required treatment for recurrent corneal erosion. In one case corneal damage was caused when lime from the side markings on a football pitch entered the conjunctival sac. There was delay in seeking medical advice, and the resultant corneal ulcer was resistant to treatment.

Uncomplicated traumatic uveitis occurred in 24 cases (9.8%) and hyphaema in 30 (12.2%), of which nine (3%) subsequently displayed angle recession. Of these cases six had a significant rise in intraocular pressure, four settled spontaneously, but one required trabeculectomy and the other is maintained on medical treatment. Two patients had a second bleed while in hospital.

Nine patients (3.7%) with severe, diffuse, blunt trauma involving both the anterior and posterior segments had various combinations of hyphaema, angle recession, cataract, vitreous haemorrhage, retinal haemorrhage, retinal tear, retinal oedema, and optic nerve damage. It is noteworthy that this group did well, eight retaining acuity of 6/12 or better. One eye had no perception of light for 24 hours following injury, but this improved to 6/12 within 48 hours. The others displayed persisting evidence of trauma in the form of vitreous debris, abnormal retinal pigmentation, or posterior sub-capsular lens opacities. One eye ended up with an acuity of 3/60 due to optic nerve damage.

Three retinal detachments involving the macula were all successfully reattached, but acuities remained poor at 6/24, 6/36, and counting fingers. Two eyes had symptomatic retinal tears which were successfully treated with cryotherapy, with or without plombage; both retained 6/6 vision. Two eyes (0.8%) had extensive scleral rupture, both of which culminated in enucleation of the affected eye. One patient had got an opponent's finger in the eye while

playing rugby and the other was involved in a freak whiplash accident while water skiing. Two patients presented because of complications of intracranial damage; one had a transient hemianopia and the other a fourth nerve palsy following blunt head trauma.

Ocular motility problems arose in three patients. Two had severe periorbital bruising, but no fracture could be demonstrated either radiographically or clinically. Both patients gradually improved over the ensuing months, though one still had asymptomatic limited adduction of the affected eye. One fourth nerve palsy recovered spontaneously. There were two blowout fractures, neither of which suffered diplopia or enophthalmos, though one had surgical emphysema.

PROTECTION

Specific mention of protective eye wear was made in only two cases. These were swimming goggles in both instances, and it was these goggles which were responsible for the eye injury, having slipped out of wet hands into the eye. Of the three skiers with ultraviolet injury one had lost his sun glasses and the other two had omitted to wear them. There was no record of ultraviolet protection in the other skiers. Five patients were wearing glass corrective lenses which had shattered, all the patients sustaining superficial lacerations or abrasions to the lids or cornea. Three patients suffered corneal abrasions while wearing contact lenses.

FINAL ACUITIES

The final visual acuity was 6/6 or better in 200 cases (81.3%). Only two eyes were left with acuities of less than 6/60, a further two eyes were enucleated, and one patient was lost to follow-up (Table 3).

Table 3 Final corrected visual acuity

<i>Final visual acuity</i>	<i>Eyes (%)</i>
6/6 or better	200 (81.3%)
6/9-6/12	37 (15.1%)
6/18-6/60	4 (1.6%)
Less than 6/60	2 (0.8%)
Enucleated	2 (0.8%)
Lost to follow-up	1 (0.4%)

Discussion

Sport associated eye injuries occur during a variety of different sporting activities. The mechanisms by which they occur may usefully be divided into five groups: ball contact; racquet or bat contact; body contact; foreign body; and falling over. Ball contact accounted for the majority of injuries overall in this

series and was particularly common in the racquet sports (squash, badminton, tennis). The close relationship between the size of the squash ball and the orbital aperture has roused particular interest in this activity as a cause of serious eye injury,^{2,4,5} though racquet and body contact are also common.^{3,6,7} Badminton, golf, tennis, and hockey usually involve injuries caused by ball or racquet/bat contact,^{4,7,9-12,20} whereas body to eye contact is usually responsible for injuries in boxing, rugby football, association football, and karate.^{15,16,20} Foreign material may enter the eye in any sport. This seems to be the commonest cause of injury in the recently popularised jogging and aerobics, though excessive body movements in these activities have been responsible for self-induced body to eye contact. Introduction of foreign body material normally results in superficial mechanical damage. However, materials capable of producing toxic effects, such as lime from the line markings as illustrated in the study, may also be introduced, causing more severe effects. Injury by falling over is most likely to occur in sports where the participant is travelling at speed, for example skiing and horse riding.

Football has not previously been considered as a major cause of serious sport associated eye injury. This study, however, has shown that it is the commonest cause of sport associated eye injury in the west of Scotland. This is undoubtedly a function of the popularity of football in this area. In comparison a study from Ireland²⁰ showed hurling to be the most dangerous pastime. The football has previously been considered too large to enter the orbital aperture and therefore rarely to cause damage to the eye itself,² yet significant intraocular problems occurred in 49% of those injured with a football in this study.

Many injuries considered trivial or superficial may nevertheless progress to a more serious or long lasting effect, such as recurrent corneal erosion or ocular motility problems caused by periorbital bruising and adhesions. There is also a large group of more severe injuries, usually involving the anterior segment, resulting in hyphaema, traumatic uveitis, and/or angle recession. Long-term follow up is essential to determine the prognosis in these eyes. Extensive injury is not common, but retinal damage, optic nerve dysfunction, and disruption of the globe are all recorded in this study, each resulting in loss of acuity and of the affected eye in two cases.

Sport associated eye injuries are preventable.¹⁸ None of the injured patients in this study were noted to be wearing suitable eye protection (except two swimmers). Face and eye protection has been shown to be of value in hockey and squash^{18,19} and is available commercially. In tennis and badminton corrective glass spectacles do provide some pro-

tection,⁷ but it is now thought that during any sport plastic safety glasses should be worn (with or without correction). Skiers should always wear protection against ultraviolet light. Swimming goggles should be fixed to the face with a non-elastic strap to prevent them springing backwards into the eye.¹⁴

Devising suitable eye protection for use while playing football (rugby or association) is a more difficult problem, as by their very nature these games would require protective gear which would have to be firmly fixed to the head, and any suitable device may inadvertently injure other players or encourage the use of the head as a weapon. Furthermore, compelling players to wear any such protector would be impossible, as many youngsters participate in football on an unsupervised or informal basis.

Although these 246 cases represent only 1.1% of the total of 26 609 new patients seen in this combined casualty department over the 18-month study period, they represent a significant number of preventable injuries in a young population.

In summary, most sport associated eye injuries are relatively minor and can be treated on an outpatient basis. However, a significant number result in more serious damage which may threaten sight. This is an unacceptable price to pay in the pursuit of fitness and relaxation.

I would like to thank the Casualty Department nursing staff for their co-operation, and Miss Clare Doran for typing the manuscript.

References

- 1 Vinger PF, Hoerner EF, eds. *Sports injuries: the unthwarted epidemic*. Littleton: PSG Publishing Co., 1981.
- 2 Anonymous. A ball in the eye. (Editorial.) *Br Med J* 1973; ii: 195-6.
- 3 Ingram DV, Lewkonja I. Ocular hazards of playing squash rackets. *Br J Ophthalmol* 1973; 57: 434-8.
- 4 Barrell GV, Cooper PJ, Elkington AR. Squash ball to eye ball: the likelihood of squash players incurring an eye injury. *Br Med J* 1981; 283: 893-5.
- 5 Bankes JLK. Squash rackets: a survey of eye injuries in England. *Br Med J* 1985; 291: 1539.
- 6 Davey JB. Eye injuries in the game of squash. *Optometry Today* 1986; April: 236-40.
- 7 Vinger PF, Tolpin DW. Racket sports. An ocular hazard. *JAMA* 1978; 239: 2575-7.
- 8 Blonstein JL. Eye injuries in sport with particular reference to squash and badminton. *Practitioner* 1975; 215: 208-9.
- 9 Chandran S. Ocular hazards of playing badminton. *Br J Ophthalmol* 1974; 58: 757-60.
- 10 Millar GT. Golfing eye injuries. *Am J Ophthalmol* 1967; 64: 741-2.
- 11 Vinger PF. Ocular injuries in hockey. *Arch Ophthalmol* 1967; 94: 74-6.
- 12 Elliot AJ, Jones D. Major ocular trauma; a disturbing trend in field hockey injuries. *Br Med J* 1984; 289: 21-2.
- 13 Duke M. Tennis players and eye injuries. *JAMA* 1976; 236: 2287.
- 14 Jonasson F. Swimming goggles causing severe eye injuries. *Br Med J* 1977; ii: 881.
- 15 Boshoff PM, Jokl E. Boxing injuries of the eyes. *Arch Ophthalmol* 1948; 39: 643-4.

- 16 Burstein F. Ocular injuries in sports. *J Sports Med* 1963; **3**: 25–30.
- 17 Elkington AR. Boxing and the eye. *Trans Ophthalmol Soc UK* 1985; **104**: 898–902.
- 18 Vinger PF. Sports-related eye injury. A preventable problem. *Surv Ophthalmol* 1980; **25**: 47–51.
- 19 Vinger PF. Eye Injuries. In: Vinger PF, Hoerner EF, eds. *Sports injuries: The unthwarted epidemic*. Littleton: PSG Publishing Co., 1981: 122–46.
- 20 Kelly S, Nolan J. Eye injuries in organised sport in a rural area. *Br J Ophthalmol* 1983; **67**: 837–9.

Accepted for publication 26 September 1986.