

High incidence of corneal epithelium antibodies in Fuchs' heterochromic cyclitis

E LA HEY, G S BAARSMA, A ROTHOVA, L BROERSMA,
R VAN DER GAAG, AND A KIJLSTRA

From the Netherlands Ophthalmic Research Institute, Amsterdam

SUMMARY Sera obtained from 26 patients with Fuchs' heterochromic cyclitis were examined for the presence of autoantibodies directed against the anterior segment of the eye by means of immunofluorescence techniques. Antibodies against human iris tissue could not be detected, whereas autoantibodies against corneal epithelium were found in almost 90% of cases. This is the first report describing the presence of autoantibodies in patients with Fuchs' heterochromic cyclitis and it provides a further clue that immunological mechanisms might play an important role in the aetiology of Fuchs' heterochromic cyclitis.

Fuchs' heterochromic cyclitis is a relatively rare condition. According to Dernouchamps¹ it accounts for approximately 3% of all cases of uveitis. In 90% of the patients only one eye is affected.

The diagnosis is sometimes difficult, especially in the early stages of the disease. According to Fuchs² the essential features are a low grade cyclitis, including a variable degree of iris stroma atrophy, starting in the pupillary margin and causing depigmentation of the stroma. In later stages the iris pigment epithelium also becomes affected. Further clinical findings are the absence of synechiae and the presence of scattered, small, translucent keratic precipitates. Most of the patients visit the ophthalmologist with complaints of reduced vision which are caused by cataract formation or vitreous opacities.

The major causes of visual loss in heterochromic cyclitis are cataract and progressive glaucoma. Because glaucoma is a rare complication (15% of cases),³ and cataract extraction results in the restoration of clear vision, the prognosis may be good.⁴

Various theories have been proposed to explain the aetiology of Fuchs' heterochromic cyclitis. Electron microscopic studies of iris biopsies from patients with the disease reveal a decreased number of melanocytes with relatively few, small melanin granules.⁵ Earlier EM studies⁶ and light microscopic studies⁷ showed the presence of plasma cells and lymphocytes in the irides of these patients. The

keratic precipitates, which are so typical of this disease, have been shown to represent an accumulation of lymphocytes.⁸ Analysis of the aqueous humour from patients with this disease showed intraocular production of immunoglobulins; furthermore rheumatoid factor (RF) and immune-complex-like material could be detected.⁹ These observations strongly suggest involvement of an immunological process in the pathogenesis of the disease.

To investigate the role of the immune system in this disease we examined the incidence of autoantibodies directed against the anterior segment of the eye. No antibodies could be detected against iris or ciliary body, but surprisingly a high percentage of patients (88%) had antibodies against corneal antigens.

Materials and methods

Sera were obtained from 26 patients with Fuchs' heterochromic cyclitis (13 males and 13 females, average age 37 years) visiting the eye clinics of the universities of Amsterdam and Rotterdam. The diagnosis was made when a patient presented with a low-grade uveitis characterised by the absence of synechiae, and more or less iris (stroma) atrophy with or without heterochromia, the typical keratic precipitates and often cataract. Thirty sera were also obtained from sex and age matched (healthy) persons without a history of ocular inflammation.

Sera were tested for the presence of iris, ciliary body, or cornea antibodies by an indirect immunofluorescence technique. Human irides, collected

Correspondence to Dr A Kijlstra, Department of Ophthalmology, PO Box 12141, 1100 AC Amsterdam, The Netherlands.

from donor eyes (from which the corneas were used for transplantation) and rabbit corneas were snap frozen in liquid nitrogen. Sections ($8\ \mu\text{m}$) were cut in a cryostat, air dried on to glass slides previously

coated with gelatin (1%) plus potassium-chromium (III) sulphate (0.1%) and fixed in acetone for 10 minutes. After being washed with phosphate buffered saline (PBS) the sections were incubated

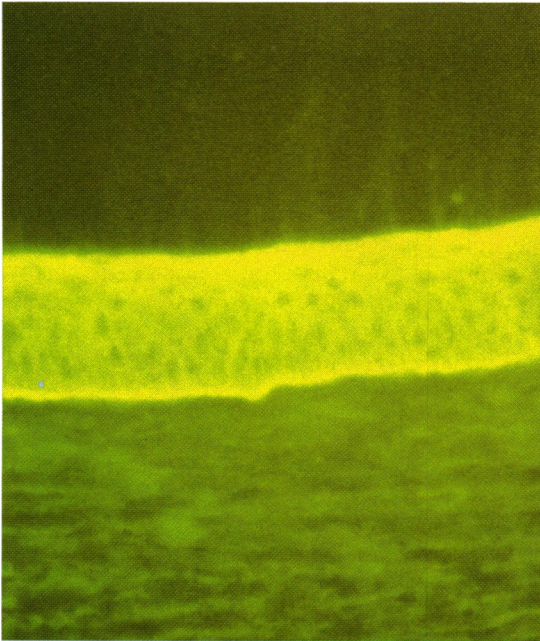


Fig. 1A

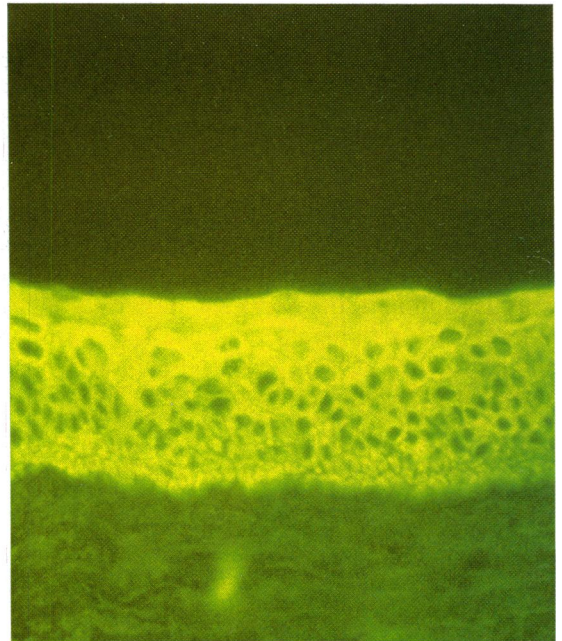


Fig. 1B

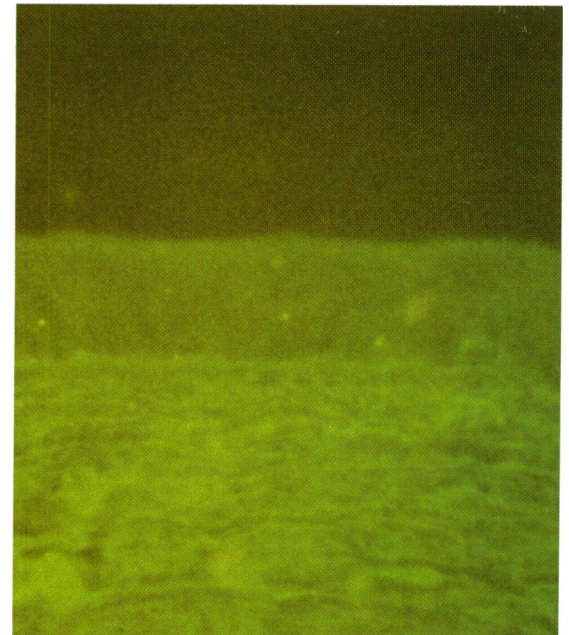


Fig. 1C

Fig. 1 A: Immunofluorescence test showing antibodies in the serum of a patient with Fuchs' heterochromic cyclitis reacting with corneal epithelium. B: Positive serum of a healthy control. C: Negative serum of a healthy control.

Table 1 Antibodies to corneal epithelium in Fuchs' heterochromic cycliitis as tested by immunofluorescence

	Immunofluorescence score*			Percentage positive
	++	+	-	
Fuchs' patients (n=26)	18	5	3	88
Healthy controls (n=30)	1	0	29	3

*Tissue sections showing corneal epithelium antibodies after incubation with patient sera were scored by the following classification: strongly positive ++, positive +, negative -. The numbers indicate the number of patients.

with a 1/10 dilution of patient or control serum in PBS for 30 minutes at room temperature. Subsequently the slides were washed three times for 10 minutes with PBS and incubated for 30 minutes in the dark at room temperature with a polyclonal, FITC conjugated goat antihuman immunoglobulin (GAHuIg-FITC, Nordic, The Netherlands) or a monoclonal, FITC conjugated mouse antihuman IgG (MoAHuIgG-FITC, CLB, The Netherlands) (both diluted 1/40 in PBS). The slides were washed thoroughly and embedded in a solution of glycerin and PBS (1:1).

Human sera containing antinuclear antibodies were used as positive controls. Tissue sections incubated with PBS instead of human sera served as negative controls.

The slides were scored in a masked fashion by two different investigators, unaware whether patient or control sera were being used, with a Leitz fluorescence microscope using the following classification: strongly positive: ++, positive: +, negative: -.

Results

In the majority of patients with Fuchs' disease (88%; 23 out of 26) antibodies directed against corneal epithelium could be detected by the immunofluorescence test (IFT), whereas only one control person out of 30 had corneal antibodies (3%) (Table 1). The immunofluorescence pattern of this control person showed only cytoplasmic staining, while all the Fuchs' disease sera showed both cytoplasmic and membrane staining (Fig. 1).

Titration of the patients sera by a strong positive immunofluorescence test showed that corneal epithelium antibodies could still be detected up to a 1/40 serum dilution.

Some sera from patients with Fuchs' disease were also tested with a human cornea and a mouse cornea. These experiments showed similar results as those seen with rabbit corneas and are in agreement with earlier findings showing a large degree of cross reactivity between corneal antigens of different species.¹⁰

With the immunofluorescence test no antibodies could be detected in patients with Fuchs' disease (all 26 sera were tested) against normal human iris tissue. Positive control sera containing antinuclear antibodies showed a strong nuclear fluorescence staining in the iris. The detection of antibodies against human ciliary body was hindered by the fact that there was a strong background staining of endogenous immunoglobulins near the basement membrane and to a lesser degree also in the stroma (Fig. 2). This was apparent in control experiments whereby the tissue was incubated with phosphate buffered saline instead of human serum and subsequently

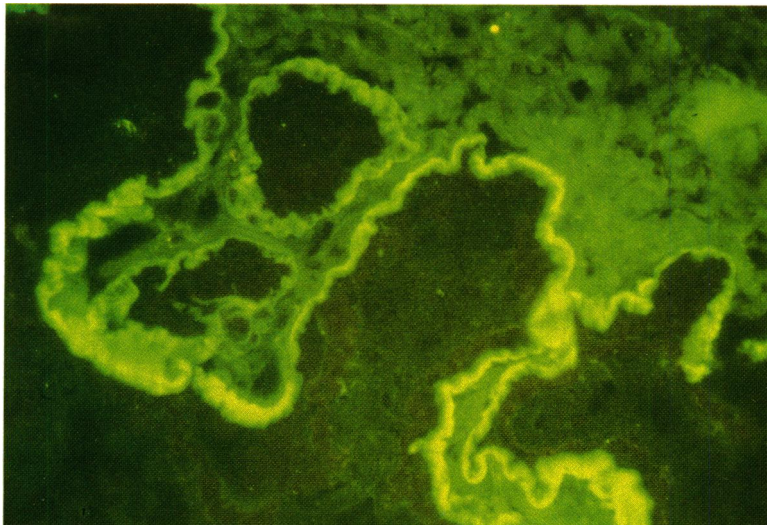


Fig. 2 Incubation of normal human ciliary body with phosphate buffered saline followed by staining with fluorescein labelled goat antihuman immunoglobulins. Note strong staining of basement membrane.

stained with fluorescein labelled goat antihuman immunoglobulins or a monoclonal antihuman immunoglobulin.

Discussion

Our results show a high incidence of corneal epithelium antibodies in the circulation of patients with Fuchs' heterochromic cyclitis.

Although the presence of circulating corneal epithelium antibodies has also been reported in other forms of uveitis, the incidence seen in patients with Fuchs' disease (88% positive) is much higher than that reported in other groups.^{11,12} The incidence is 42% in anterior uveitis and 30% in posterior uveitis. The frequency of corneal epithelium antibodies in healthy controls was 3% in this study and is similar to that reported earlier.¹¹ Other recent investigations¹³ into the presence of serum autoantibodies (which comprised smooth muscle, nuclear material, gastric parietal cell, reticulin, and mitochondria) in uveitis showed no difference between controls and patients with Fuchs' heterochromic cyclitis. Corneal epithelium antibodies are thus the first autoantibodies found in almost all patients with this disease, a finding which to our knowledge has not been reported earlier.

No antibodies could be detected against human iris. The assay for antibodies against human ciliary body was not possible because this tissue already contains large deposits of immunoglobulins near the basement membrane and stromal regions. These findings are in agreement with recent investigations¹⁴ showing that cationic immunoglobulins traverse the fenestrated capillaries in the ciliary body and bind to anionic sites within this tissue.

The detection of autoantibodies directed against a corneal layer not involved in Fuchs' cyclitis may appear puzzling at first sight. The corneal epithelium, however, contains a number of antigens which are shared with the corneal stroma and endothelium.¹⁵⁻¹⁷ This layer is often involved in Fuchs' cyclitis, as shown by the small keratic precipitates which have been identified as accumulations of lymphocytes. These lymphocytes may be directed against certain antigens expressed or secreted by corneal endothelial cells. Furthermore it has been shown that the corneal epithelium shares antigens with the iris, ciliary body, and lens epithelium.^{10,15-18} The fact that autoantibodies directed against the cornea mainly appear as corneal epithelium antibodies when using immunofluorescence techniques on cornea sections is probably due to the higher density of these antigens in the corneal epithelium as compared with stroma or endothelium.

It is not yet clear whether the corneal auto-

immunity which was apparent in various forms of uveitis and especially in Fuchs' cyclitis is directed against the same antigen(s) or whether each entity has its own characteristic antigen. Furthermore it has not been clarified yet if the autoimmune reactions against corneal antigens have a primary role, implicating Fuchs' heterochromia as an autoimmune disease, or if these immunological reactions are a secondary phenomenon due to permeability changes in the anterior segment of the eye. The increased permeability of vessels in patients with Fuchs' disease can lead to a greater accessibility of corneal antigens to the immune system, which may result in an autoimmune response against these antigens. A possible important role of the immune system in Fuchs' heterochromic cyclitis is already apparent from the original description of plasma cells in the irides of these patients by Fuchs himself.² The accumulation of inflammatory cells on the endothelial side of the cornea is also in agreement with this hypothesis. Further evidence comes from studies by Dernouchamps,¹⁹ who revealed the intraocular production of immunoglobulins in these patients. Whether the locally produced antibodies are directed against corneal antigens remains to be investigated. Rheumatoid factor and immune-complex-like material have also been observed in the aqueous humour of these patients.⁹ The findings mentioned above in combination with our detection of corneal autoimmunity in such a high percentage of patients support the hypothesis that immunological mechanisms may play an important part in Fuchs' heterochromic cyclitis.

References

- 1 Dernouchamps JP. Fuchs' heterochromic cyclitis: an IUSG study on 550 cases. In: Saari KM, ed. *Uveitis update*. Amsterdam: Elsevier, 1984: 129-35.
- 2 Fuchs E. Ueber Komplikation der Heterochromie. *Z A Augenheilkd* 1906; 15: 14-212.
- 3 Loewenfeld IE, Thompson HS. Fuchs' heterochromic cyclitis: a critical review of the literature. *Surv Ophthalmol* 1973; 18: 2-61.
- 4 O'Connor R. Doyno lecture: Heterochromic iridocyclitis. *Trans Ophthalmol Soc UK* 1985; 104: 219-31.
- 5 McCartney ACE, Bull TB, Spalton DJ. Fuchs' heterochromic cyclitis: an electron microscopy study. *Trans Ophthalmol Soc UK* 1986; 105: 324-9.
- 6 Wobmann P. Die heterochromiecyclitis Fuchs. Elektronenmikroskopische Studie von 9 Irisbiopsien. *Graefes Arch Clin Exp Ophthalmol* 1976; 199: 167-78.
- 7 Goldberg MF, Erozan YS, Duke JR, Krost JK. Cytopathologic and histopathologic aspects of Fuchs' heterochromic cyclitis. *Arch Ophthalmol* 1965; 74: 604-9.
- 8 Perry HD, Yanoff M, Scheie HG. Rubeosis in Fuchs' heterochromic iridocyclitis. *Arch Ophthalmol* 1975; 93: 337-9.
- 9 Dernouchamps JP, Vaerman JP, Michiels J, Masson PL. Immune complexes in the aqueous humor and serum. *Am J Ophthalmol* 1977; 84: 24-31.
- 10 Kruit PJ, van der Gaag R, Broersma L, Kijlstra A. Autoimmunity against corneal antigens. I. Isolation of a soluble 54 Kd

- corneal epithelium antigen. *Curr Eye Res* 1986; **5**: 313-20.
- 11 Kruit PJ, van der Gaag R, Broersma L, Kijlstra A. Circulating antibodies to corneal epithelium in patients with uveitis. *Br J Ophthalmol* 1985; **69**: 446-8.
 - 12 Henley WL, Kong S. Antibody to corneal protein in uveitis. *Pediatr Res* 1986; **20**: 294A.
 - 13 Murray P. Serum autoantibodies and uveitis. *Br J Ophthalmol* 1986; **70**: 266-8.
 - 14 Waldrep CJ. Uveal IgG distribution: regulation by electrostatic interactions. *Curr Eye Res* 1987; **6**: 897-907.
 - 15 Silverman B, Alexander R, Henley WL. Tissue and species specificity of BCP 54, the major soluble protein of bovine cornea. *Exp Eye Res* 1981; **33**: 19.
 - 16 Eype AA, Kruit JP, v d Gaag R, Neuteboom GHG, Broersma L, Kijlstra A. Autoimmunity against corneal antigens. II. Accessibility of the 54 Kd corneal antigen for circulating antibodies. *Curr Eye Res* 1987; **6**: 467-75.
 - 17 Whiteside TL, Hamada S, Manski WJ. Immunochemical analysis of tissue antigens in different corneal layers and sclera. *Exp Eye Res* 1973; **16**: 413-20.
 - 18 Brinkman CJJ, Oerlemans-van Zutphen MPJ, Broekhuysse RM. Ocular antigens IX. Demonstration of common antigenicity in corneal epithelium and other tissues of the bovine eye. *Exp Eye Res* 1987; **27**: 81-6.
 - 19 Dernouchamps JP. The proteins of the aqueous humor. *Doc Ophthalmol* 1982; **53**: 193-248.

Accepted for publication 22 September 1987.