

Dynamic nature of posterior subcapsular cataract

G ADRIEN SHUN-SHIN, NICHOLAS P BROWN, ANTHONY J BRON,
AND JOHN M SPARROW

From the Nuffield Laboratory of Ophthalmology, University of Oxford

SUMMARY Posterior subcapsular cataracts were studied in 10 patients (19 eyes) and were photographed at four to 12 weeks intervals by the Oxford Retroillumination Camera. Changes in the fine structure of PSC may occur in as short a time as four weeks. Posterior subcapsular cataracts are shown to be in a state of flux and are not, as might be assumed, slowly but relentlessly progressive. This could imply the existence of a repair mechanism in the lens.

Posterior subcapsular cataract (PSC) in the absence of any other form of lens opacities is relatively uncommon. In the Framingham Study isolated PSC occurred in 2.1% of a population aged 52 to 85 years old.¹ PSC occur in a wide variety of conditions. Eshagian lists 38 associations.² Its histopathology has been well described.^{3,5} Quantitative microradiography has demonstrated marked shifts in protein concentration at the junction of normal lens fibres and PSC, creating scattering interfaces.⁶ PSC have been studied by the Scheimpflug slit-image camera. Lenses with PSC have been shown to be smaller than normal and to be associated with a small or absent anterior clear zone.⁷

However, there does not exist to our knowledge any study of the fine morphological changes that might occur with time in PSC. The present study was designed to study changes with time in their fine morphology. Lenses with PSC were photographed by the prototype Oxford retroillumination camera after full pupillary dilatation.^{8,9}

Material and methods

APPARATUS

Fincham¹⁰ described a method of photographing opacities of the ocular media by retroillumination photography. His apparatus was mounted on a slit-lamp and was provided with a deep orange filter (Ilford Micro 5) in order to increase the contrast on black-and-white film.

In 1980 Kawara and Obazawa¹¹ improved on Fincham's system. A pair of cross polarisers was used

Correspondence to G Adrien Shun-Shin, FRCS, Nuffield Laboratory of Ophthalmology, Walton Street, Oxford OX2 6AW.

to minimise the corneal reflection. A fixation light was placed in front of the eye which was not being photographed. They found that the position of maximum retroillumination occurred when the optic disc, acting as a reflector, lay in the illuminating beam. Repeatability is sometimes difficult with this method.

Brown and colleagues have described the Oxford retroillumination camera.^{8,9} It has two features of note. First a neutral density standard is incorporated into the system to allow, by image analysing techniques, comparison of density changes occurring in sequential photographs. Second, it has fixed fixation lights placed in front of the eye being photographed. These fixation lights are offset by 15.5° horizontally and 1.5° vertically to the illuminating beam. In the average eye this brings the optic disc into the illuminating beam and thus automatically provides maximum retroillumination. This system of fixed fixation lights allows repeatability of results.

In this study the prototype Oxford retroillumination camera was used. It was mounted on a Zeiss photoslit lamp, and the Zeiss flash unit was used.

SELECTION OF PATIENTS

Ten patients with PSC only or PSC with a minimal degree of other cataract insufficient to interfere with photography of the PSC were selected from patients attending the Clinical Cataract Research Unit in Oxford. No patients were diabetic. They had either age related PSC (three patients) or had undergone renal transplantation (five patients) or total body irradiation prior to bone marrow transplantation in the past (two patients). There were 19 eyes in total. The mean age of patients was 60 years, range 25 to 79 years.

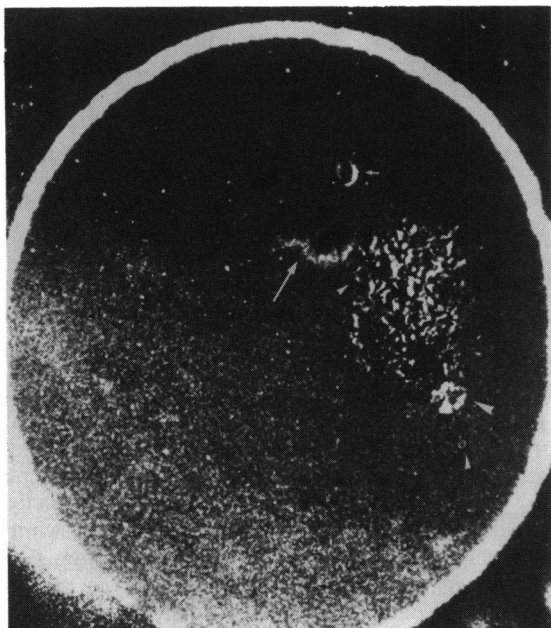


Fig. 1a Subtraction photograph of Fig. 1b and Fig. 1c.

METHOD

The pupils were dilated with phenylephrine 10% drops and tropicamide 1% drops in order to obtain a pupil diameter of 7 to 8 mm. The lenses were graded by the Oxford Clinical Cataract Classification

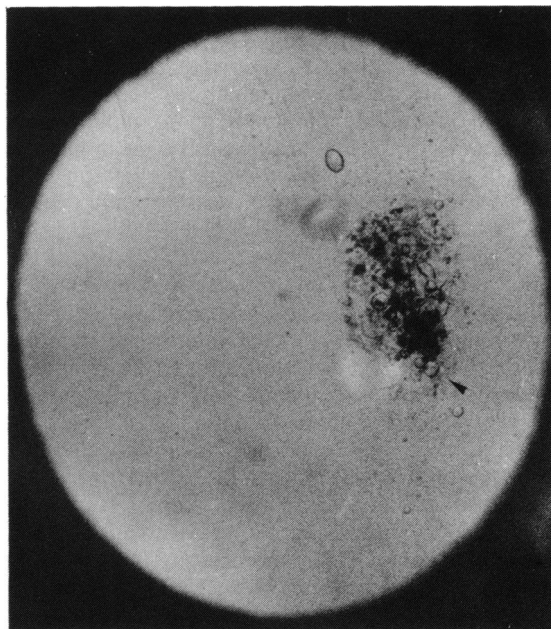


Fig. 1c Retroillumination photograph of same eye as Fig. 1b photographed six weeks later.

System.¹² This is a slit-lamp based, in-vivo system. Posterior subcapsular cataracts in this system are graded according to diameter: grade 0 represents no PSC and grade 5 a PSC occupying 81% to 100% of an 8 mm diameter pupil. This classification of PSC has a weighted kappa value of 0.81 and 0.86 inter- and

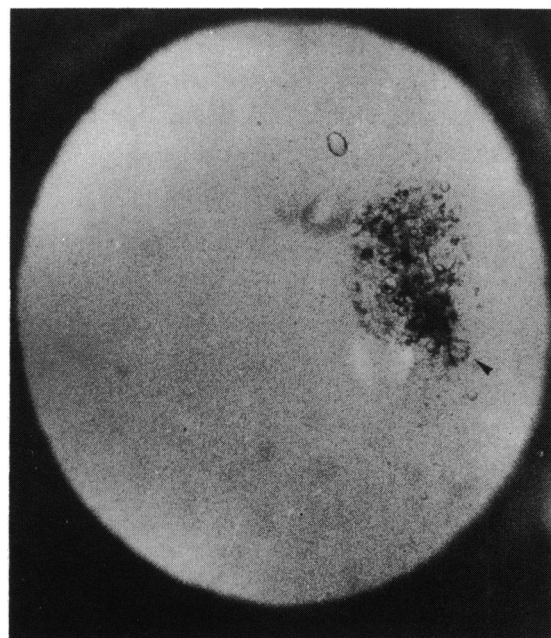


Fig. 1b Retroillumination photograph.

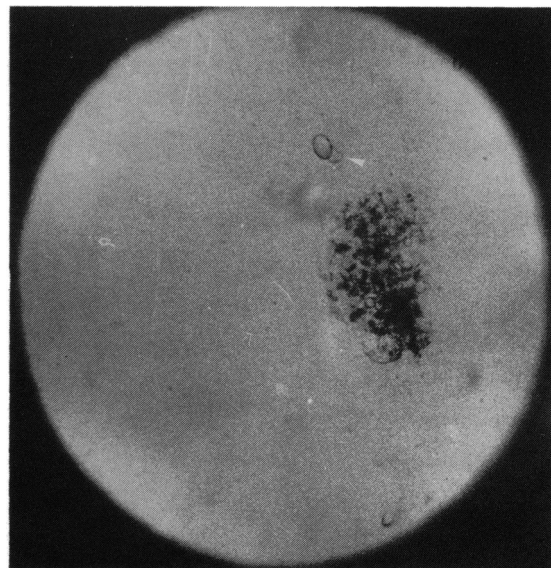


Fig. 1d Retroillumination photograph of same eye as Fig. 1b photographed eight weeks after Fig. 1c.

intraobserver variation respectively.¹³ In this study one eye was grade 1, six eyes were grade 2, 10 eyes were grade 3, and two eyes were grade 4.

The Oxford Retroillumination Camera was focused on the PSC. They were photographed again at intervals of four to 14 weeks. The mean interval was 10 weeks. Four patients were photographed on two occasions, five on three occasions, and one on four occasions.

Sequential pairs of negatives of PSC taken of the same eye at different time intervals were projected at 20 times magnification on a grid. Each square in the grid was examined, and the number of vacuoles which had disappeared completely and the number of new vacuoles were counted. Only vacuoles greater than 50 μm were counted.

As no account was taken of vacuoles which had changed in size or shape in the part of the study described in the preceding paragraph, an attempt was made to analyse morphological changes within the PSC by subtraction photography. Ten pairs of negatives were examined by the technique of subtraction photography. In practice it was difficult to obtain exact superimposition of the pairs. Thus subtraction photography was of value only as a guide to areas of maximum change. The original set of negatives was always examined in order to confirm that the changes suggested by the subtraction were not artefactual. Subtraction photography was found to be useful only for illustrative purposes. Computerised image analysis may allow objective quantification of changes in PSC in future.

Results

In all cases changes in the fine structure of PSC were seen. Vacuoles could be identified which appeared and disappeared with time. On average four new vacuoles appeared and three old vacuoles disappeared per month. The range was one to six. There were not enough pairs to draw any statistically significant conclusions, but it seemed that the rate of change was not related to the size of the PSC. However, it would seem that the more vacuolated the PSC the greater the rate of change as defined in the preceding section.

Fig. 1a is a subtraction photo of a pair of photographs (Figs. 1b and 1c) taken at a six-week interval. It suggests that the area of maximal change was at the inferior tip of the triangular shaped PSC indicated by the large white arrowhead. The vacuoles indicated by the small white arrowhead have been correctly superimposed. The vacuole with the small white arrow has a dark shadow to its left suggesting that there might have been a small shift of one of the subtraction pairs relative to the other. However, the complex with the large white arrow has its dark shadow to its right, and this militates against any shift having occurred. This is thus an example of an acceptable superimposition of negatives. Figs. 1b and 1c are the original pair from which the subtraction picture was taken. It is to be noted that the vacuoles (arrowed) at the inferior tip of the PSC have changed. This change has occurred in six weeks. The surrounding features are similarly in focus in the two

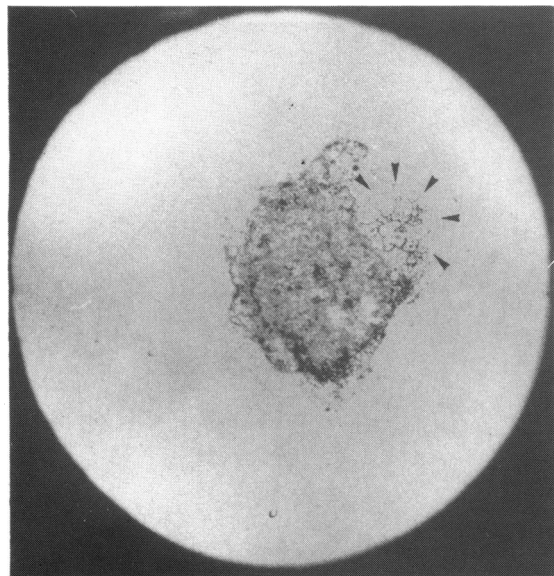


Fig. 2a Retroillumination photograph taken June 1987.

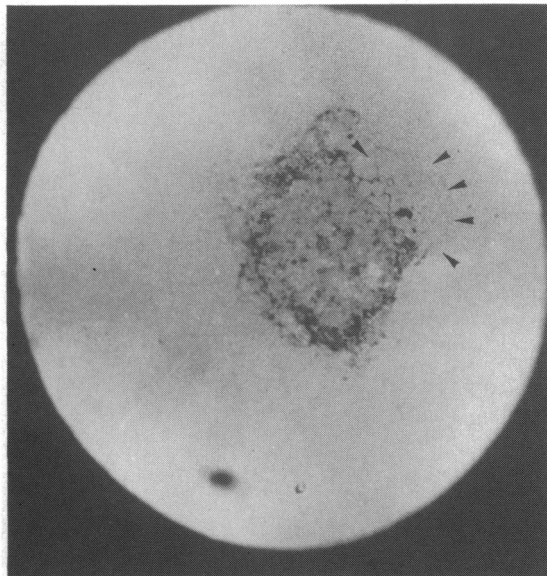


Fig. 2b Retroillumination photograph of same eye as Fig. 2a taken July 1987.

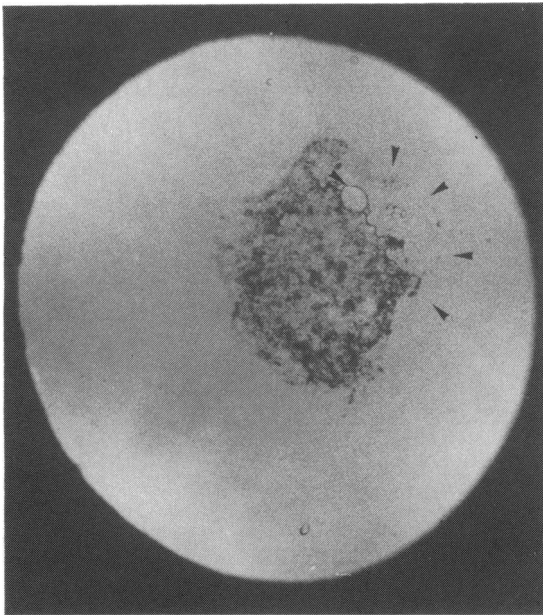


Fig. 2c Retroillumination photograph of same eye as Fig. 2a taken August 1987.

photographs, showing that the changes occurring are not an artefact caused by differing plane of focus. Fig. 1d was taken eight weeks later. The appearance of a new vacuole is indicated by the white arrow.

Figs. 2a, b, and c are from the same eye taken in June, July, and August. The area arrowed in Fig. 2a shows the vacuoles which make up the structure of the PSC. Within the short space of one month these vacuoles start to break up and disappear as shown in Fig. 2b. A new, optically denser and solid-looking structure appears. Fig. 2c shows the situation a further month later. The dense opacity has increased in size and there is further break-up of the vacuolar structure of the PSC. The diameter of the larger vacuoles is about 300 μm .

POSSIBLE SOURCES OF ERROR

Fixation loss. This is a potential source of error. The camera back used has a graticule incorporated which consists of a circle and crosshairs. There is a small corneal reflex seen during photography which is due to the reflection of light from the fixation light. When this reflex is aligned with the centre of the circle, fixation is central. In spite of this there may be an occasional fixation loss, and therefore the effect of fixation loss of the fine morphology of PSC was studied. Photographs were taken on axis and with the eye deliberately off axis by 15.5° . A 5° fixation loss is readily noticed by the photographer. The negatives were compared at 20 times magnification. Six PSC

were thus studied. There was no change in the number of vacuoles seen in the PSC. Fixation loss is therefore not a significant problem in the study of qualitative changes in PSC.

Variation in the plane of focus. As the constituents of the PSC are three-dimensional structures it is possible to induce artefactual changes in photographs by focusing at different planes. To guard against this, common features in a sequential series of photographs must be clearly identified and found to be similarly in focus before it can be said that definite change has occurred.

Repeatability of photographs. To assess the repeatability of the method retroillumination photographs of PSC were taken at separate sessions and the negatives compared.

Patients were selected on the criteria used in the dynamic nature of PSC study. The pupils of five patients (10 eyes) with PSC were dilated with phenylephrine 10% drops and tropicamide 1% drops to obtain a pupil diameter of 7 to 8 mm.

Photographs were taken with the camera accurately focused on the PSC. The PSC was rephotographed between one and 24 hours later. To assess the repeatability of the method a masked observer was shown pairs of negatives projected on to a screen at a final magnification of 90 times. The pairs were of two types. There were 10 pairs of photographs taken as described above and 10 pairs in which the same eye with a PSC had been photographed at four to 12 weeks' interval. The order of presentation was randomised. The masked observer was asked to decide whether a pair of photographs was identical (and therefore taken at an interval of one to 24 hours) or whether there was any difference between the two photographs being projected. A difference was defined as either the appearance or disappearance of a vacuole, or a change in shape of the vacuole. A diagram was made of the changes seen so that the results could be verified later.

The observer was able to identify the appearance or disappearance of vacuoles in the 10 pairs of negatives taken at an interval of four to 10 weeks. There were also differences in the size and shape of vacuoles noted. But he was unable to identify any difference in any of the 10 pairs taken at one to 24 hours. The retroillumination camera thus has a degree of repeatability sufficient for this study.

Figs. 3a and 3b were taken at a one-hour interval and illustrate the high degree of repeatability which may be obtained with the Oxford retroillumination camera.

Discussion

Posterior subcapsular cataracts are demonstrably in a

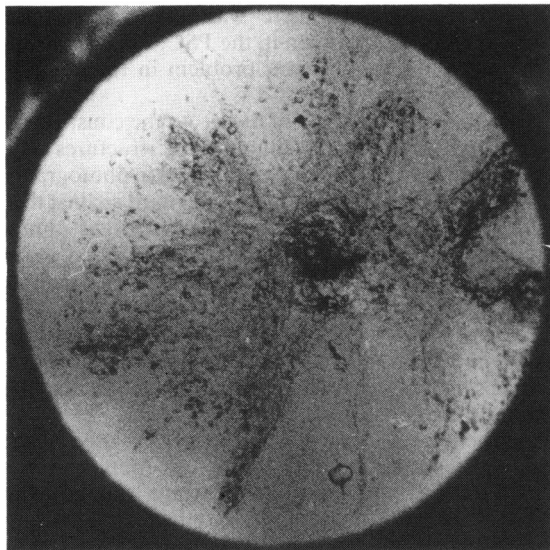


Fig. 3a *Retroillumination photograph.*

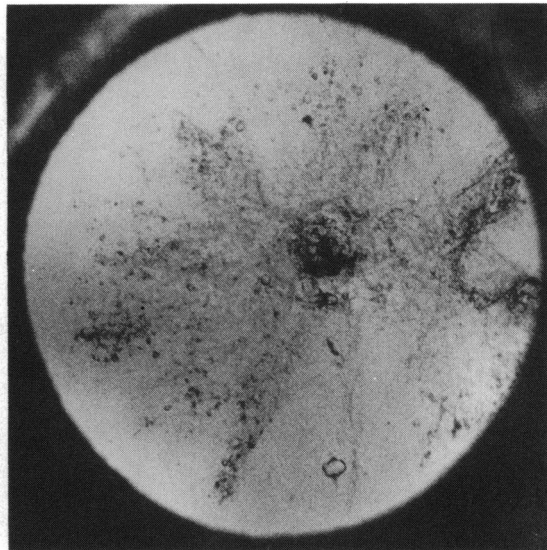


Fig. 3b *Retroillumination photograph of same eye as Fig. 3a taken one hour later.*

state of flux. Vacuoles appear and disappear continually. Sometimes they are replaced by a denser opacity.

Ultrastructural studies have suggested that the evolution of PSC is associated with fibre swelling and breakdown.⁴ In lenses with posterior subcapsular cataract a sequence has been suggested of increased or altered interdigitation of fibres, nipping off of interdigitating processes, fibre swelling, formation of intercellular and interfibre lakes and vacuoles, and total fibre breakdown.^{6,14,15} Fibre breakdown is accompanied by the formation of complex and bizarre membrane figures such as 'figure of 8' patterns and 'tramline' figures.¹⁴ Eshagian has shown that epithelial cells have prominent, rough, endoplasmic reticulum and a Golgi apparatus as they move from the equator towards the posterior pole. He concludes that this represents an increase in cell metabolic activity. Extracellular granular and fibrillary material are produced.⁵ Within this evolutionary progress could lie the explanation for the changes in density and morphology of the figures documented photographically in PSC.

Repair processes in the lens are not well recognised. We have proposed that the lens has an uncoupling mechanism which responds to injury or damage by ionically disconnecting damaged fibres from undamaged ones. This implies closure of the gap junctions which connect neighbouring fibres electrically and ionically. Furthermore it is suggested than an annealing mechanism could exist in which a part of a damaged fibre was sealed off from the rest of the fibre.¹⁶ A process might thus occur by which focal

lens opacities were compartmentalised before the whole lens fibre was involved. Vrensen and Willekens have electron-micrographic evidence for this.¹⁷ They have shown a clear demarcation line running across lens fibres and separating normal from cataractous segments. It is thought that in senile PSC the secondary migration of the lens epithelial cells may be a response to primary damage at the posterior pole of the lens and represent attempts at repair.²

Though the findings in this study that features appear and disappear could be simply explained on the basis of the evolution of cataract, they could also in part represent the occurrence of a reparative process.

CONCLUSIONS

These findings may have some relevance to our expectations for the medical treatment of cataract. The majority of cataracts are age related or 'senile' cataract. A number of potential drugs for the treatment of cataract have been proposed in recent years.^{18,19} It is likely that their use in the treatment of senile cataract will be directed to the prevention of progression in those with established lens opacities. There will be some interest in the possibility of reversing existing opacity. The dynamic features of cataract observed in this study offer some hope that this may be possible.

References

- 1 Spurduto BD, Hiller R. The prevalence of nuclear, cortical, and posterior subcapsular lens opacities in a general population sample. *Ophthalmology* 1984; **91**: 815-8.

- 2 Eshagian J. Human posterior subcapsular cataracts. *Trans Ophthalmol Soc UK* 1982; **102**: 364–8.
- 3 Greiner JV, Chylack LT. Posterior subcapsular cataracts. Histopathologic study of steroid-associated cataracts. *Arch Ophthalmol* 1979; **97**: 135–44.
- 4 Nagata M, Matsuura H, Fujinaga Y. Ultrastructure of posterior subcapsular cataract in human lens. *Ophthalmic Res* 1986; **18**: 180–4.
- 5 Eshagian J, Streeten BW. Human posterior subcapsular cataract. An ultrastructural study of the posterior migrating cells. *Arch Ophthalmol* 1980; **98**: 134–43.
- 6 Philipson BT, Fagerholm PP. Human subcapsular cataract—distribution of protein in relation to opacification. *Exp Eye Res* 1981; **33**: 621–30.
- 7 Brown N, Tripathi R. The loss of the anterior sub-capsular clear zone of the lens. Prognostic significance in cataract formation. *Trans Ophthalmol Soc UK* 1974; **94**: 29–45.
- 8 Brown NP, Dawson T. A new British ophthalmic camera. *Br J Photography* 1987; **134**: 1253–4.
- 9 Brown NAP, Bron AJ, Ayliffe W, Sparrow J, Hill AR. The objective assessment of cataract. *Eye* 1987; **1**: 234–46.
- 10 Ficham EF. Photographic recording of opacities of the ocular media. *Br J Ophthalmol* 1955; **39**: 85–9.
- 11 Kawara T, Obazawa H. A new method for retroillumination photography of cataractous lens opacities. *Am J Ophthalmol* 1980; **90**: 186–9.
- 12 Sparrow JM, Bron AJ, Brown NAP, Ayliffe W, Hill AR. The Oxford clinical cataract classification and grading system. *Int Ophthalmol* 1986; **9**: 207–25.
- 13 Sparrow JM, Ayliffe W, Bron AJ, Brown NP, Hill AR. Inter-observer and intra-observer variability of the Oxford clinical cataract classification and grading system. *Int Ophthalmol* 1988; **11**: 151–7.
- 14 Phillipson B. Changes in the lens related to the reduction of transparency. *Exp Eye Res* 1973; **16**: 29–39.
- 15 Dilley KJ, Bron AJ, Habgood JO. Anterior apolar and posterior subcapsular cataract in a patient with retinitis pigmentosa: a light-microscopic and ultrastructural study. *Exp Eye Res* 1976; **22**: 155–67.
- 16 Bron AJ, Brown NAP. Lens structure and forms of cataract. In: Duncan G, ed. *Proceedings of EURAGE-BBS symposium on the lens transparency and cataract*. Norwich: EURAGE, 1985: 3–11.
- 17 Vrensen G, Willekens B. Conservation mechanisms in cataractous human lenses: ultrastructural aspects. *Ophthalmic Res* 1988; **20**: 84.
- 18 Kador PF. Overview of the current attempts toward the medical treatment of cataract. *Ophthalmology* 1983; **90**: 352–64.
- 19 Bron AJ, Brown NAP, Sparrow JM, Shun-Shin GA. Medical treatment of cataract. *Eye* 1987; **1**: 542–50.

Accepted for publication 6 October 1988.