

# Retinal detachment in Axenfeld-Rieger syndrome

A SPALLONE

From Clinica Zucchi, Monza, Italy

**SUMMARY** Three cases of the association between the Axenfeld-Rieger syndrome and retinal detachment in one family are described. Serious damage to the posterior segment of the eye in the Axenfeld-Rieger syndrome has not previously been reported.

This study reports three cases from one family who had the Axenfeld-Rieger syndrome. They are particularly interesting because in addition to the characteristic clinical signs typical of this disorder they also have retinal detachment, in one case bilateral and in another with a giant tear. The young age at which the retinal detachment appeared in each case and the family history provided a basis for assuming that the detachment was probably hereditary. Our study of these cases raises the following question: Is it possible that the Axenfeld-Rieger syndrome is also a disease of the posterior segment of the eye?

Correspondence to Dr Attilio Spallone, via C Battisti 12, 20035 Lissone (MI), Italy.

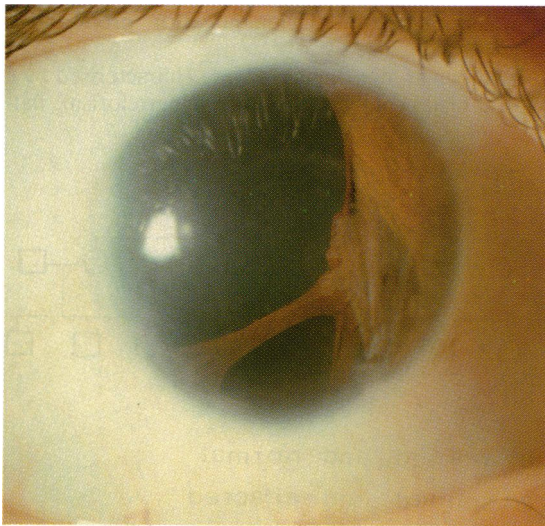


Fig. 1 Proband. Anterior segment of the right eye: partial aniridia from 7 to 12 o'clock with a full thickness hole in the inferior quadrant.

## Case reports

### CASE 1

The proband, a boy 14 years old, was referred to us for sudden blurred vision in his left eye. His parents were unrelated. His visual acuity was 0.1 in the right eye with  $-8$  sph and counting fingers in the left eye with  $-9$  sph. In the right eye ocular examination showed microcornea (8.5 mm) and partial aniridia from 7 to 12 o'clock, with a full thickness hole in the inferior quadrant (Fig. 1). Gonioscopic examination showed clearly a prominent Schwalbe's line and a band of transparent tissue attached to the peripheral cornea from the 3 to 4 o'clock position. From 8 to 12 o'clock iris processes were visible, and the iris was here present only as an iris root.

The patient had suffered from glaucoma for six years, and in fact even with topical therapy the ocular pressure in this eye was 32 mmHg. The right fundus showed a myopic crescent on the pale optic disc and an abrupt termination of the temporal retinal vascularisation at the equator.

External examination of the left eye showed a diagonal orientation of the ectopic pupil, with stromal iridic defects in the 3 o'clock position. The Schwalbe's anterior border ring was prominent from 3 to 9 o'clock. A small remnant of iris tissue was visible in the pupillary space (Fig. 2). Gonioscopic examination showed clearly the prominent Schwalbe's line, and iris processes were visible in the 6 o'clock position. Partial aniridia was present from 1 to 3 o'clock. Ocular pressure in the left eye was 5 mmHg. But the most unusual aspect was visible in the ocular fundus, which showed a retinal detachment with a giant tear extending for  $270^\circ$  from 9 to 6 o'clock (Fig. 3).

Non-ocular abnormalities consisted of a characteristic facial configuration with hypertelorism, flattening of the mid-face, a thin upper lip, and a protruding

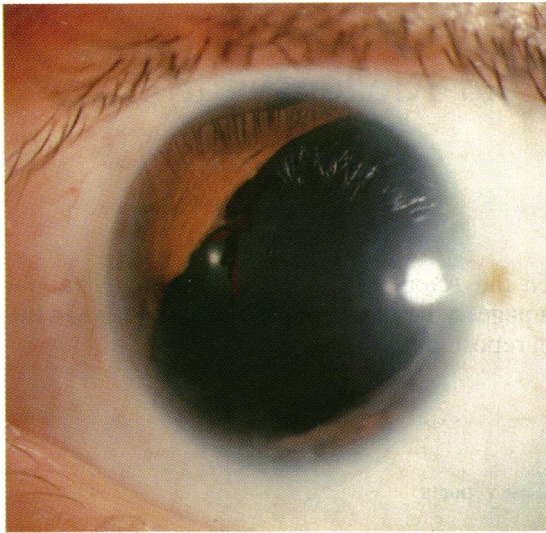

Fig. 2 Proband. Anterior segment of the left eye: diagonal orientation of the ectopic pupil, and a small remnant of pigmented iris tissue in the pupillary space.

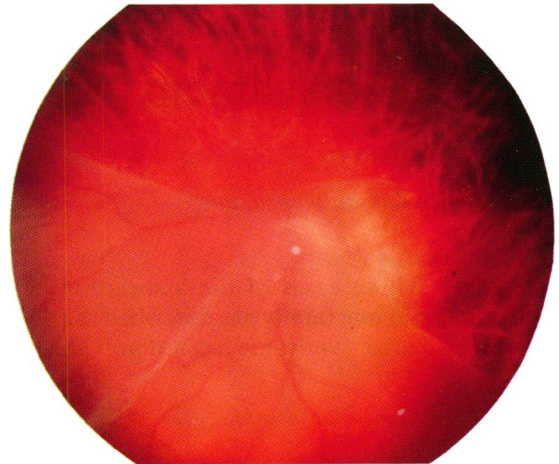


Fig. 3 Proband. Left eye: retinal detachment with giant tear.

lower lip. In addition microdontia, hypoplasia, and partial anodontia were present. The umbilicus was also very prominent. Since we considered this patient's ocular and non-ocular abnormalities to be typical of the Axenfeld-Rieger syndrome, we studied the family tree (Fig. 4).

CASE 2

A boy of 15, one of the brothers of the first patient, was also affected with the Axenfeld-Rieger syndrome. Six years earlier he had had a non-traumatic retinal detachment in his left eye. In the right eye visual acuity was 0.2 with -7 sph, and in the left eye was no perception light. External examination of the right

eye showed corectopia and iridic atrophy, with the formation of holes in the quadrant opposite the direction of the pupillary displacement. Gonioscopic examination showed a prominent Schwalbe's line over 360°, and iris processes were visible from 7 to 11 o'clock. The ocular pressure in this eye was 40 mmHg with topical therapy. The ocular fundus showed a small pale optic disc with a large staphyloma, lacquer cracks, and haemorrhagic dots in the posterior pole.

The left eye was microphthalmic, and external examination showed a marked band keratopathy and a complete cataract that prevented gonioscopic and ocular fundus examinations. Echography showed a complete retinal detachment with proliferative vitreoretinopathy.

Non-ocular abnormalities were characterised by a typical facial configuration with hypertelorism, flat-

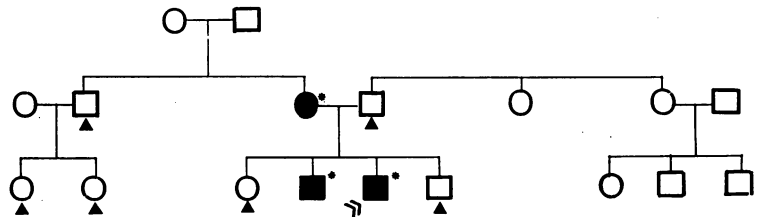


Fig. 4 Family tree of patients reported here.

- □ Patients examined and normal
- ■ Patients examined and affected
- Case reports
- » Proband

tening of the mid-face, a thin upper lip with a long philtrum, and a receding chin. In addition there were a submucose palate, microdontia, anodontia, and an abnormal configuration of the teeth, which had a conical aspect. In this patient too the umbilicus was very prominent.

#### CASE 3

A woman 37 years old, mother of cases 1 and 2, is now completely blind as a result of bilateral retinal detachment. External examination of both eyes showed a dense band keratopathy with a complete cataract. The characteristic changes of the cornea, angle chamber, and iris were not visible owing to the cataract and corneal opacity. The ocular pressure was 10 mmHg in the right eye and 6 mmHg in the left eye. Her visual acuity, before bilateral retinal detachment, had been very poor with -5 sph in both eyes. In addition from the age of 12 she had suffered from bilateral glaucoma. Fifteen years before being seen she had had her first retinal detachment in the right eye. The patient thought this had a traumatic origin. The detachment was considered inoperable. The retinal detachment in her left eye had occurred seven years earlier and was non-traumatic. After two operations, however, the retina was still unattached. This eye is now microphthalmic, with corneal leukoma and cataract. The ecographic examination confirmed retinal detachment in both eyes, with proliferative vitreoretinopathy.

Non-ocular lesions in this patient were cleft palate, typical facial configuration, anodontia, and complete absence of finger nails and toe nails from birth.

Her other son and the daughter had no ocular or non-ocular abnormalities, and all the other members of the family examined were completely normal (Fig. 4). No consanguinity was present in the family tree.

#### Discussion

The occurrence of iris strands in addition to a prominent Schwalbe's line has traditionally been called Axenfeld's anomaly. If glaucoma is also present, the condition is known as Axenfeld's syndrome. Rieger<sup>1-4</sup> reported some cases with similar anterior segment anomalies but with additional changes, such as microcornea, corectopia, and atrophy and hole formation in the iris, and also some non-ocular abnormalities, especially of the teeth and facial bones. Rieger recognised that this disorder probably had an autosomal mode of inheritance. Subsequently some authors<sup>5,6</sup> reported numerous patients with different combinations of the typical features of both the Axenfeld and the Rieger syndromes, even within the same family trees. The occurrence of the different lesions and also

the serious nature of the ocular and non-ocular anomalies varied considerably among members of the same pedigrees.<sup>7-11</sup> For this reason some authors now prefer to consider these two conditions within a single diagnostic category indicated by the general term Axenfeld-Rieger syndrome.<sup>12</sup>

This interesting defect is relatively rare. Many hypotheses<sup>3,12,13</sup> have been proposed for its pathogenesis on the assumption that the lesions have a common developmental origin during embryonic life. All the embryologic hypotheses are based on the observation that the syndrome has been reported as involving only the anterior segment of the eye. Now in contrast we report here three cases from one family that in addition to the characteristic ocular and non-ocular signs, including anomalies of the anterior segment of the eye, also show serious impairment in the posterior segment, with retinal detachment (in one case bilateral) and in one case a giant retinal tear. In our opinion the retinal detachment in our patients is not related only to the high myopia present. In fact the young age at which it occurred and the family history suggest a hereditary origin for the detachment.

Other authors<sup>14-18</sup> have described an association between the Rieger anomaly and certain developmental disorders. However, it is important to note that the developmental disorders were in non-ocular organs. The Axenfeld-Rieger syndrome comprises a range of ocular and non-ocular development disorders which may occur differently within the same family tree, and all the syndromes characterised by an association between ocular and non-ocular abnormalities caused by an arrest of development of some embryonic cells are not always so clear-cut as the traditional classifications would imply.<sup>19</sup> It is possible that failure in the development of embryonic cells and consequent alteration of their interactions with adjacent tissue may lead to the ocular and non-ocular anomalies of the Axenfeld-Rieger syndrome and may also generate posterior segment disorders, which perhaps are the cause of retinal detachment in our young patients.

#### References

- 1 Rieger H. Demonstration von zwei. Fallen von Verlagerung und Schlitzform der Pupille mit Hypoplasie des Irisvorderblattes an beiden Augen einer 10- und 25-jähriger Patientin. *Z Augenheilkd* 1934; **84**: 98-9.
- 2 Rieger H. Beiträge zur Kenntnis seltener Missbildungen der Iris. II. Über Hypoplasie des Iris vorderblattes mit Verlagerung und Entrundung der Pupille. *Graefes Arch Clin Exp Ophthalmol* 1935; **133**: 602-35.
- 3 Rieger H. Dysgenesis mesodermalis Corneae et Iridis. *Z Augenheilkd* 1935; **86**: 333.
- 4 Rieger H. Erbfragen in der Augenheilkunde. *Graefes Arch Clin Exp Ophthalmol* 1941; **143**: 277-99.

- 5 Cromble AL, Cullen JF. Hereditary glaucoma: occurrence in five generations of an Edinburgh family. *Br J Ophthalmol* 1964; **48**: 143–7.
- 6 Jerndal T. Goniodysgenesis and hereditary juvenile glaucoma. *Acta Ophthalmol (Kbh)* 1970; **107** (suppl).
- 7 Berg F. Erbliches jugendliches Glaukom. *Acta Ophthalmol (Kbh)* 1932; **10**: 568–87.
- 8 Hambresen L, Schepens C. Glaukome familiale. *Bull Soc Ophthalmol Fr* 1932; **59**: 219–23.
- 9 François J, Deweer JP, van den Berghe J. Chronic simple glaucoma with dominant heredity. *Bull Soc Belge Ophthalmol* 1950; **96**: 665–83.
- 10 Weatherill JR, Hart CT. Familial hypoplasia of the iris stroma associated with glaucoma. *Br J Ophthalmol* 1969; **53**: 433–8.
- 11 Chisholm IA, Chudley AE. Autosomal dominant iridogoniodysgenesis with associated somatic anomalies: four-generation family with Rieger's syndrome. *Br J Ophthalmol* 1983; **67**: 529–34.
- 12 Shields MB. Axenfeld-Rieger syndrome. A theory of mechanism and distinctions from the iridocorneal endothelial syndrome. *Trans Am Ophthalmol Soc* 1983; **81**: 736–84.
- 13 Reese AB, Ellsworth RM. The anterior chamber cleavage syndrome. *Arch Ophthalmol* 1966; **75**: 307–18.
- 14 Busch G, Weiskopf J, Bush K-T. Dysgenesis mesodermalis et ectodermalis Rieger oder Rieger'sche Krankheit. *Klin Monatsbl Augenheilkd* 1960; **36**: 512–23.
- 15 Crawford RA. Iris dysgenesis with other anomalies. *Br J Ophthalmol* 1967; **51**: 438–40.
- 16 Brailey WA. Double microphthalmos with defective development of iris, teeth and anus. Glaucoma at an early age. *Trans Ophthalmol Soc UK* 1890; **10**: 139.
- 17 Schachenmann G, Schmid W, Fraccaro M, et al. Chromosomes in coloboma and anal atresia. *Lancet* 1965; ii: 290.
- 18 De Hauwere RC, Leroy JG, Adriaenssens K, van Heule R. Iris dysplasia, orbital hypertelorism, and psychomotor retardation: a dominantly inherited developmental syndrome. *J Pediatr* 1973; **82**: 679–81.
- 19 Shields MB, Buckley E, Klintworth GK, Thresher R. Axenfeld-Rieger syndrome. A spectrum of developmental disorders. *Surv Ophthalmol* 1985; **29**: 387–409.

Accepted for publication 2 November 1988.