

Additional File 2

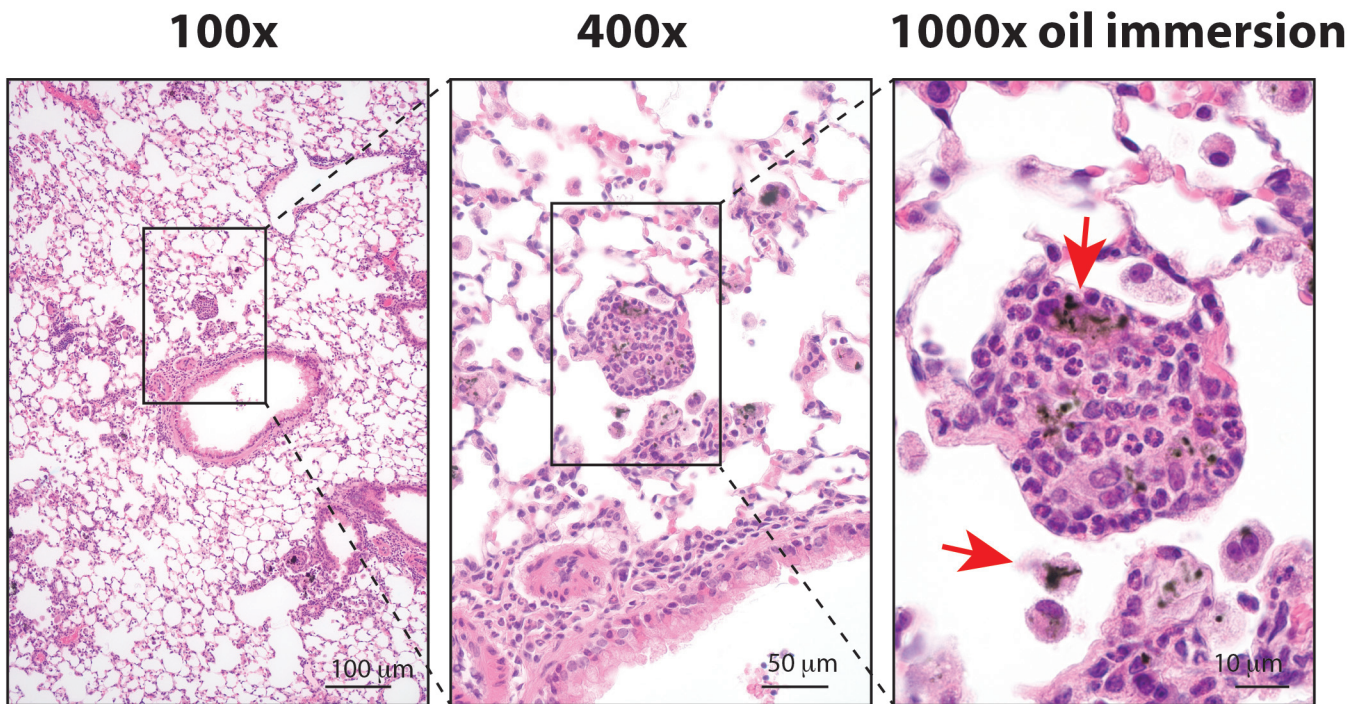


Fig. S1. Hematoxylin and eosin-stained lung tissue section showing eosinophilic granulomatous lesions containing MWCNTs in wild type mouse lung following exposure to HDM extract and MWCNTs by oropharyngeal aspiration. Red arrows indicate MWCNTs.