

LETTERS TO THE EDITOR

Seasonal variation in congenital toxoplasmosis

SIR,—Ocular toxoplasmosis is the most important cause of posterior uveitis and is considered to represent a late manifestation of congenital infection.^{1,2}

At present no definite cure exists for toxoplasmosis so prevention is of utmost importance. In 1984 the WHO urged the initiation of worldwide prevention projects to decrease the frequency of this congenital disease.

The moment of maternal infection during pregnancy was reported as an important factor in the severity and frequency of the fetal infection.³ Severe congenital toxoplasmosis with either neonatal death or neurologic manifestations and ocular involvement is only encountered if the maternal infection occurs during the first two trimesters of pregnancy. Later acquisition results mostly in subclinical fetal infections and accounts for about 65% of all maternal seroconversions. The cases of ocular toxoplasmosis manifested during adolescence and later are probably due to congenital infections associated with infection of the mother late in the pregnancy.

The aim of this study was to investigate whether the risk of maternal seroconversion depended on seasonal variation. We therefore analysed the birth dates of 532 patients with ocular toxoplasmosis, without evidence of any extraocular symptoms of toxoplasmosis and compared these data with the overall birth rate variation in the Netherlands over the same time period (Fig 1). The diagnosis of ocular toxoplasmosis was made on clinical grounds – in patients with unilateral focal necrotising retinitis sometimes associated with typical old pigmented scars. In doubtful cases an active formation of antitoxoplasmal antibodies in the eye was assessed by the Goldmann-Witmer coefficient.⁴ *Toxoplasma* serology was not routinely performed since *Toxoplasma* antibodies are present in the majority of the Dutch population and so positive titres in adults have no diagnostic value. The patients included were those who attended uveitis clinics with active ocular toxoplasmosis between 1987 and 1988. The birth dates of the patients and controls (population study of more than 20 000 persons per year) were between 1954 and 1969.

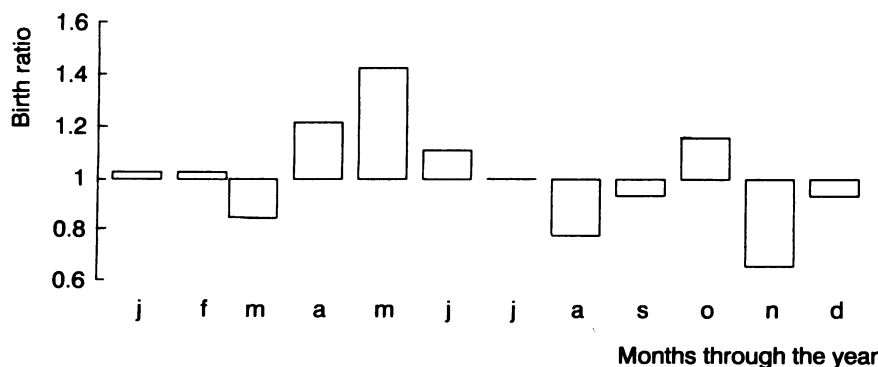


Figure 1 Seasonal variation in congenital toxoplasmosis.

$$\text{Birth ratio} = \frac{\text{number of children born with ocular toxoplasmosis}}{\text{expected number}}$$

Two significant differences between the overall birth rates and those of patients were observed: a higher birth rate of children with ocular toxoplasmosis in May and a lower birth rate in November compared with the expected number of births (Fig 1; χ^2 test, $p < 0.05$).

How are we to interpret these findings? All our patients had only ocular involvement of toxoplasmosis and so we can assume that the maternal infection probably took place during the third trimester of the pregnancy.³ A higher frequency of seroconversion in March, April, or May may thus be responsible for a peak of births observed in May.

These findings suggest that there may be a higher risk of contracting toxoplasmosis in the early spring and eventual preventive measures should take this phenomenon into account.

The authors thank the members of the Dutch Uveitis Group for their cooperation.

C MEENKEN
A ROTHOVA
A KIJLSTRA

Department of Ophthalmology-Immunology,
The Netherlands Ophthalmic Research Institute,
Amsterdam,

Department of Ophthalmology,
Academic Medical Centre,
Amsterdam, The Netherlands

J OOSTING
Department of Medical Physics,
University of Amsterdam,
Academic Medical Centre,
Amsterdam, The Netherlands

- Henderly DE, Genster AJ, Smith RE, Rao NA. Changing patterns of uveitis. *Am J Ophthalmol* 1987; **103**: 131–6.
- Perkins ES. Ocular toxoplasmosis. *Br J Ophthalmol* 1973; **57**: 1–17.
- Desmonts G, Couvreur A. Congenital toxoplasmosis, a prospective study of 378 pregnancies. *N Engl J Med* 1974; **290**: 1110–6.
- Kijlstra A, Breebaart AC, Baarsma GS, Bos PJM, Rothova A, Luyendijk L, et al. Aqueous chamber taps in toxoplasmic chorioretinitis. *Doc Ophthalmol* 1986; **64**: 53–8.

Angioid streaks in β thalassaemia minor

SIR,—A report by Kinsella and Mooney¹ described a 42-year-old woman of Italian origin with coexisting angioid streaks and β thalassaemia minor. Her general physical and cutaneous examination was normal, and a skin biopsy in 1986 showed no histological evidence of pseudoxanthoma elasticum (PXE). She was referred to the dermatology department in November 1989. She had no symptoms referable to her skin but on close questioning agreed that her axillary skin had changed.

On examination lax skin was noted involving the patient's anterior neck and axillae. She had the typical 'plucked chicken' or cobblestone

pattern of PXE of the axillae, with more subtle change of her posterolateral neck, accentuated by stretching the skin. A 4 mm punch biopsy obtained from clinically involved axillary skin and stained with haematoxylin and eosin and Miller's elastic stain and von Kossa reagent showed characteristic histological changes of PXE: clumping, disruption, and calcification of the elastic fibres within the dermis. Punch biopsy of the adjacent normal appearing skin showed no histological abnormality.

An association between angioid streaks and PXE has been noted in at least 62% of cases of angioid streaks.² The cutaneous lesions of PXE usually first appear before age 10, but may be delayed until the fourth³ or fifth decade.⁴ Early changes are frequently clinically subtle. On occasion a histological change consisting of tiny foci of abnormal elastic tissue may be detected in skin which is not clinically altered.⁵ Random biopsy of skin is unlikely to be helpful in establishing a diagnosis of PXE. The sites of predilection include the side of the neck, said to be the earliest, most frequent, and most heavily involved site in PXE, and next the axillary areas.³ Improved diagnostic yield may be attained by taking biopsy samples from scars.⁶

In addition to PXE, angioid streaks have been described in various haemoglobinopathies, and there are single case reports of their occurrence in some thalassaemias.¹ The prevalence of angioid streaks in Paget's disease has recently come under scrutiny. A surprisingly low prevalence of 1.4% was noted, leading to the conclusion that Paget's disease is only infrequently associated with angioid streaks.⁷

Patients with angioid streaks of undetermined aetiology warrant careful clinical cutaneous evaluation with selective histological sampling to detect subtle changes of possible aetiological significance. If clinical examination and skin histology prove normal, these patients should be followed up until the fourth or fifth decade for possible subsequent development of PXE.

BRIGID F O'DONNELL
FRANK C POWELL
SEAN O'LOUGHLIN

Regional Centre of Dermatology
ROBERT W ACHESON
Regional Centre of Ophthalmology,
Mater Misericordiae Hospital,
Eccles Street,
Dublin 7,
Ireland

- Kinsella FP, Mooney DJ. Angioid streaks in beta thalassaemia minor. *Br J Ophthalmol* 1988; **72**: 303–4.
- Percival SPB. Angioid streaks and elastorrhexis. *Br J Ophthalmol* 1968; **52**: 297–308.
- Reeve EB, Neldner KH, Subryan V, Gordon SG. Development and calcification of skin lesions in thirty-nine patients with pseudoxanthoma elasticum. *Clin Exp Dermatol* 1979; **4**: 291–301.
- Neldner KH. Pseudoxanthoma elasticum. *Clin Dermatol* 1988; **6**: 1–159.
- Goodman RM, Smith EW, Paton D, et al. Pseudoxanthoma elasticum: a clinical and histopathological study. *Medicine* 1963; **42**: 297–334.
- Lebwohl M, Phelps RG, Yannuzzi L, Chang S, Schwartz I, Fuchs W. Diagnosis of pseudoxanthoma elasticum by scar biopsy in patients without characteristic skin lesions. *N Engl J Med* 1987; **317**: 347–50.
- Dabbs TR, Skjold K. Prevalence of angioid streaks and other ocular complications of Paget's disease of bone. *Br J Ophthalmol* 1990; **74**: 579–82.

Pattern visual evoked potential in ocular hypertension

SIR,—Drs Bray, Mitchell, and Howe are to be congratulated on their article on the prognostic significance of the pattern visual evoked potential in ocular hypertension.¹ They say that they