

## Contractile protein antigens in the cells of malignant melanoma of the choroid and their diagnostic significance

A. H. S. RAHI, A. GARNER, AND A. H. A. MALATY

*From the Department of Pathology, Institute of Ophthalmology, London*

**SUMMARY** Sera from patients with proved and suspected melanoma of the uvea and from patients with innocuous uveal naevi were found by immunohistological techniques to have an affinity for the cytoplasm of malignant choroidal melanoma cells in an appreciable proportion of cases. The responsible antibodies were subsequently shown to react with smooth muscle protein in a variety of tissues and not to be melanoma-specific. It was also shown by electron microscopy that microfilaments consistent with contractile protein are a feature of the cytoplasm of malignant choroidal melanoma cells. The latter observations, which do not appear to have been reported previously, mean that false positives are to be expected if immunodiagnostic techniques are used for the recognition of malignant disease of the uvea, especially as smooth muscle antibodies can occur in non-neoplastic ocular diseases.

There is good evidence that the cells of malignant melanoma involving the choroid possess at least 2 special types of antigen, melanoma-specific cytoplasmic antigens (MSCA) and melanoma-specific transplantation antigens (MSTA), located on the surface membrane of the tumour cell. In an earlier study (Rahi, 1971, 1973) it was shown that the surface antigens are peculiar to each individual tumour, in contrast to a considerable degree of sharing of intracytoplasmic antigens between one malignant melanoma and another (Wong and Oskvig, 1974). Contrary to our experience, however, the latter workers also reported some sharing of surface antigens in a proportion of their cases. Such discrepancy may be due to an increase in non-specific uptake of antiserum when used undiluted as in the immunofluorescence studies of Wong and Oskvig. Alternatively, choroidal melanomas may resemble those of the skin in having either of 2 additional types of surface-associated antigen: one is specific to melanoma cells but common to a number of individual tumours, while the other is shared with non-neoplastic cells of other tissues in a variety of animal species (Oettgen, 1977).

In the present communication we present evidence of a hitherto unreported cytoplasmic antigen in choroidal melanoma cells which is also present in a

variety of other mammalian tissues. As a corollary we further describe the presence of autoantibodies, in the serum of patients with both benign and malignant pigmented intraocular tumours, which react not only with autologous and allogeneic melanoma cells but also with a variety of other mammalian cell types. Because the relevant cells are all rich in contractile protein these antibodies are presumed to be directed against the smooth muscle content.

### Materials and methods

Sections of snap frozen malignant choroidal melanoma, tumour imprints, and tumour cells maintained in tissue culture were used as substrates for antibody detection.

Serum from patients with chronic uveitis which was shown to have high titres of smooth muscle antibody (>1:160) in other studies (Rahi *et al.*, 1976), directed particularly against actin as judged by the conventional criteria (Trenchev and Holborow, 1976), was the principal source of antiserum for the localisation of contractile protein in the melanoma cells. Confirmatory studies were performed with antisera monospecific for actin, myosin, and light and heavy meromyosin (obtained by the courtesy of Dr Trenchev).

Frozen sections of a composite block containing liver, kidney, skeletal muscle, stomach, and salivary

Address for reprints: Dr A. H. S. Rahi, Department of Pathology, Institute of Ophthalmology, Judd Street, London WC1H 9QS

gland of rat origin were used to demonstrate the specificity of presumed smooth muscle antibodies in test sera. Frozen sections of rat eyes were also used for this purpose.

Sera from 100 healthy adults, 120 patients with histologically-confirmed malignant melanoma of the choroid, 63 with clinically suspected malignant melanoma, and 27 with uveal naevi were examined for the presence of smooth muscle antibodies and for the capacity of such antibodies to cross-react with the cytoplasm of malignant melanoma cells.

Examination for the presence of antibodies involved the use of immunofluorescence and immunoperoxidase techniques. Fluorescein-labelled mono- or poly-specific antihuman and antirabbit immunoglobulins were obtained from Wellcome Laboratories, and a Zeiss epifluorescence microscope equipped with a fluorescein isothiocyanate interference filter was used to examine the treated sections and tissue culture preparations. Sections and cell preparations for immunoperoxidase staining were initially treated with 1:20 normal pig serum to block non-specific reactivity and then successively with a 1:5 dilution of the test serum and rabbit serum containing antihuman immunoglobulin. After being washed, peroxidase-labelled antirabbit IgG raised in pigs (Dako, Denmark) and diluted 1:80 was placed on the sections and tumour imprints. Subsequently the slides were washed thoroughly and then incubated in a freshly prepared 0.06% solution of diaminobenzidine tetrahydrochloride in Tris-buffered saline with the addition of 2 drops of 10 volume hydrogen peroxide to each 10 ml. The reaction product was then examined by light microscopy. Appropriate controls to exclude non-specific and endogeneous peroxidase activity were also prepared.

In one instance osmium-fixed material from a malignant melanoma of the choroid was examined by electron microscopy of Araldite-embedded sections stained with uranyl acetate and lead citrate using a Jeol JEM-100C transmission electron microscope.

## Results

With the use of a 1:5 dilution of test sera antibodies with an affinity for sites in the cytoplasm of uveal malignant melanoma, cells were demonstrated in 42% of the patients with proved malignant melanoma, 52% of the patients suspected of having a malignant melanoma, and 29% of those with presumed uveal naevi (Table 1, Fig. 1).

Serum from patients with uveitis previously found to contain antibodies to contractile protein by virtue of its staining affinity for the cytoplasm of rat stomach, liver, kidney, salivary gland, and

skeletal muscle (Figs. 2-7) also reacted strongly with the cytoplasm of uveal malignant melanoma cells (Fig. 8). The implication of these findings that the tumour cells may also possess contractile proteins was supported by the electron microscopical demonstration of numerous fine filaments in the cytoplasm of 1 such tumour (Figs. 9-11). The filaments were usually grouped in loose bundles and showed some tendency to be aligned parallel to the long axis of the cell; they varied in diameter between 4 and 7 nm.

Confirmation of the presence of contractile protein in choroidal malignant melanoma cells was provided by the immunofluorescence shown by 5 tumour specimens treated with antiserum to purified actin.

Testing serum from patients with melanotic lesions of the uvea against the same rat tissues, as recommended by Whitehouse and Holborow (1971) for the demonstration of smooth muscle antibody in malignant states, showed that such antibody was present in 27% of patients with proved malignant melanoma, 38% of patients with suspected malignancy, and 48% of persons with naevi (Table 2).

A similar pattern was observed by means of the immunoperoxidase technique.

In addition to smooth muscle antibodies some of the test sera from patients with melanotic lesions were examined for the presence of other auto-antibodies. Some were found to contain antinuclear

Table 1 *Incidence of antibodies to tumour-associated cytoplasmic antigens in patients with melanotic lesions of the uvea (serum tested at 1:5 dilution)*

Diagnosis	No. of cases	No. of positives +	No. of positives ++	Percentage of positives
Malignant melanoma (histologically confirmed)	120	40	10	42
Malignant melanoma (clinically suspect)	63	31	2	52
Naevus (clinical diagnosis)	27	7	1	29

Table 2 *Incidence of smooth muscle antibodies in patients with melanotic lesions of the uvea and in normal individuals (serum initially tested at 1:10 dilution)*

Diagnosis	No. of cases	No. of positives 1:10	No. of positives $\geq$ 1:10	Percentage of positives
Malignant melanoma (histologically confirmed)	120	22	10	27
Malignant melanoma (clinically suspect)	63	16	8	38
Naevus (clinical diagnosis)	27	9	4	48
Healthy adults	100	12	2	15

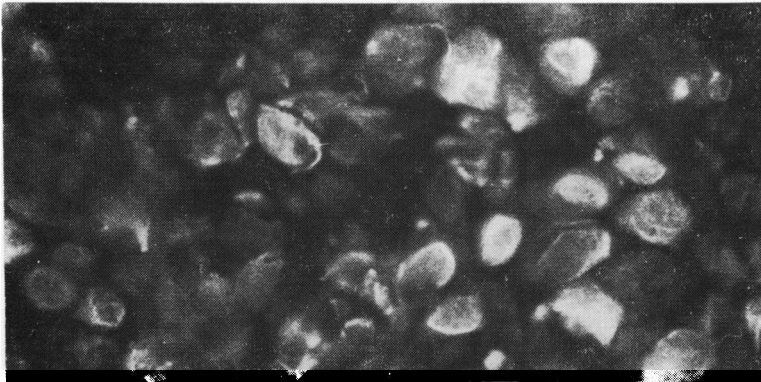


Fig. 1 Indirect immunofluorescence test with frozen section of a composite block of choroidal melanoma showing strong cytoplasmic fluorescence in the presence of tumour antibodies. The serum was from a histologically proved case  $\times 960$

Fig. 2 Positive indirect fluorescence test for smooth muscle antibodies. The muscularis mucosa, the vessel walls, and the muscle fibres between the glands in a rat stomach show bright fluorescence  $\times 320$

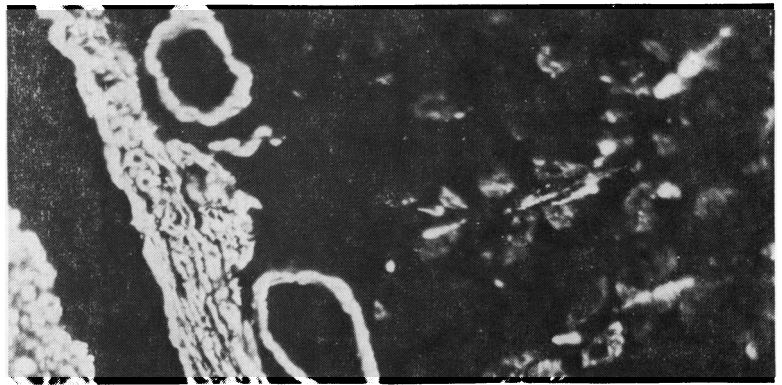


Fig. 3 Indirect immunoperoxidase test with section of rat liver showing polygonal staining of the hepatocytes due to affinity of smooth muscle antibodies for contractile proteins located beneath the surface membrane  $\times 455$

Fig. 4 Myoepithelial cells of a rat salivary gland showing bright fluorescence in the presence of smooth muscle antibodies in the serum of a patient with a malignant choroidal melanoma  $\times 960$

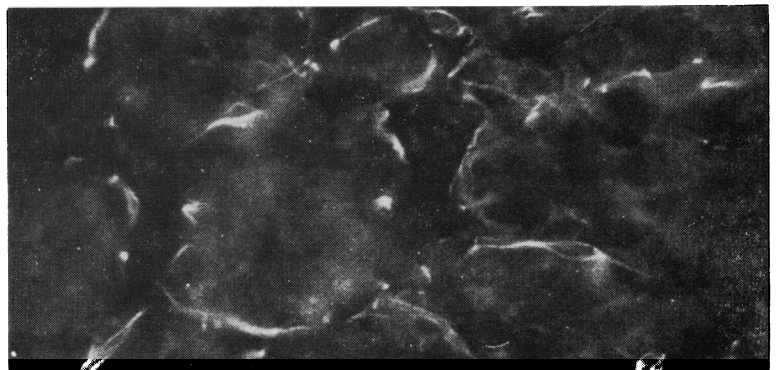

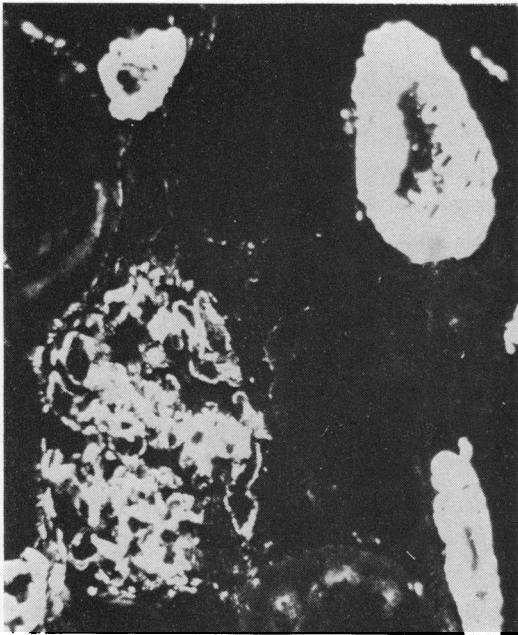


Fig. 5 Section of rat kidney treated with serum from a case of malignant melanoma showing smooth muscle antibodies. Note the bright fluorescence of a glomerulus and several blood vessels  $\times 960$

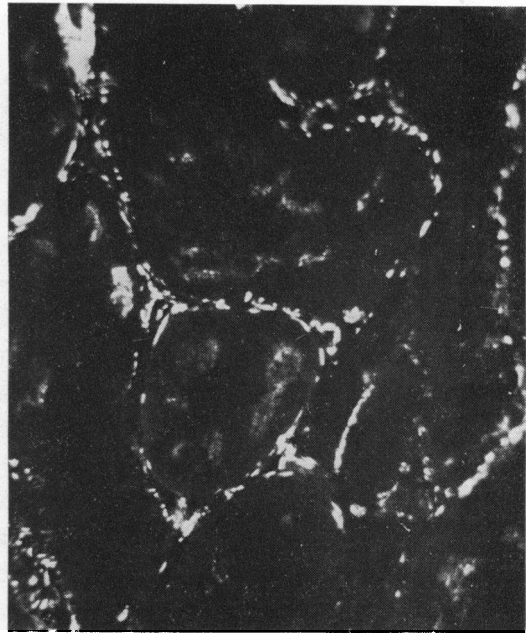

Fig. 6 Indirect immunofluorescence test with sections of rat kidney showing peritubular staining in the presence of antibodies to contractile protein antigens  $\times 960$

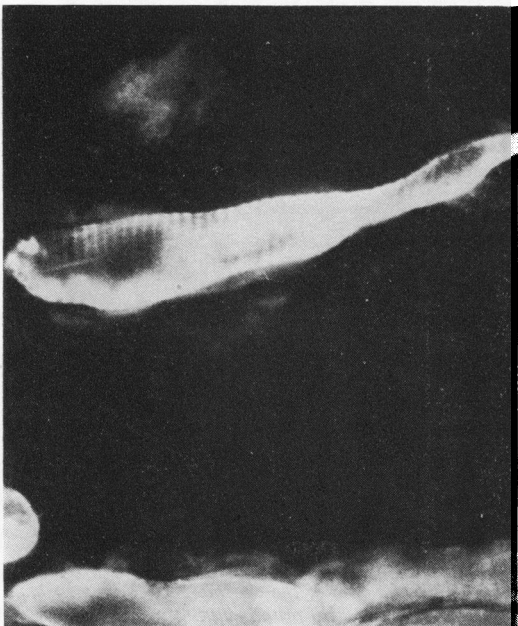


Fig. 7 Indirect immunofluorescent staining of skeletal muscle fibres. The bands of staining are single and probably represent antibodies directed against actin-rich 'I' bands  $\times 1200$

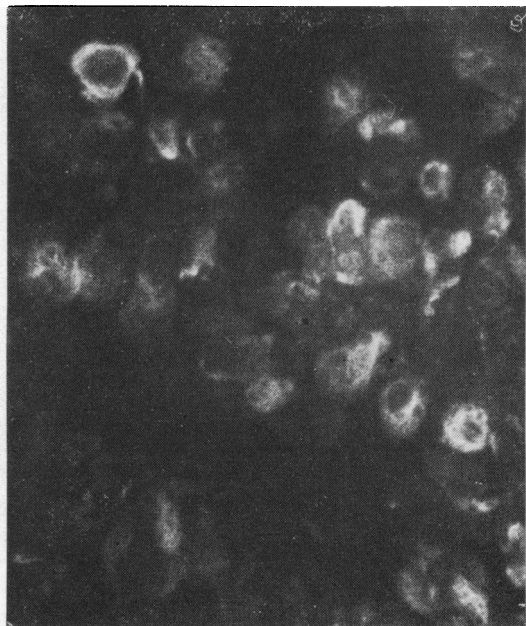
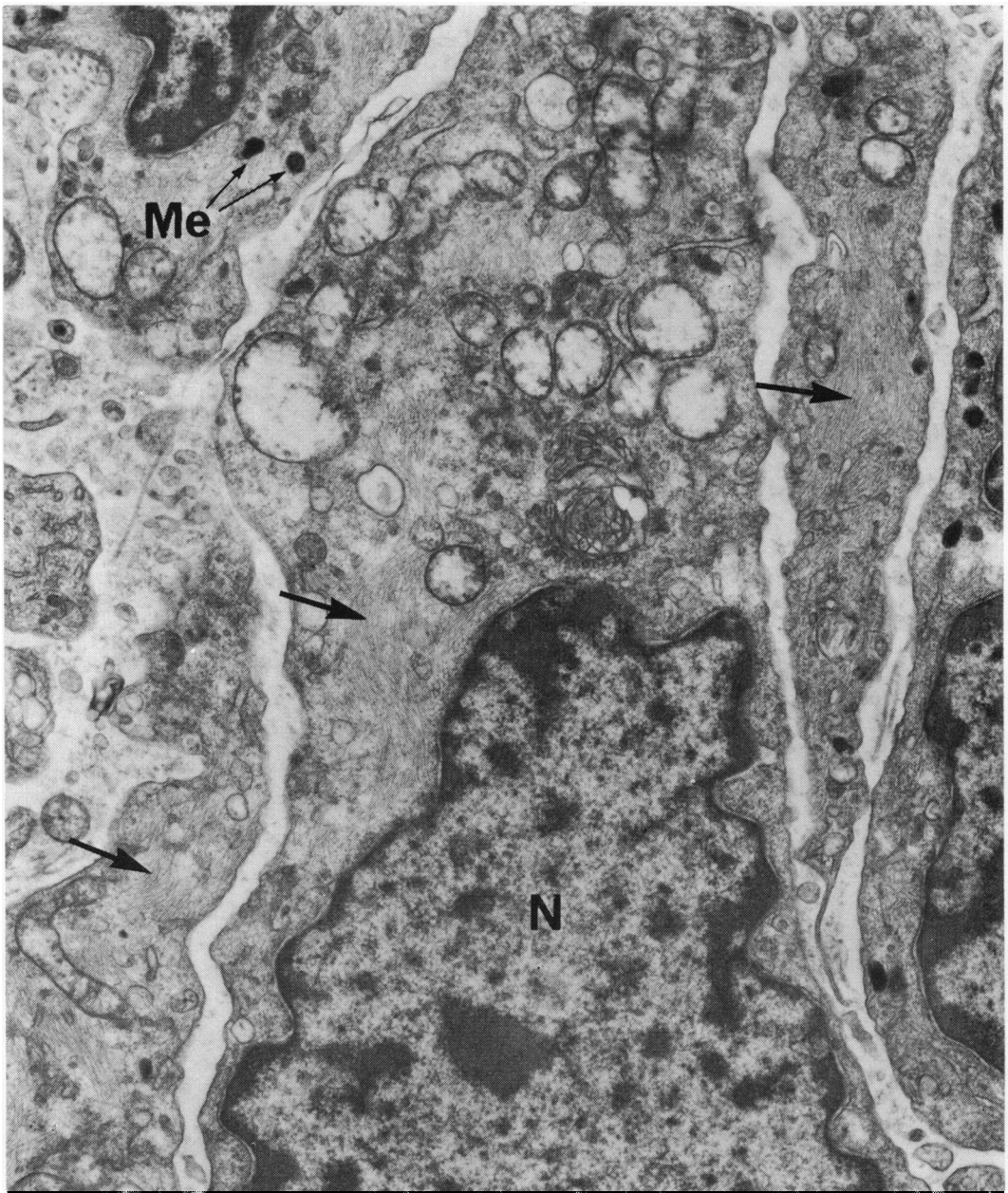


Fig. 8 Frozen section of a malignant melanoma treated with serum from a case of uveitis known to contain smooth muscle antibodies. Note the bright cytoplasmic fluorescence of several tumour cells suggesting presence of contractile elements  $\times 960$



**Fig. 9** *Electron micrograph of a lightly pigmented spindle-cell malignant melanoma of the choroid showing numerous intracytoplasmic fine filaments (arrows). Mitochondria, many of them swollen, are also prominent but melanosomes (Me) are sparse. N = nucleus × 17 800*

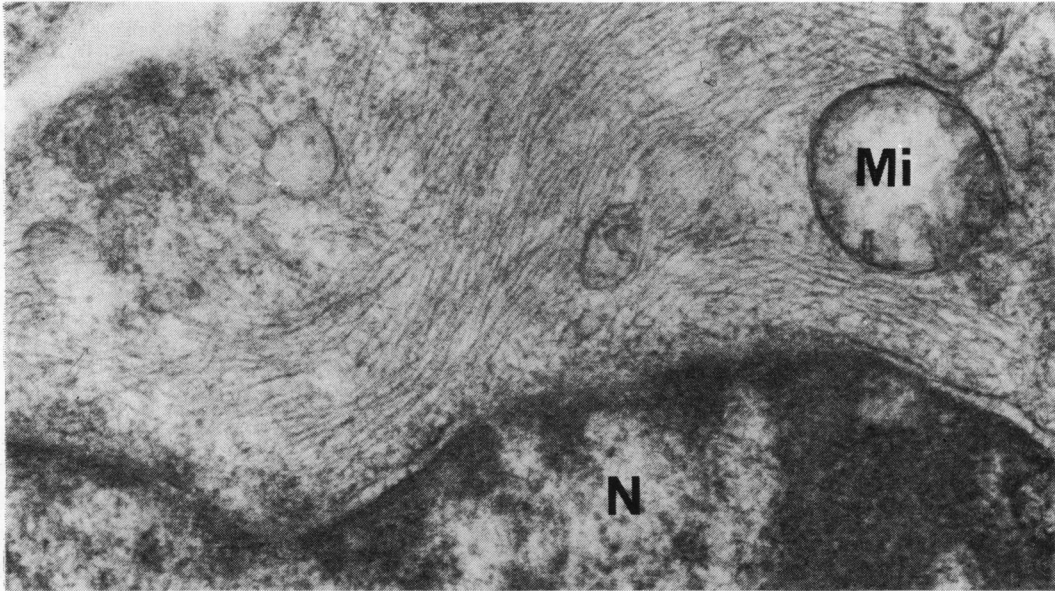


Fig. 10 Electron micrograph at higher magnification of part of a malignant melanoma cell shows intracytoplasmic filaments measuring 4 to 7 nm in diameter lying more or less parallel to the cell surface. N = nucleus. Mi = mitochondrion  $\times 54\ 000$

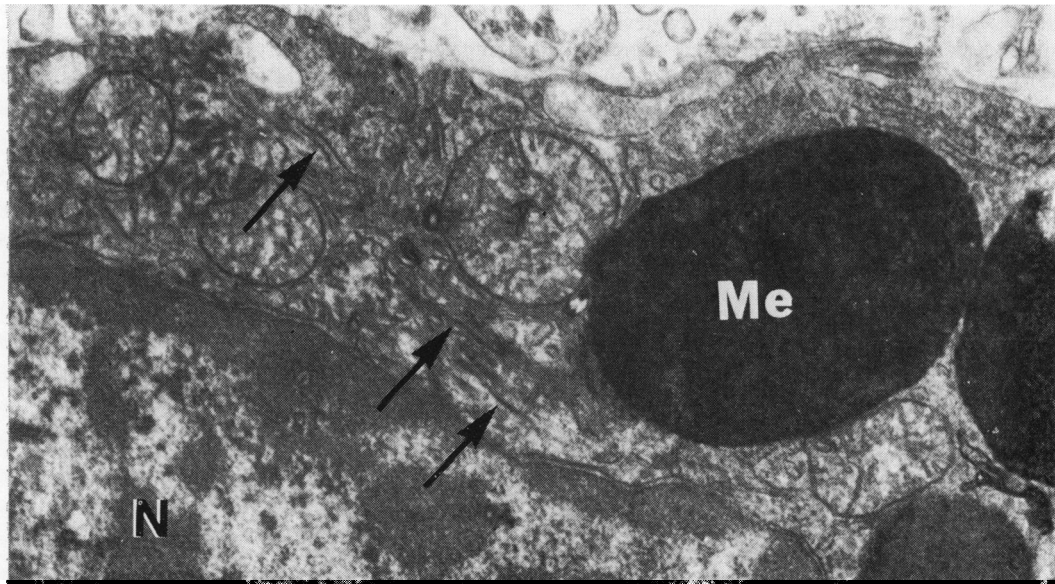


Fig. 11 Occasional cells include additional coarse filaments of 10 to 14 nm diameter (arrows). N = nucleus. Me = melanosome  $\times 27\ 000$

and melanoma-specific antinucleolar antibodies, the significance of which will form the substance of a further communication.

### Discussion

It is well recognised that the sera of patients with liver disease frequently contain a specific antibody which reacts with smooth muscle fibres in the stomach wall and blood vessels and the cytoplasm of hepatocytes and glomerular endothelium (Johnson *et al.*, 1965; Whittingham *et al.*, 1966). Autoantibodies of this type have also been detected in the serum of patients with a range of malignant tumours, including cutaneous melanoma (Whitehouse and Holborow, 1971). A subsequent report from the same laboratory further showed that the contractile proteins against which these 'smooth muscle' antibodies are directed are a feature of many cell types, in addition to those with a primary muscular function, and are generally organised as cytoplasmic filaments (Gabbiani *et al.*, 1975). These workers also described strong immunofluorescence by human cancer cells exposed to serum from rabbits containing antibodies raised against smooth muscle actin, myosin, and heavy and light meromyosin, while electron microscopy revealed the presence of numerous microfilaments presumed to be contractile in nature.

These studies are important because they show that patients with malignant tumours may develop antibodies to contractile protein, i.e., to antigens which are not tumour-specific, and that such antibodies are apt to develop in non-neoplastic disorders. Consequently, the mere demonstration that a patient has antibodies with an affinity for cancer cells does not necessarily constitute evidence of a malignant condition in that patient. In the context of ocular malignant melanomas this casts considerable doubt on claims that cytoplasmic fluorescence of allogeneic melanoma cells can be used as an index of malignancy (Federman *et al.*, 1974; Wong and Oskvig, 1974). Clearly, before such antibody can be accepted as being a response to tumour-specific cytoplasmic antigen it is necessary to exclude the presence of smooth muscle antibodies by testing the patient's serum against preparation of stomach wall, etc.

Whether patients with smooth muscle antibodies in the presence of uveal malignancy also develop melanoma-specific antibodies is not known. Only when it is technically practicable to remove antibody to muscle antigens by absorbing them on to purified preparations of the individual contractile proteins will it be possible to answer this question with any certainty. Even then the presence of heterophile

antibodies, normally demonstrable in about 6% of the population and able to combine with a variety of tissues from animals of differing species (Hawkins *et al.*, 1977), needs to be excluded before the antibody can reliably be regarded as tumour specific.

Recent interest in intracellular contractile proteins has been stimulated by the finding that many cells not primarily muscular in type contain this type of structure in a readily identifiable form. The major contractile element of skeletal muscle is a macromolecular complex of polymerised myosin and actin organised into interdigitating filaments able to slide over each other and presenting a characteristic banded pattern. Smooth muscle fibres similarly contain filaments of actin and myosin but do not have the same spatial alignment; rather they lie at angles to each other, though in a predominantly parallel direction. Actin filaments can be recognised in electron micrographs of smooth muscle cells, their ends appearing to be attached to the cell membrane so that contraction produces movement of the whole cell relative to its environment (Guyton, 1976). A similar arrangement in neoplastic cells might account for the capacity of malignant tumour cells to infiltrate neighbouring tissues.

Other contractile proteins are desmin and skeletin, found in relatively thick 10-nm filaments, tropomyosin, actinin, C-protein, J-protein, and tubulin, the latter being the essential component of microtubules seen predominantly in neural cells, platelets, mast cells, lens epithelium, and mitotic spindles of dividing cells.

There is widespread agreement that several functions of non-muscle cells depend on the presence of actin filaments (4 to 7 nm diameter), microtubules (20 to 27 nm diameter), tonofilaments, and other large filamentous structures (10 to 12 nm diameter). These structures are considered to control cell shape, tight intercellular junctions, endocytosis, exocytosis, and cell motility (Lazarides, 1975; Feeney and Mixon, 1976; Becker, 1977).

As with so many other autoantibodies, the stimulus to anticontractile protein antibody ('anti-smooth muscle antibody') is unknown but may be related in part to focal tumour necrosis, since the necrosis produced by the application of a cryoprobe to the liver of laboratory animals has been shown to provoke the formation of this type of antibody (Li *et al.*, 1977). Demonstrably they are not a function of the neoplastic state as such, being a feature of several quite different forms of ocular disease including retinal vasculitis (Chilman, 1973), chronic uveitis, and Behçet's disease (Rahi *et al.*, 1976).

The role of smooth muscle antibodies in the pathobiology of uveal malignant melanoma is unknown. If they are to have any function it might

be speculated that complexes of antibody with contractile elements released from degenerating tumour cells (as part of the normal turnover of rapidly growing neoplasms) may be deposited within the tumour blood vessels to activate the complement sequence and initiate focal necrosis. In this case activation of complement would need to be through the alternative pathway, since the antibodies themselves do not fix complement. Prospective studies are in hand to see whether there is any correlation between smooth muscle antibody titre, melanoma cell type, and the presence of necrosis. It is, however, more likely that the antibody to contractile protein is an epiphenomenon with no significant biological effect, because if the antibodies, whether complexed with antigen or not, had a damaging effect they might be expected to harm many more tissues harbouring contractile proteins. Apparently they do not.

This study of melanoma antibodies is manifestly incomplete but it does go some way towards explaining the frustration beginning to be experienced by those wanting to use immunological methods for the diagnosis of cancer. Our finding that the antibodies responsible for the cytoplasmic fluorescence shown by melanoma cells in the presence of the serum of patients with suspected uveal malignancy are in large part directed against contractile protein components indicates that immunofluorescent staining of this kind cannot be taken as adequate evidence of malignant melanoma. Furthermore, the diverse conditions in which smooth muscle antibodies arise, including many which are not neoplastic, and the numerous categories of cell in which contractile filaments occur, may account for the positive immunofluorescence given by the sera of patients with non-malignant naevi and even non-neoplastic conditions.

#### References

- Becker, E. L. (1977). Stimulated neutrophil locomotion. *Archives of Pathology and Laboratory Medicine*, **101**, 509-513.
- Chilman, T. (1973). Specific and non-specific antibody activity in retinal vasculitis. *Transactions of the Ophthalmological Societies of the United Kingdom*, **93**, 193-198.
- Federman, J. L., Lewis, M. G., Clark, W. H., Jr., Egerer, I., and Sarin, L. K. (1974). Tumour-associated antibodies in the serum of ocular melanoma patients. *Transactions of the American Academy of Ophthalmology and Otolaryngology*, **78**, 784-794.
- Feeney, A., and Mixon, R. N. (1976). An *in vitro* model of phagocytosis in bovine and human retinal pigment epithelium. *Experimental Eye Research*, **22**, 533-548.
- Gabbiani, G., Trenchev, P., and Holborow, E. J. (1975). Increase of contractile proteins in human cancer cells. *Lancet*, **2**, 796-797.
- Guyton, A. C. (1976). *Textbook of Medical Physiology*. 5th edn. pp. 130-152. Saunders: Philadelphia.
- Hawkins, B. R., McDonald, B. L., and Dawkins, R. L. (1977). Characterisation of immunofluorescent heterophile antibodies which may be confused with autoantibodies. *Journal of Clinical Pathology*, **30**, 299-307.
- Johnson, G. D., Holborow, E. J., and Glynn, L. E. (1965). Antibody to smooth muscle in patients with liver diseases. *Lancet*, **2**, 878-879.
- Lazarides, E. (1975). Immunofluorescence studies on the structure of actin filaments in tissue culture. *Journal of Histochemistry and Cytochemistry*, **23**, 507-528.
- Li, A. K. C., Trenchev, P. S., Holborow, E. J., Newsome, C., and Wynne, A. T. (1977). Experimental smooth muscle antibodies. *Clinical and Experimental Immunology*, **27**, 273-277.
- Oettgen, H. F. (1977). Immunotherapy of cancer. *New England Journal of Medicine*, **297**, 481-491.
- Rahi, A. H. S. (1971). Autoimmune reactions in uveal melanoma. *British Journal of Ophthalmology*, **55**, 793-807.
- Rahi, A. H. S. (1973). Immunological aspects of malignant melanoma of the choroid. *Transactions of the Ophthalmological Societies of the United Kingdom*, **93**, 79-91.
- Rahi, A. H. S., Holborow, E. J., Perkins, E. S., Gungen, Y. Y., and Dinning, W. (1976). Immunological investigations in uveitis. *Transactions of the Ophthalmological Societies of the United Kingdom*, **96**, 113-122.
- Trenchev, P., and Holborow, E. J. (1976). The specificity of antiactin serum. *Immunology*, **31**, 509-517.
- Whitehouse, J. N. A., and Holborow, E. J. (1971). Smooth muscle antibodies in malignant diseases. *British Medical Journal*, **4**, 511-513.
- Whittingham, S., Mackay, I. R., and Iwin, J. (1966). Autoimmune hepatitis immunofluorescence reactions with cytoplasm of smooth muscle and renal glomerular cells. *Lancet*, **1**, 1333.
- Wong, I. G., and Oskvig, R. M. (1974). Immunofluorescent detection of antibodies to ocular melanomas. *Archives of Ophthalmology*, **92**, 98-102.