

Blepharochalasis

J. R. O. COLLIN, C. BEARD, W. H. STERN, AND D. SCHOENGARTH

From the Department of Ophthalmology, University of California Medical Center, San Francisco, USA

SUMMARY The condition of blepharochalasis and its treatment are discussed. Four cases are presented which show a physical sign that may help in its diagnosis.

Blepharochalasis is a relatively rare but distinctive condition characterised by recurrent attacks of eyelid oedema which often result in an acquired ptosis. It was first described by Beer (1817) and later given its name by Fuchs (1896). Since that time there have been many reports of the clinical and pathological findings. After recurrent and unpredictable attacks of oedema the eyelid skin becomes wrinkled, redundant, discoloured, thinned, and laced by tortuous vessels. Fuchs (1896) described the skin as having a cigarette-paper appearance.

Blepharochalasis is usually bilateral but may be unilateral. Two stages of the condition have been described. In the early stage the skin and eyelid tissues may become hypertrophied with oedema which does not pit on pressure (Benedict, 1926). This is followed by a thinning and atrophy of the skin and all the eyelid tissues, giving the characteristic skin appearance and ptosis. Most cases present in the atrophic state, and it is not certain whether they have ever passed through a so-called hypertrophic stage. Fine skin nodules have been described (Verhoeff and Friedenwald, 1922), but may be only a secondary association with previous surgery. Herniation of fat through a weakened orbital septum occurs (Schmidt-Rimpler, 1899). The lower lids may also be affected (Stein, 1930), and the generalised laxity of the tissues may lead to blepharophimosis (Friedenwald, 1923).

The various pathological findings have been summarised by Alvis (1935). The main changes are in the blood vessels, which are dilated and increased in number. These are associated with a proliferation of the endothelium of the capillaries and venules. There is a loss of elastic tissue and a generalised infiltration of the tissues with round cells. The epithelium is thinned and atrophic, with vacuolation of the basal cells. The aetiology of these changes remains unknown.

Address for reprints: Mr J. R. O. Collin, FRCS, Moorfields Eye Hospital, City Road, London EC1V 2PD

The attacks of oedema usually begin around puberty, which might suggest an endocrine imbalance. They resemble attacks of angioneurotic oedema of the eyelids (Fuchs, 1896), which might be due to an allergic diathesis. Patients with angioneurotic oedema may subsequently develop the characteristic skin changes of blepharochalasis (Verhoeff and Friedenwald, 1922), but no deficiency of C1-esterase inhibitor was found in a patient with blepharochalasis (Beard, 1976). Ascher (1922) described the triad of blepharochalasis, swelling of the mucous membrane of the lips, and nontoxic thyroid enlargement, suggesting that it could be part of a more generalised disorder. Most cases of blepharochalasis, however, are limited to the eyelids, and no generalised abnormality has been described.

Treatment is surgical. Redundant skin should be excised. A prolapsed lacrimal gland can be sutured back into position. A minimal ptosis may be successfully treated with a Fasanella-Servat (1961) procedure. Greater degrees of ptosis require more major surgery, but this may easily result in an over-correction if the condition is not properly diagnosed. Recurrent attacks of eyelid oedema can ruin a previously good postoperative result. The timing of surgery is therefore difficult. Since the frequency of attacks decreases with age, it would seem reasonable to wait until the disease is quiescent before attempting surgery (Stieglitz and Crawford, 1974).

This is a report of 4 cases of blepharochalasis which show a previously poorly described feature of the condition. The results of surgical correction are presented and the cause of the ptosis is discussed.

Patients

CASE 1

A man aged 31 presented with a bilateral acquired ptosis following recurrent attacks of eyelid oedema. The attacks had started about 13 years previously and there had been about 15 attacks in all lasting between 24 hours and 3 days. He had a history of

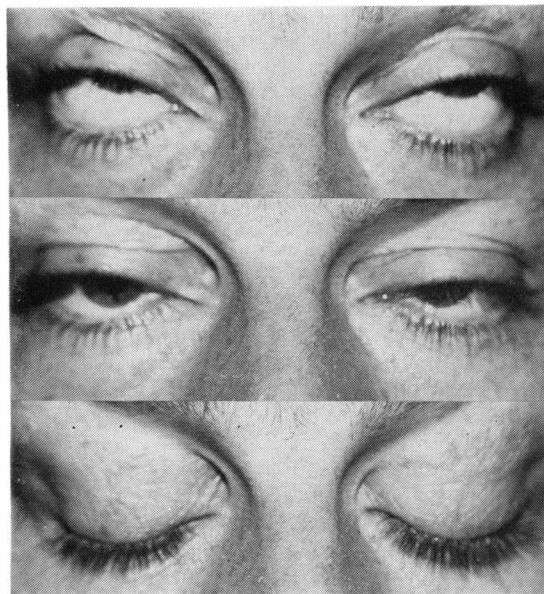


Fig. 1 Case 1: preoperatively showing bilateral ptosis with good levator function and atrophy of the nasal fat pads, more marked on the right, producing pseudo-epicanthic folds

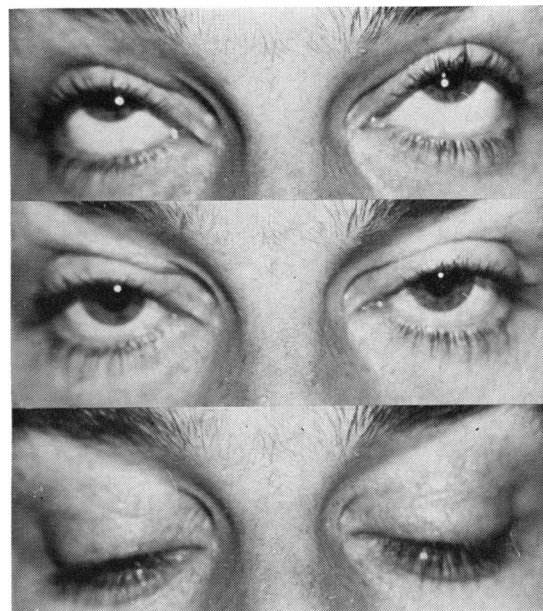


Fig. 2 Case 1: Postoperatively

possible allergy to aspirin but did not suffer from asthma, eczema, or hay fever. There was no family history of any similar condition or of other allergies.

On examination he had a marked bilateral ptosis with the typical thin wrinkled skin and considerable atrophy of the nasal fat pad, giving the appearance of a pseudoepicanthic fold on both sides. The vertical palpebral apertures were 7 mm on the right and 6 mm on the left, and the levator function was good, being 10 mm on the right and 11 mm on the left (Fig. 1). The unaided visual acuity was 6/6 on the right and 6/60 on the left. This left amblyopia was associated with a left convergent squint. No other ocular abnormality was detected. A Tensilon test was negative.

Bilateral upper lid surgery was performed by an anterior approach. The aponeurosis was not disinserted but was thinned. It was tucked and excess skin was excised. Postoperatively he was much improved. The palpebral apertures were 8.5 mm on both sides and the levator function was 15 mm (Fig. 2). He continued to have intermittent attacks of eyelid oedema (Fig. 3), which accentuated the atrophy of the nasal fat pads. The duration of these attacks was not influenced by systemic prednisolone 5 mg 4 times a day and cold compresses. Five years later the ptosis is recurring, and further surgery is being considered.

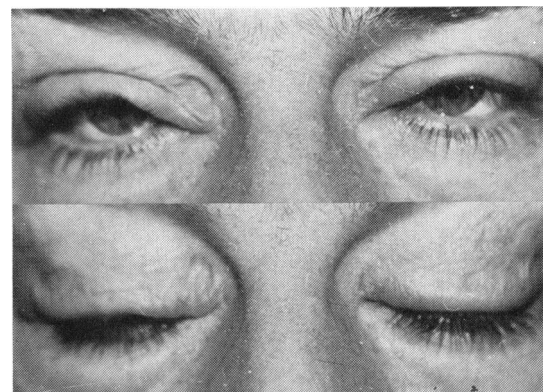

Fig. 3 Case 1: Postoperative attack of eyelid oedema in primary position and on down-gaze

CASE 2

A boy aged 15 presented with a right ptosis which had progressed over the previous 3 years. It was now stable although appeared worse when he was tired. He got recurrent attacks of swelling of the right eyelid, especially when he had a cold, but there was no history of any allergies and no significant family history.

On examination he had 2 mm of right ptosis with good levator function (Fig. 4). The palpebral apertures were 7 mm on the right and 9 mm on the left, and the levator function was right 13 mm and

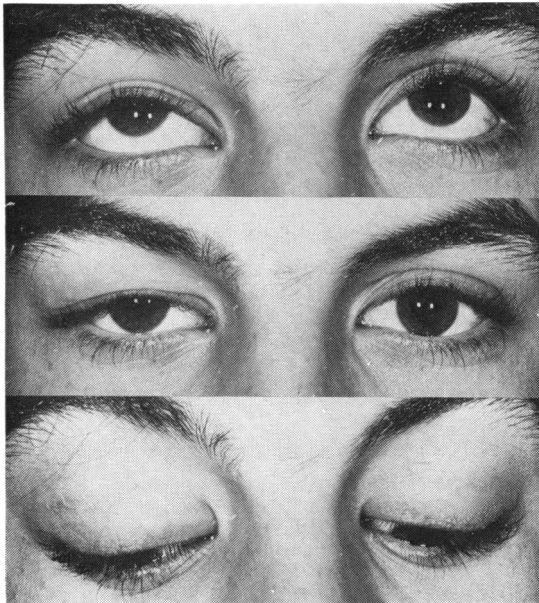


Fig. 4 Case 2: Preoperatively showing 2 mm of right ptosis with good levator function

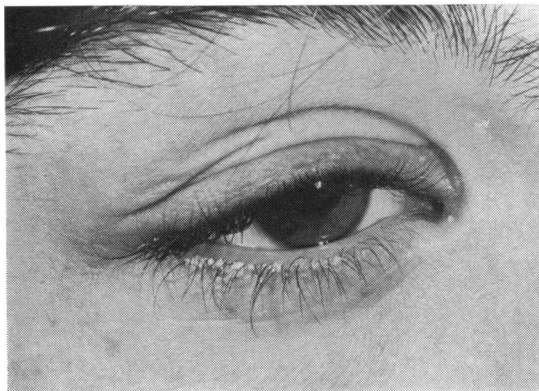


Fig. 5 Case 2: Right eye showing redundant skin and atrophy of the nasal fat pad producing a pseudoepicanthic fold

left 15 mm. The right eyelid remained lower than the left in all positions of gaze, suggesting an acquired type of ptosis. The skin of the upper lid was redundant and thinner than on the left, with visible blood vessels, and he had a marked atrophy of the nasal fat pad, producing a pseudoepicanthic fold on that side (Fig. 5). The unaided visual acuity was 6/9 in the right eye and 6/6 in the left eye. There were no other ocular or general physical abnormalities.

Ptosis surgery was performed via an anterior skin

approach. The aponeurosis was found to be extremely thin and stretched; 6 mm of this tissue were resected and healthy looking aponeurosis was sutured to the anterior tarsal surface 3 mm from the upper tarsal border (Fig. 6). Excess skin was excised and the skin crease reformed with interrupted sutures which picked up the underlying aponeurosis. Postoperatively the result was satisfactory (Fig. 7).

CASE 3

A girl aged 13 presented with a bilateral ptosis and a history of recurrent attacks of eyelid oedema since the age of 7. She had undergone a left ptosis correction 1 year previously, but the ptosis had recurred. There was no history of any allergy and no significant family history.

On examination she had a bilateral acquired ptosis worse on the left. The left palpebral aperture was 4 mm and the right 5 mm. The levator function was good, being 12 mm on the right and 10 mm on the left. The eyelid skin was markedly thin and atrophic. There was a marked atrophy of the nasal fat pad on both sides, giving her pseudoepicanthic

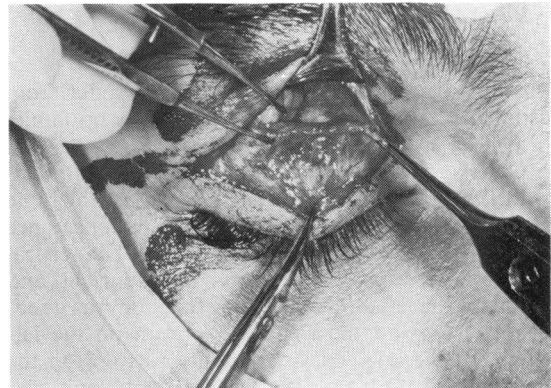


Fig. 6 Case 2: Operative picture showing aponeurosis held in forceps. This was sutured to the anterior tarsus just above the point of the scissors

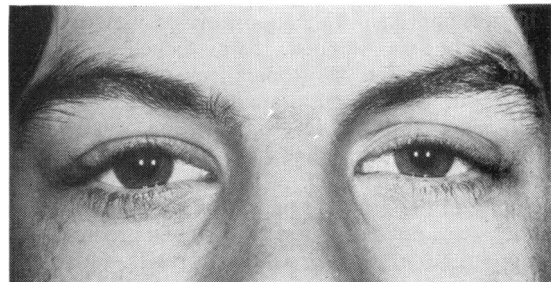

Fig. 7 Case 2: In primary position postoperatively

folds, and she had multiple small nodules in the skin of the left upper eyelid (Fig. 8). The unaided visual acuity in the right eye was 6/6 and in the left 6/9. There were no other ocular or physical abnormalities.

Bilateral ptosis surgery via an anterior approach was performed. Excess skin and the thinned aponeurosis were excised and healthy aponeurosis sutured to the tarsal plate. The postoperative appearance was much improved, but a subsequent attack of oedema led to a recurrence of the left ptosis, especially nasally (Fig. 9).

CASE 4

A man aged 25 presented with a left acquired ptosis following recurrent attacks of left upper eyelid oedema.

On examination he had about 3 mm of left ptosis

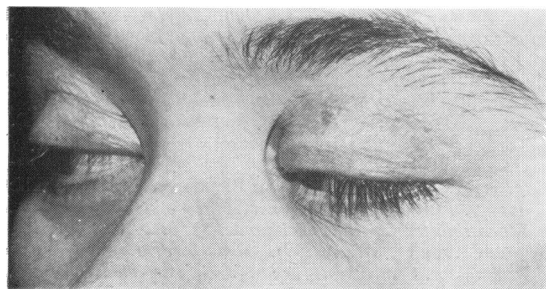

Fig. 8 Case 3: Showing atrophy of nasal fat pad producing a pseudoepicanthic fold. The left eyelid skin has multiple small skin nodules

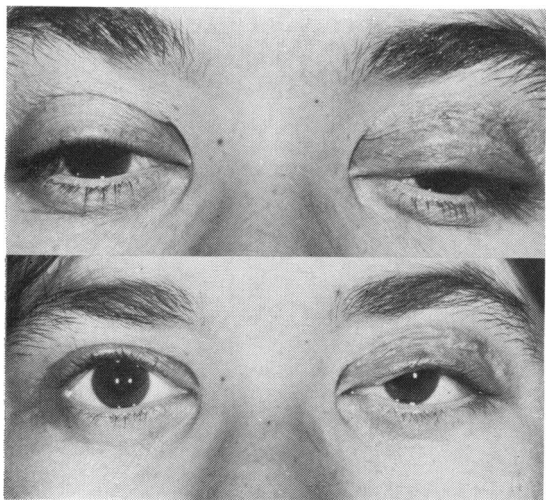

Fig. 9 Case 3: Pre- and postoperative appearance. A postoperative attack of oedema led to a recurrence of the ptosis nasally in the left eye

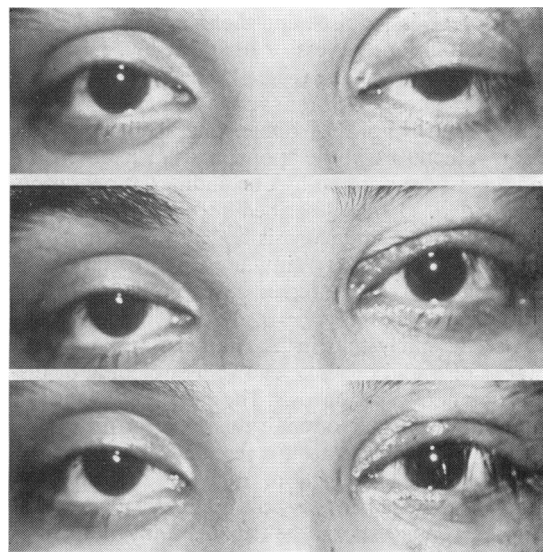


Fig. 10 Case 4: Upper: Preoperative appearance showing left ptosis. Middle: Immediate postoperative appearance showing overcorrection. Lower: Late postoperative appearance after suture removal and massage

with good levator function. The lid skin showed the typical thin, wrinkled appearance with the characteristic fat atrophy and pseudoepicanthic fold (Fig. 10, upper). At ptosis surgery by the conjunctival approach the thinned aponeurosis and a small amount of the levator muscle itself were resected. This led to an initial overcorrection (Fig. 10, middle) which was satisfactorily corrected by the early removal of sutures and massage (Fig. 10, lower).

Discussion

These 4 cases illustrate many of the accepted features of the condition. There is always a history of recurrent attacks of eyelid oedema leading to the characteristic skin appearance. In addition fine skin nodules may be present if the patient has undergone previous surgery (Case 3). The attacks usually start around puberty. In our youngest patient they began at the age of 7 (Case 3) and were still continuing in our oldest at the age of 35 (Case 1). The condition may be unilateral (Cases 2 and 4) or bilateral (Cases 1 and 3), and affects both sexes. Only 1 previous report (Alvis, 1935) has described the very distinctive atrophy of the nasal fat pad and the pseudoepicanthic fold which all our cases show. Why the medial fat pad should atrophy so markedly is not clear, but a review of published photographs of previously described cases shows that this is a very common feature of the condition.

The ptosis is acquired and the more affected eyelid is lower than on the less or unaffected side on both up-gaze and down-gaze (Fig. 4). The levator function is good. These factors suggest that the levator muscle itself is not dystrophic. The likely site of the lesion is therefore in the aponeurosis or its insertion, and this was supported by our findings at operation. Jones *et al.* (1975) described ptosis due to a disinsertion of the aponeurosis and its surgical repair. Their operation is very similar to that described by Kreiker (1929) for the repair of the ptosis associated with blepharochalasis.

It seems likely that in blapharochalasis recurrent attacks of eyelid oedema lead to a stretching or disinsertion of the aponeurosis. The aim of ptosis surgery should therefore be to repair this aponeurotic defect. If the levator muscle itself is resected, this will easily result in an overcorrection, as in Case 4. Since the attacks of oedema may continue postoperatively (Fig. 3), surgery should be delayed until they are as infrequent as possible. If recurrent attacks of oedema cause a recurrence of the ptosis, the aponeurotic defect can be repaired again.

Conclusion

Four cases of blepharochalasis are presented. These all show a marked atrophy of the nasal fat pad of the upper eyelid, which gives rise to a deep hollow nasally and a pseudoepicanthic fold. This characteristic is important, since the diagnosis of blepharochalasis must be made on the history and examination. Recognition of this sign may alert the surgeon to make the proper diagnosis and so avoid unnecessary investigations and inappropriate surgery.

Although the aetiology of the condition is unknown, the cause of the ptosis is probably a stretching or disinsertion of the aponeurosis of the levator palpebrae superioris muscle. If this defect is repaired, there is little risk of an overcorrection, and the repair can be repeated if recurrent attacks of oedema lead to a recurrence of the ptosis.

References

- Alvis, B. Y. (1935). Blepharochalasis. *American Journal of Ophthalmology*, **18**, 238–245.
- Ascher, K. W. (1922). Das Syndrom Blepharochalasis, Struma und Doppellid. *Klinische Wochenschrift*, **1**, 2287–2288.
- Beard, C. (1976). *Ptosis*, 2nd edition, p. 72. Mosby: St. Louis.
- Beer, G. J. (1817). *Lehre von den Augenkrankheiten, als Leitfaden zu Seinen öffentlichen Vorlesungen Entworfen*, vol. 2, p. 109. Heubner und Wolke: Vienna.
- Benedict, W. L. (1926). Blepharochalasis. *Journal of the American Medical Association*, **87**, 1735–1739.
- Fasanella, R. M., and Servat, J. (1961). Levator resection for minimal ptosis. *Archives of Ophthalmology*, **65**, 493–496.
- Friedenwald, J. S. (1923). Further note on blepharochalasis. *Archives of Ophthalmology*, **52**, 367–368.
- Fuchs, E. (1896). Ueber Blepharochalasis (Erschlaffung der Lidhaut). *Wiener klinische Wochenschrift*, **9**, 109–110.
- Jones, L. T., Quickert, M. H., and Wobig, J. L. (1975). The cure of ptosis by aponeurotic repair. *Archives of Ophthalmology*, **93**, 629–634.
- Kreiker, A. (1929). Operation der Blepharochalasis mit Hilfe der v. Blaskovicsschen Lidfalten bildenden Nähte. *Monatsblätter für Augenheilkunde*, **83**, 302–305.
- Schmidt-Rimpler, H. (1899). Fett-Hernien der oberen Augenlider. *Centralblatt für praktische Augenheilkunde*, **23**, 297–298.
- Stein, R. (1930). Blepharochalasis des Unterlides. *Monatsblätter für Augenheilkunde*, **84**, 846–851.
- Stieglitz, L. N., and Crawford, J. S. (1974). Blepharochalasis. *American Journal of Ophthalmology*, **77**, 100–102.
- Verhoeff, F. H., and Friedenwald, J. S. (1922). Blepharochalasis. *Archives of Ophthalmology*, **51**, 554–559.