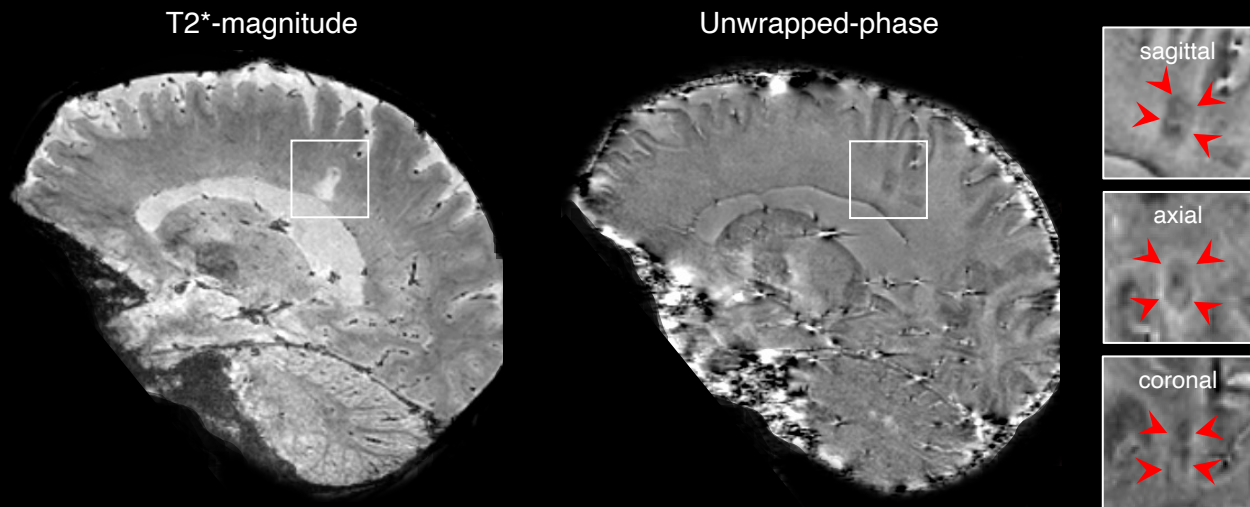


a. Baseline sagittal susceptibility MRI showing a Paramagnetic rim lesion (PRL)



b. The paramagnetic rim disappeared over the 63 months MRI follow-up

