

Ultrastructure of gonococci in acute, chronic, and asymptomatic gonorrhoea

N. M. OVČINNIKOV, V. V. DELEKTORSKIJ, AND G. A. DMITRIEV

From the Department of Microbiology and the Gonorrhoea Section of the Central Institute for Research on Skin and Venereal Diseases of the Ministry of Health, Moscow, USSR

Summary

The authors have made an electron microscope study of material from patients with acute, chronic, and asymptomatic gonorrhoea both before and during treatment with penicillin and kanamycin. Some features of the structure of the gonococcus, *e.g.* the six-layered cell wall, and of the reactions of the organism in different forms of gonorrhoea before and during treatment with antibiotics were demonstrated using Ruthenium red staining. Thus, in chronic gonorrhoea, the presence of structures similar to gonococcal L-forms was found to be characteristic, while in asymptomatic gonorrhoea the formation was observed of multimembrane phagosomes hampering the penetration of drugs and antibodies. The positioning of gonococci round epithelial cells was noted (cellular energy). The possibility of changing treatment procedures is examined in the light of these observations.

Introduction

The ultrastructure of *N. gonorrhoeae* has already been studied (Ovčinnikov, 1962; Reyn, Murray, and Birch-Andersen, 1963; Ovčinnikov and Delektorskij, 1965, 1966, 1970a, 1970b, 1971), but the findings have not yet been analysed in relation to the clinical aspects and varied course of the disease, and insufficient work has been done on the relationship between the gonococcus and the different cells in the discharge from infected tissues, particularly the relationship between treatment and the structure of L-forms in the pus. The solution of these problems may provide information useful both for diagnosis and for devising sound measures of gonorrhoea control.

Methods and material

The authors carried out electron microscope studies designed to clarify these problems. Uro-genital discharge from patients with gonorrhoea at different clinical stages was investigated. Material from fifteen male patients was studied, eight of whom had acute, five asymptomatic, and two chronic gonorrhoea. The terms 'acute', 'asymptomatic', and 'chronic' gonorrhoea are used as in the classification commonly accepted in the USSR. Gonorrhoea is designated as 'fresh' or 'chronic' according to its course. Fresh gonorrhoea (duration of disease up to 2 months) is sub-divided into acute, subacute, and asymptomatic. Disease with a benign course lasting more than 2 months is regarded as chronic; this stage may be manifested by exacerbation of the inflammatory process.

The method of processing the material for electron microscope study and the electron microscopy itself were as described by Ovčinnikov and Delektorskij (1971).

In all forms of untreated gonorrhoea, most of the gonococci are similar in structure and are situated intra- and extracellularly, but in some clinical forms specimens occur which are characteristic of a particular type of gonorrhoea. For example, polymorphic and atypical forms of gonococci occur in strains with reduced sensitivity to penicillin (Ovčinnikov, Delektorskij, and Afanas'ev, 1974).

Findings and comment

The structure of the gonococci in the discharge in acute cases of gonorrhoea has already been described (Ovčinnikov and Delektorskij, 1970, 1971). Most gonococci are situated extracellularly and take the form of a coccus, sometimes elongated with a dividing or divided nucleoid. Round each specimen there is a large number of round or cylindrical structures (Figs 1 and 2) and just beneath them is the outer wall. This outer wall was previously described by the present authors as consisting of three layers, but when the preparations were stained with Ruthenium red, an acid mucopolysaccharide marker, it became clear that it consisted of six layers (Fig. 3). Beneath the outer wall there is a cytoplasmic membrane, cytoplasm with granules (ribosomes)

scattered in it, and a star-shaped or round nuclear vacuole with filaments containing DNA.

Gonococci may be situated intracellularly, mostly in the phagosomes of polymorphonuclear leucocytes. The majority of gonococci inside leucocytes in acute gonorrhoea show no visible morphological changes, but lysed specimens occur.

It was found that, in all forms of untreated gonorrhoea, endocytobiosis takes place and that the gonococci within leucocytes remain viable. It must be remembered, however, that phagocytosis is a multistage process. First the leucocytes seize the gonococcus and enclose it in a phagosome, in which it is exposed to enzymes that stream into the phagosomes from numerous granules. Within the leucocyte a redistribution of the granules takes place (Fig. 4). Initially they are concentrated chiefly round phagosomes enclosing gonococci. They then disappear, and within leucocytes containing large numbers of gonococci that have undergone phagocytosis they become very few in number, while in leucocytes without gonococci they are numerous (Fig. 4). After the death of a leucocyte the released gonococci are again seized by other leucocytes and, already partly transformed by the granule enzymes, they undergo lysis or, if remaining extracellular, they continue to multiply.

In exacerbations of chronic gonorrhoea the picture is the same as in acute gonorrhoea, but as well as unchanged gonococci (Fig. 5) individual specimens with destroyed cytoplasm occur; the nuclear vacuole occupies almost the entire cell, and the outer wall and cytoplasmic membrane comprise a single layer (Fig. 5), so that the picture is that of an L-form. In exacerbations of chronic gonorrhoea before treatment and in asymptomatic gonorrhoea, large numbers of gonococci lie in groups alongside the epithelial cells, seldom penetrating into them (Fig. 6). The gonococci themselves are unchanged and are no different from the gonococci in acute gonorrhoea. Absence of penetration by the gonococcus into the interior of epithelial cells, together with the presence of individual gonococci in the cell cytoplasm itself, indicates that the pathogenic properties of the gonococci have decreased.

In asymptomatic gonorrhoea, the gonococci have the same structure as in exacerbations of chronic gonorrhoea and L-forms occur (Fig. 7), but in some patients with asymptomatic gonorrhoea intracellular gonococci are observed surrounded by multilayered membranes (Fig. 8, 8A, detail). L-forms of the gonococcus may also be surrounded by similar membranes (Fig. 9). In the course of asymptomatic gonorrhoea large phagosomes are found containing several gonococci, each of which is surrounded by membranes, all the gonococci having in addition another common multilayered membrane (Fig. 10).

Furthermore, in patients with untreated asymptomatic gonorrhoea (Figs 11 and 12), almost completely lysed gonococci (or on the other hand fully intact specimens) occur in phagosomes (Fig. 13). From this it appears that the cellular protection process operates effectively in patients with asymptomatic gonorrhoea but not effectively enough to destroy all gonococci. All this indicates that phagocytosis during the course of asymptomatic gonorrhoea bears features of its own.

Apparently the presence of gonococci enclosed in phagosomes with multilayered membranes also indicates that the cells isolate the gonococci, thus limiting the spread of the infection; on the other hand it is also possible that this has an unfavourable effect since drugs and antibodies may find such gonococci difficult to reach so that they remain viable inside the membranes and survive treatment. Later, if conditions are favourable, they may cause relapse. It is for this reason that in cases of asymptomatic gonorrhoea use should be made not only of antibiotics that act directly on the gonococci but also of agents that stimulate immune reactions and, possibly, autolytic processes, so as to destroy the multilayered phagosome membranes that have been formed.

Besides studying morphological changes in gonococci in relation to the clinical course of the disease, we have investigated changes in the gonococci in the urogenital discharge 3, 6, and 24 hours after the first dose of penicillin or kanamycin. Penicillin was given in cases of acute gonorrhoea at a dose of 200,000 units every 4 hours and kanamycin at a dose of 500 mg twice a day. The total dose of antibiotics was 3,000,000 units in acute gonorrhoea and 5,000,000 units in chronic and asymptomatic cases. Penicillin was given to seven patients and kanamycin to eight. Both antibiotics are clinically effective in gonorrhoea, but electron microscopy disclosed a striking difference: 3 hours after the administration of penicillin changes can already be seen in the gonococci (Fig. 14) and 6 to 24 hours after administration they are almost completely lysed inside and outside the cells (Figs 15 and 16) or they have disappeared altogether while the cells themselves are unchanged. On the other hand, 3 hours after the administration of kanamycin most of the gonococci, both extracellular (Figs 17 and 18) and intracellular (Fig. 19) are unaltered.

Legends and Figures 1-19 are arranged on pp. 232-241

FIG. 1 *Ultrathin section of material from a patient with asymptomatic gonorrhoea (before treatment), showing a gonococcus (G) which has undergone phagocytosis and appears unchanged inside a phagosome (ph). Mph—phagosome membrane; g—specific granules; N—leucocyte nucleus. × 11,000*

FIG. 2 *Ultrathin section of gonococcal discharge (before treatment). The gonococci (G) are extracellular, and there are large numbers of round or elongated structures (gs) around them. × 22,000*

FIG. 3 *Ultrathin section of a gonococcus culture in ascites-agar. Ruthenium red staining has revealed the 6-layered cell wall of the gonococcus, an outer homogeneous layer (hm), a membranous layer (m) consisting of a unit membrane, a granule layer (gl), and a cytoplasmic membrane (cm). × 240,000*

FIG. 4 *Ultrathin section of material from a patient with gonorrhoea (before treatment), showing leucocytes with gonococci which are undergoing phagocytosis, phagosomes (ph), specific granules (g) and leucocyte nucleus (N). × 8,420*

FIG. 5 *Ultrathin section of material from a patient with chronic gonorrhoea (before treatment). In addition to well-preserved gonococci (G) inside a phagosome (ph), there are specimens similar in structure to gonococcal L-forms (G¹). × 25,260*

FIG. 6 *Ultrathin section of material from a patient with chronic gonorrhoea (before treatment), showing large numbers of gonococci (G) round an epithelial cell (ec), which rarely penetrate into the cell. Also visible are leucocytes (pn) with specific granules (g). × 8,420*

FIG. 7 *Ultrathin section of material from a patient with asymptomatic gonorrhoea (before treatment), showing large numbers of gonococci of different sizes, similar in structure to L-forms (G¹). × 25,260*

FIG. 8 AND 8A (detail) *Ultrathin section of discharge from a patient with asymptomatic gonorrhoea (before treatment), showing multimembrane phagosomes (ph, Mph) enclosing unchanged gonococci (G). cw—cell wall, N¹—nucleoid. × 20,000; × 44,000*

FIG. 9 *Ultrathin section of material from a patient with asymptomatic gonorrhoea (before treatment), showing a multimembrane phagosome (ph, Mph) with a gonococcus similar in structure to L-forms (G¹). × 24,000*

FIG. 10 *Ultrathin section of material from a patient with asymptomatic gonorrhoea (before treatment), showing a multimembrane phagosome (ph) containing several gonococci (G) surrounded individually and collectively by multilayered membranes (Mph). M—mitochondria. × 24,000*

FIG. 11 *Ultrathin section of material from a patient with asymptomatic gonorrhoea (before treatment), showing a phagosome (ph) enclosing lysed gonococci (lg). N—leucocyte nucleus; g—specific granules. × 19,000*

FIG. 12 *Same as Fig. 11, showing a phagosome (ph) with lysed gonococci (lg), a leucocyte nucleus (N), and specific granules (g). × 19,000*

FIG. 13 *Ultrathin section of material from a patient with asymptomatic gonorrhoea (before treatment), showing fully intact gonococci (G) a clear-cut nucleoid (N¹), cell wall (cw), and mesosomes (Ms). There are gonococci in a phagosome (ph, Mph) and specific granules (g) can be seen. × 44,000*

FIG. 14 *Material from a patient with gonorrhoea 3 hours after administration of penicillin, showing a phagosome (ph, Mph) with lysed gonococci. × 40,000*

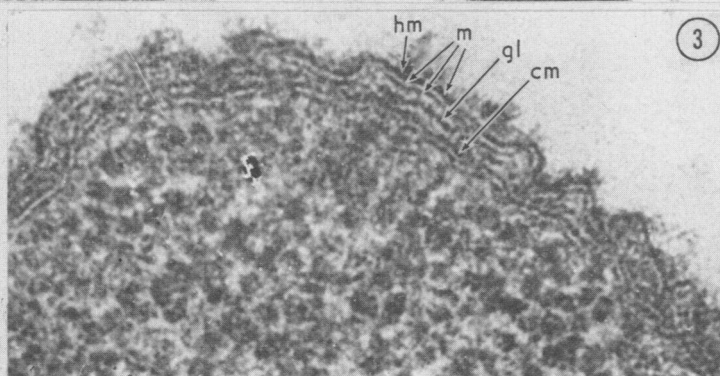
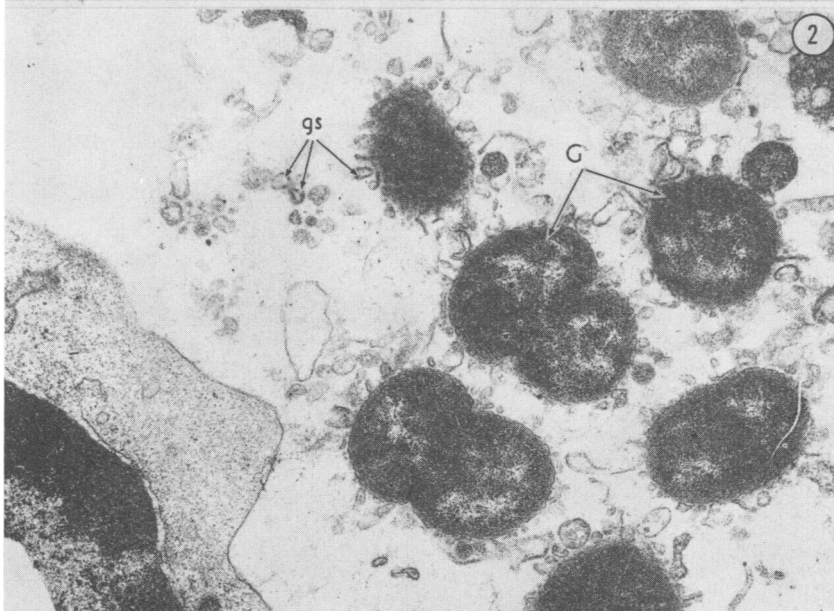
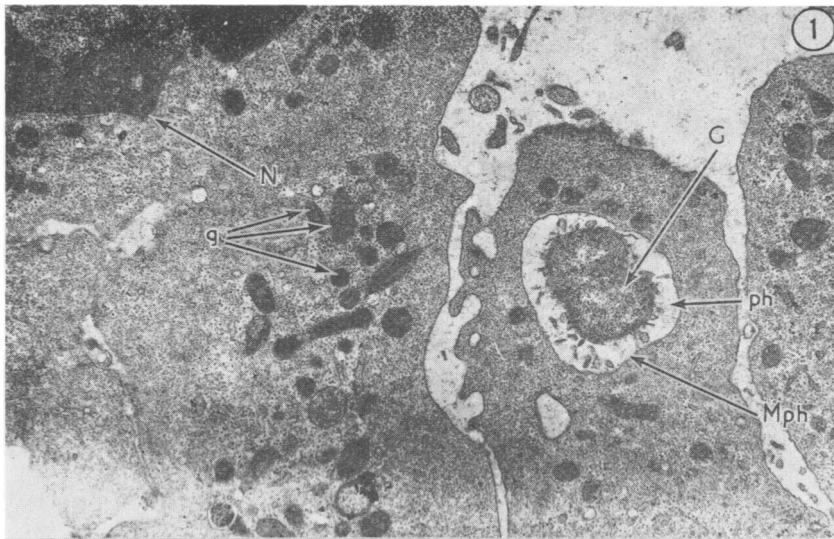
FIG. 15 *Material from a patient with gonorrhoea 6 hours after administration of penicillin. An intracellular gonococcus has been lysed (lg). × 26,600*

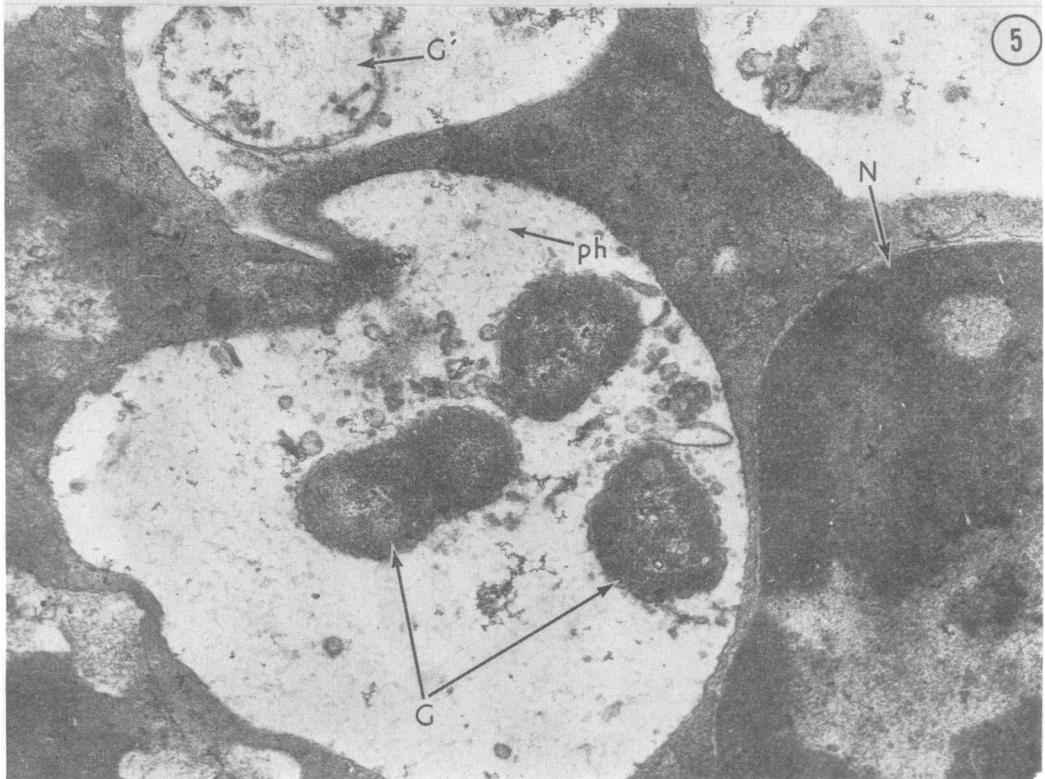
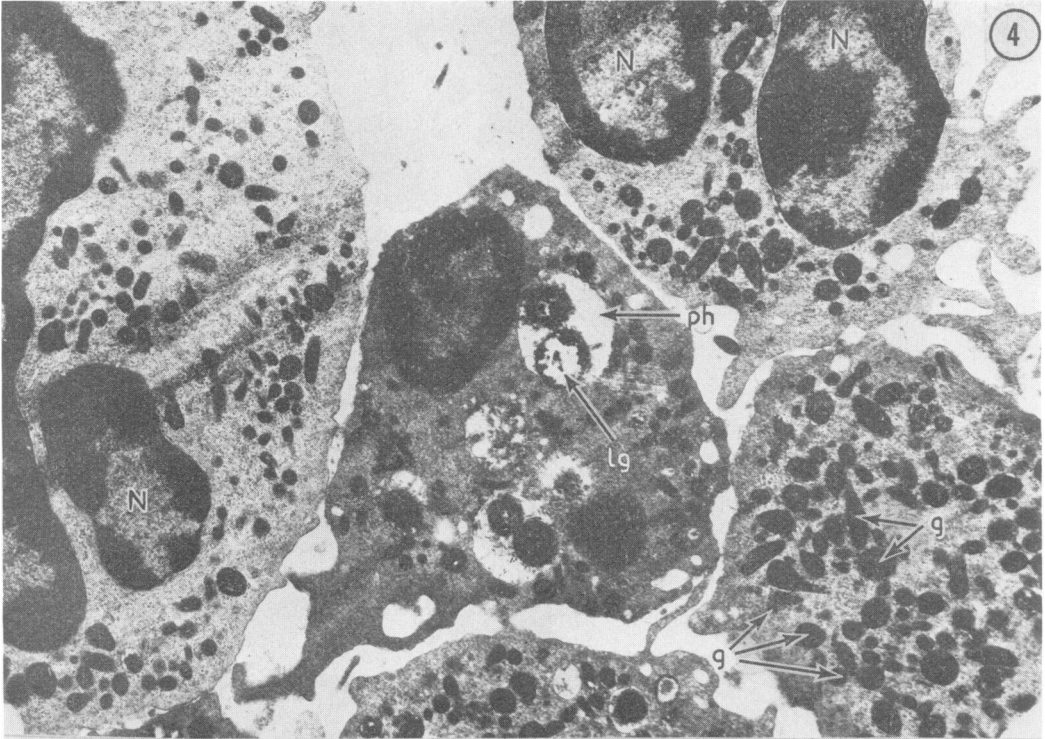
FIG. 16 *As in Fig. 15. A phagosome (ph) has seized a lysed gonococcus (lg). × 22,200*

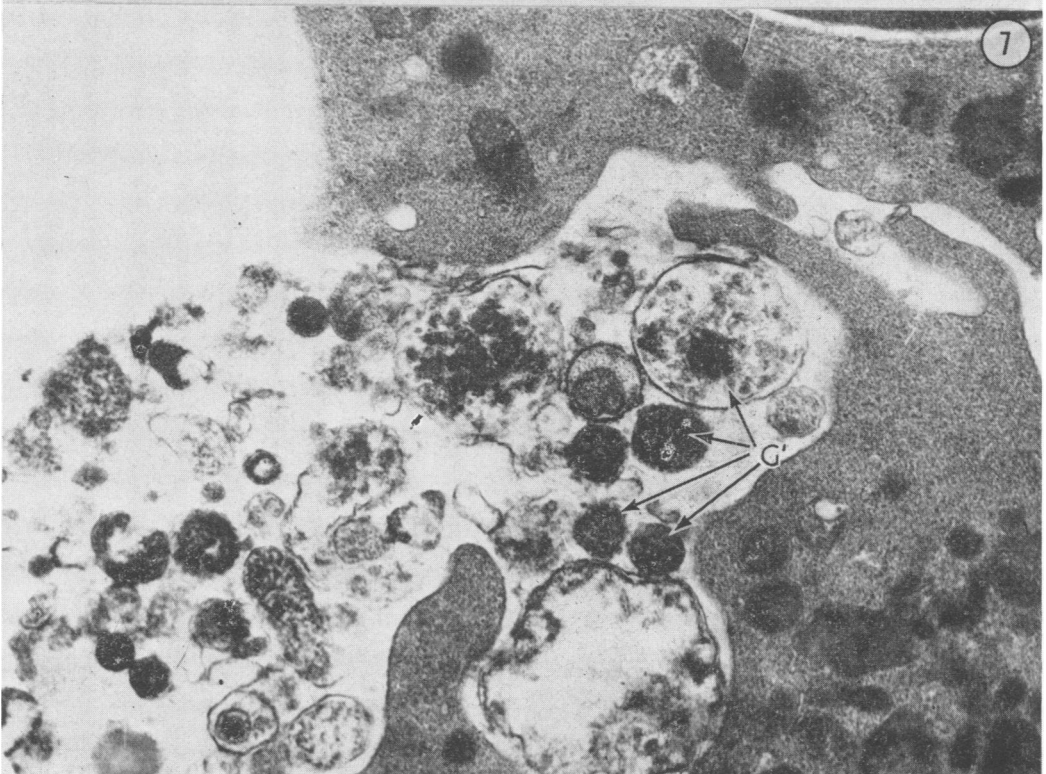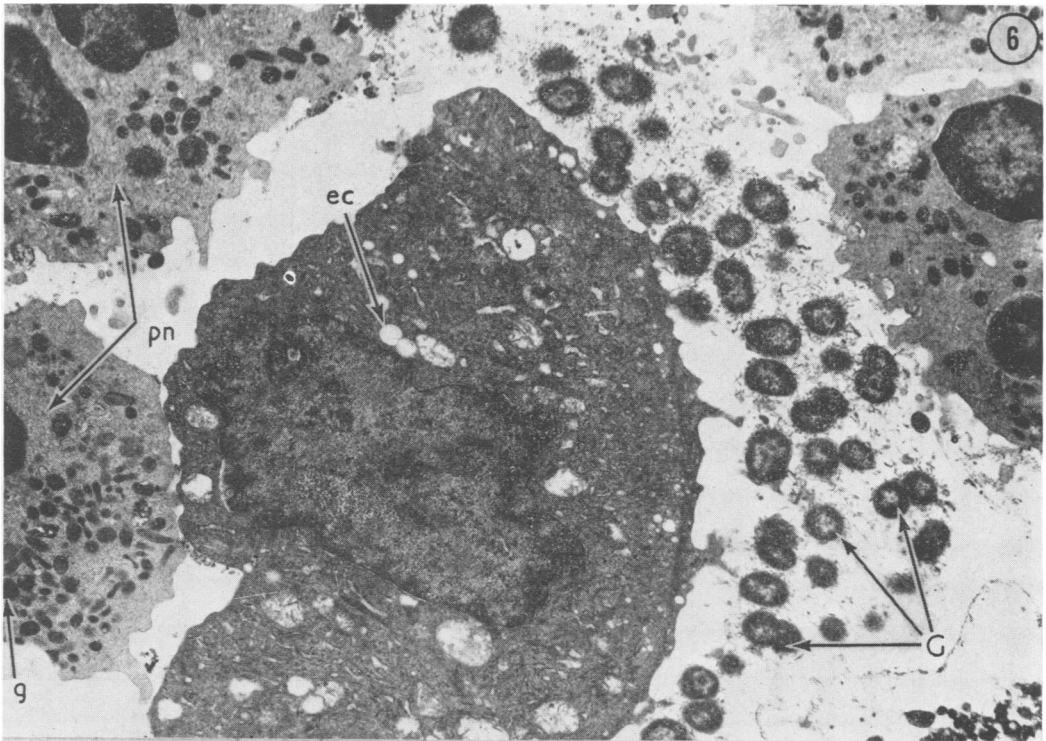
FIG. 17 *Material from a patient with asymptomatic gonorrhoea 3 hours after administration of kanamycin, showing extracellular gonococci (G), and a large number of round or elongated structures (gs) round the unchanged gonococci. × 26,600*

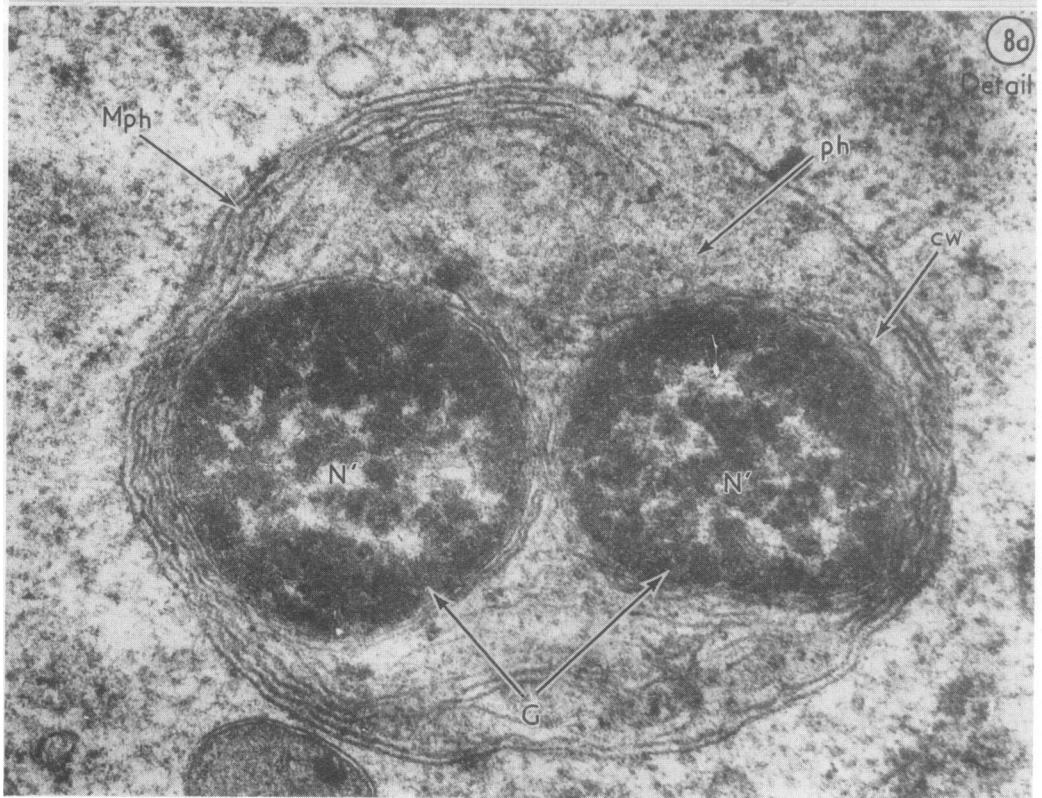
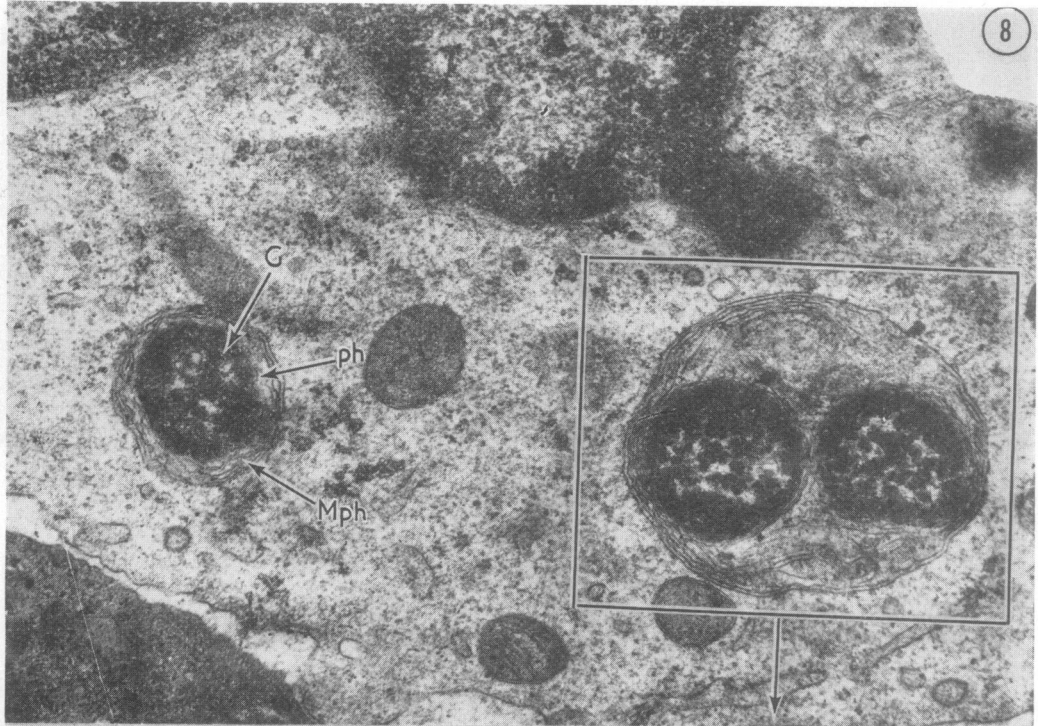
FIG. 18 *As in Fig. 17. × 24,000*

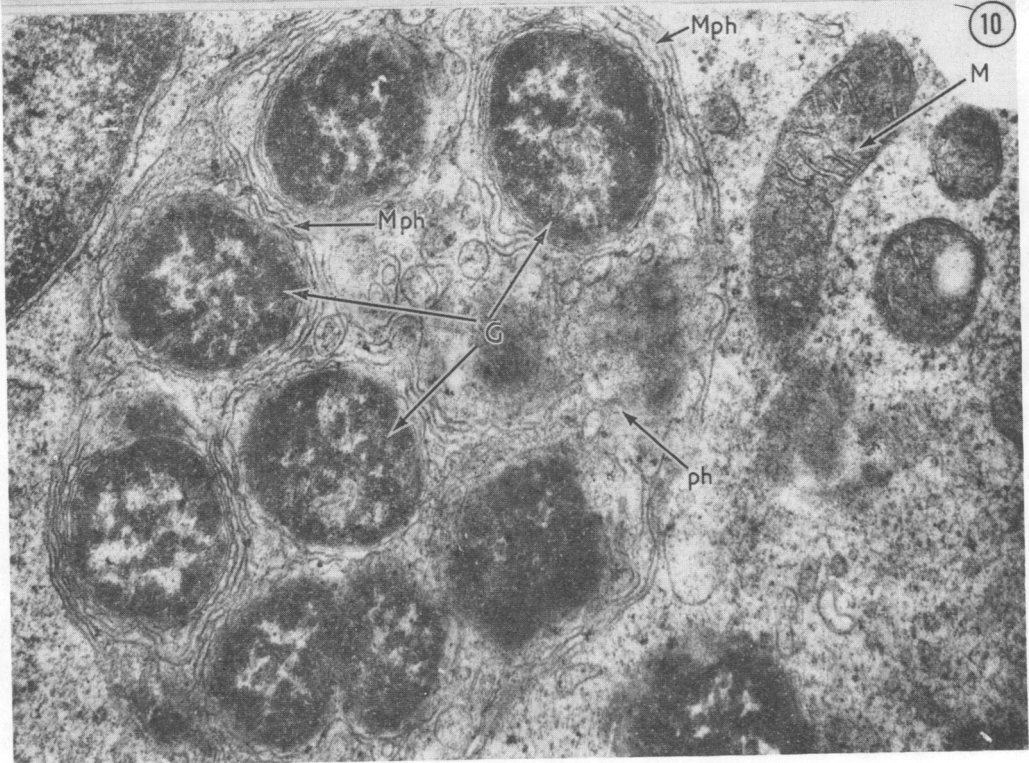
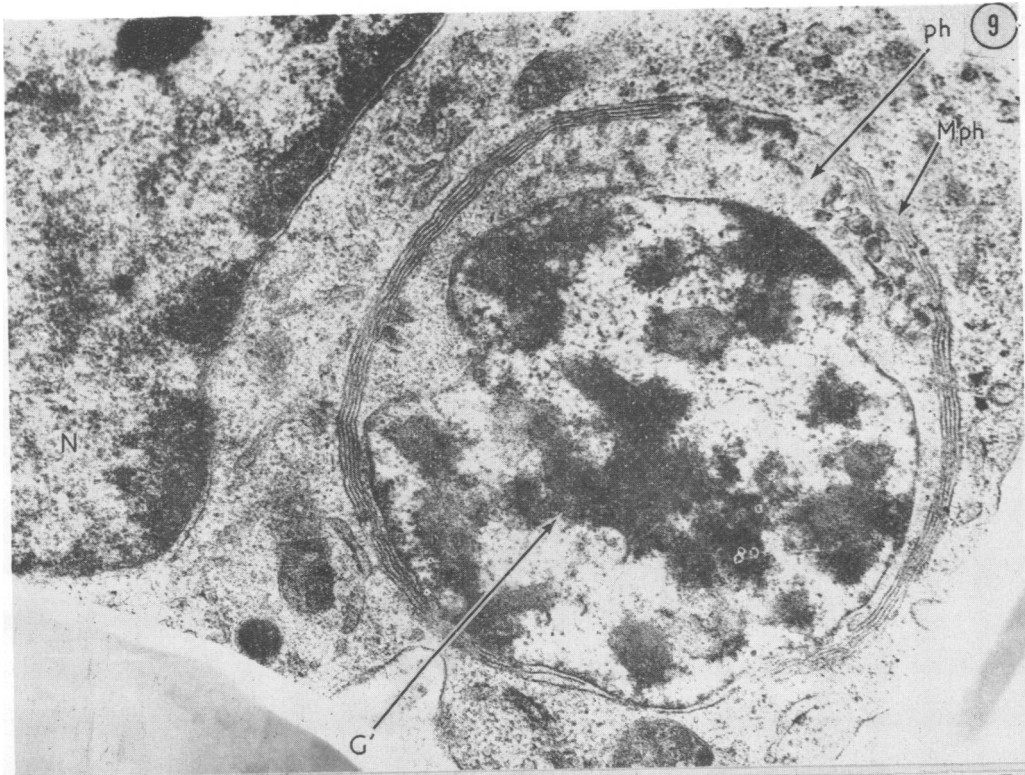
FIG. 19 *As in Figs. 17 and 18. The structure of the gonococcus has been well preserved. A cell wall (cw), a nucleoid (N¹), and a mesosome (Ms) can be seen. × 40,000*

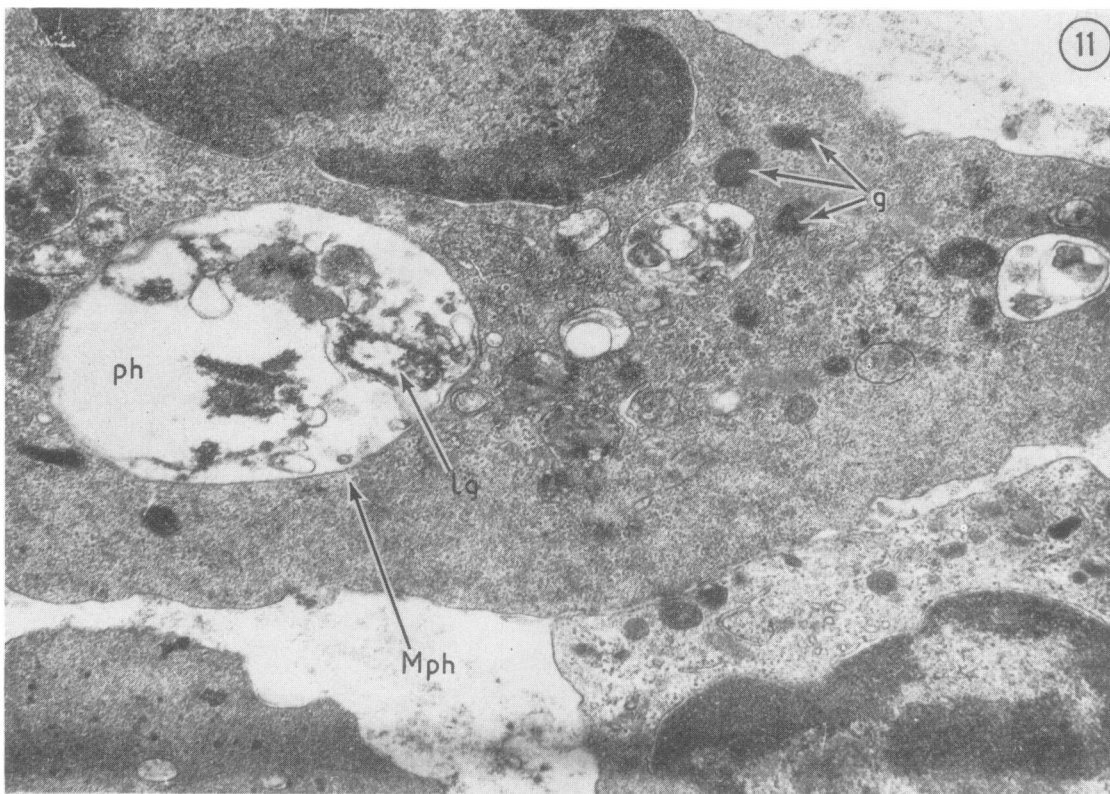




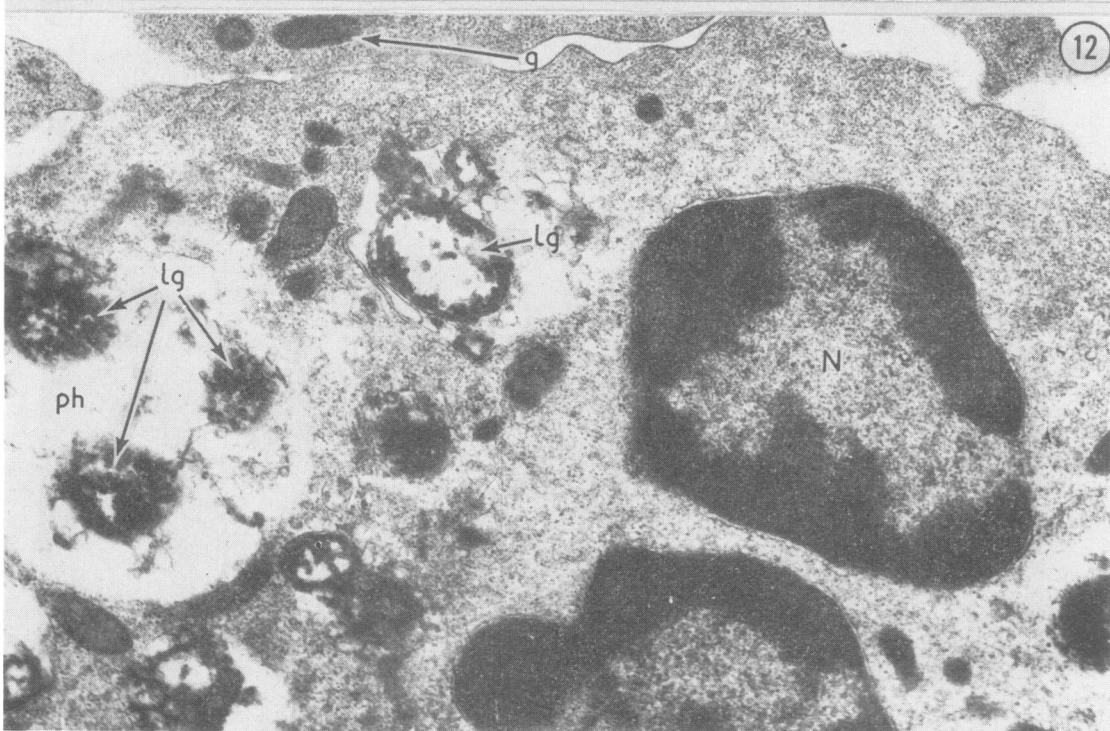




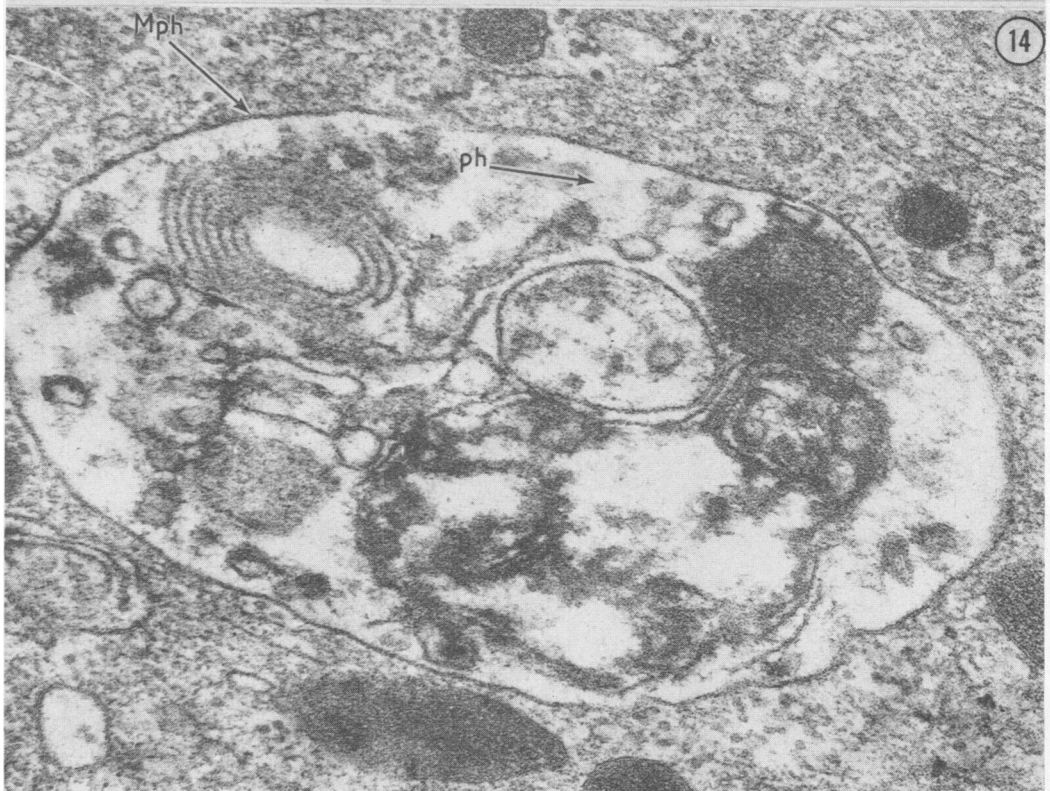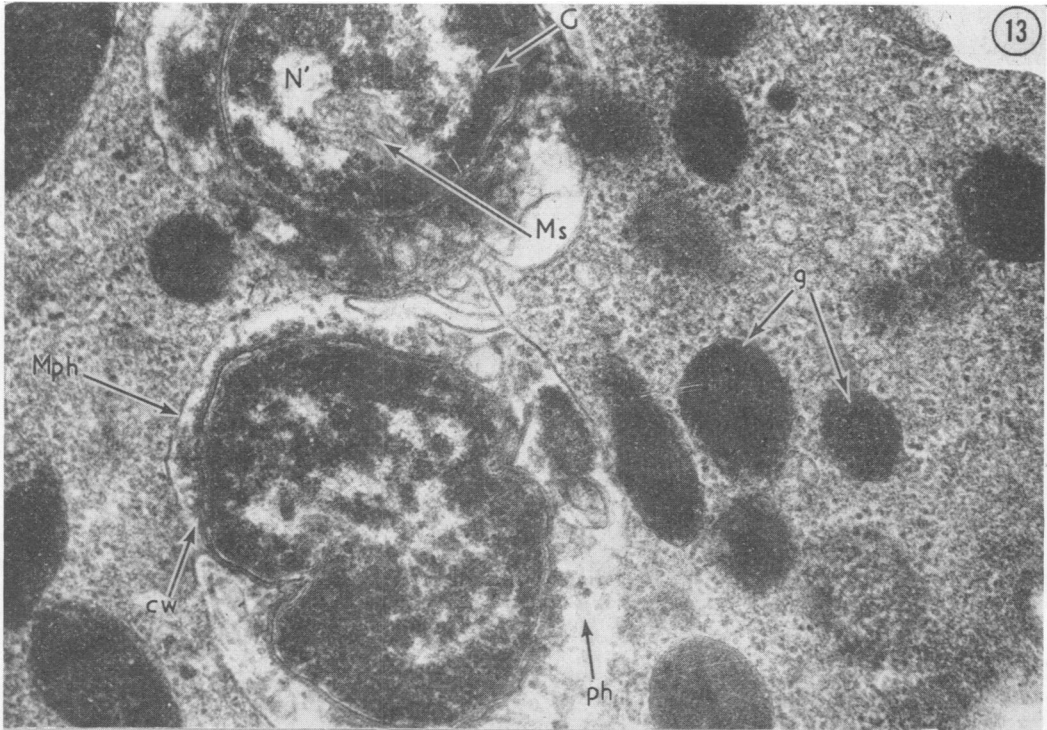


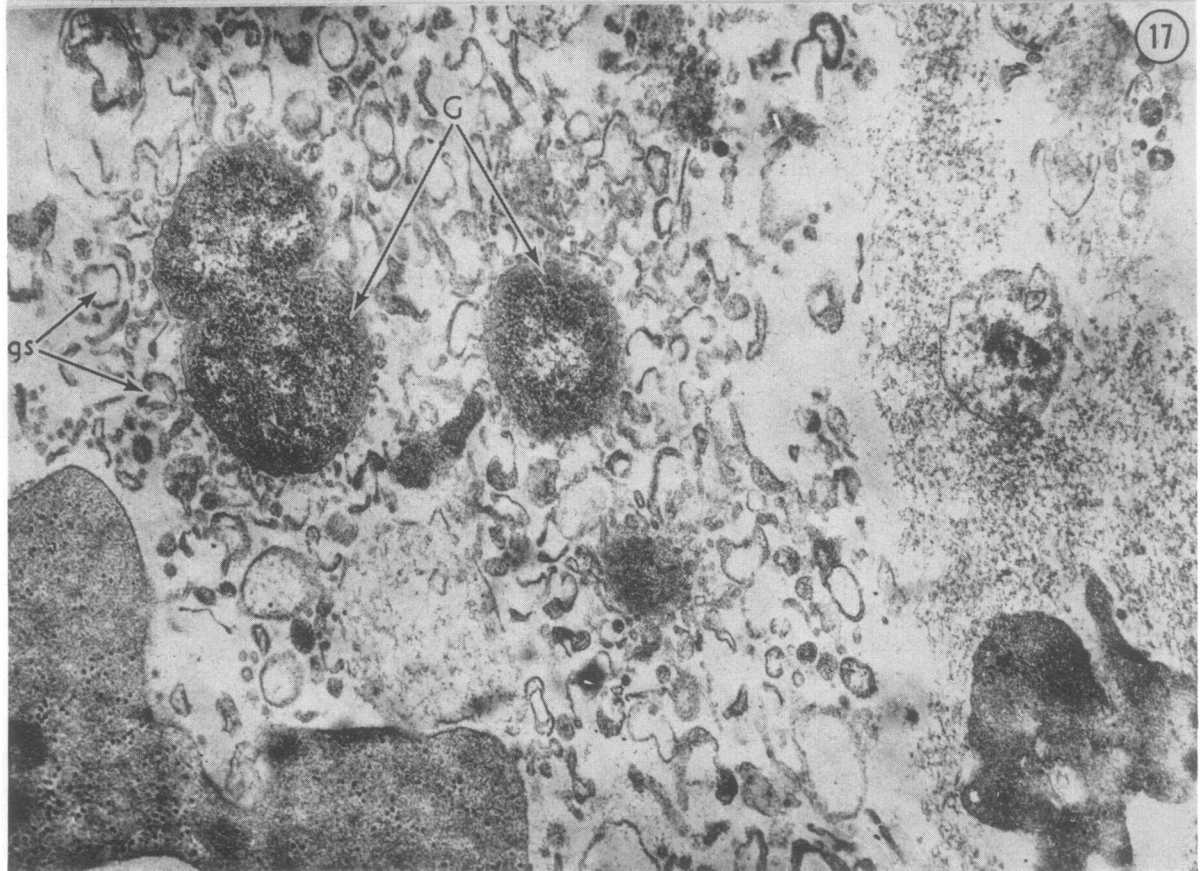
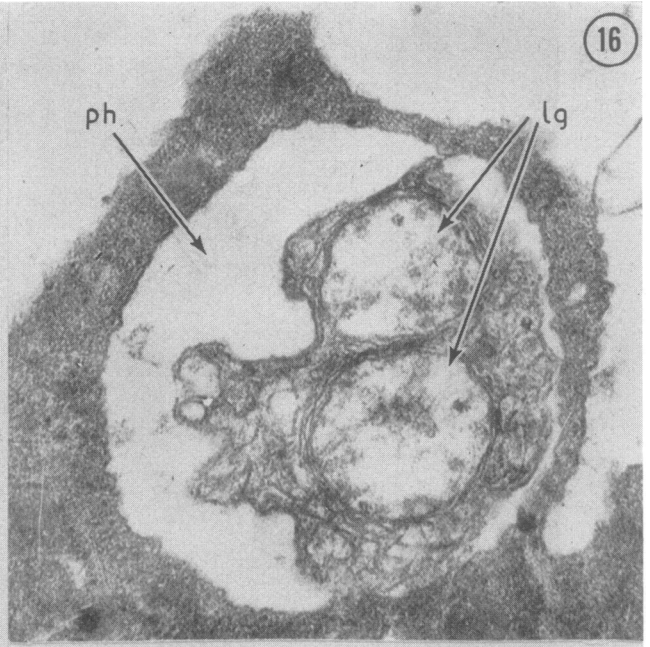
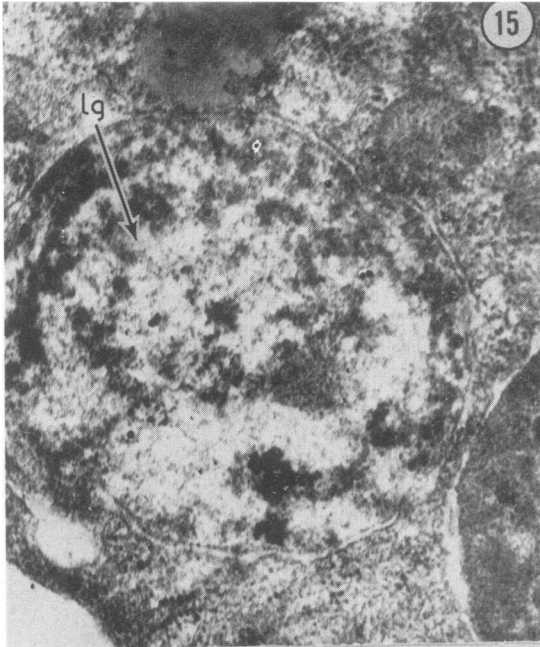


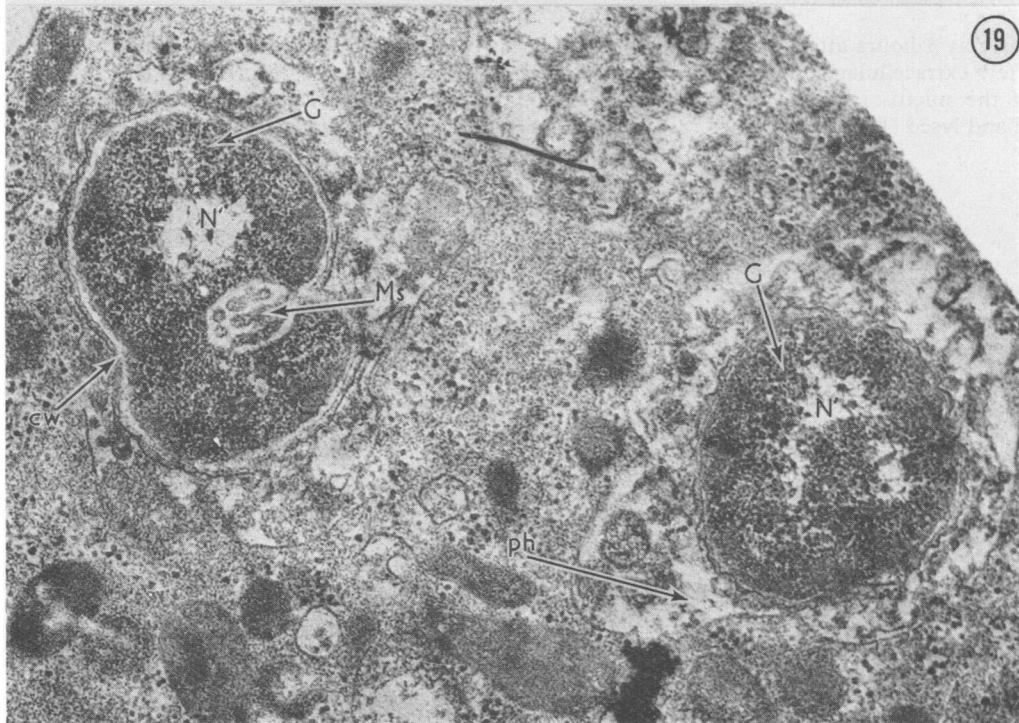
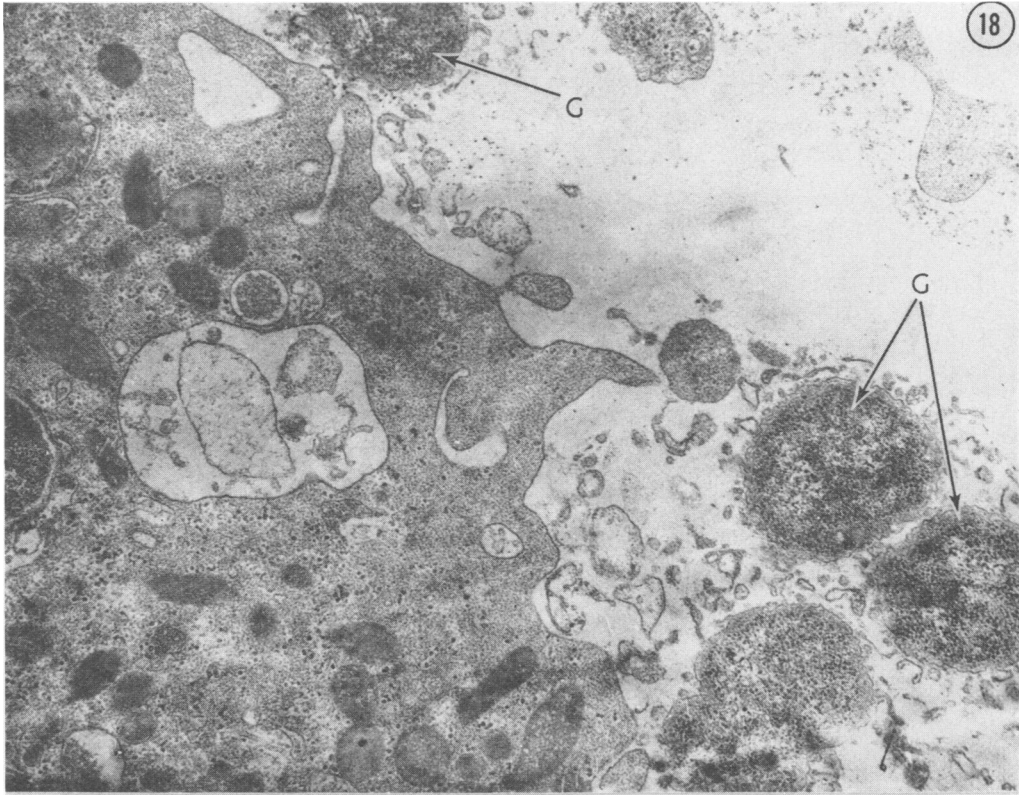
11

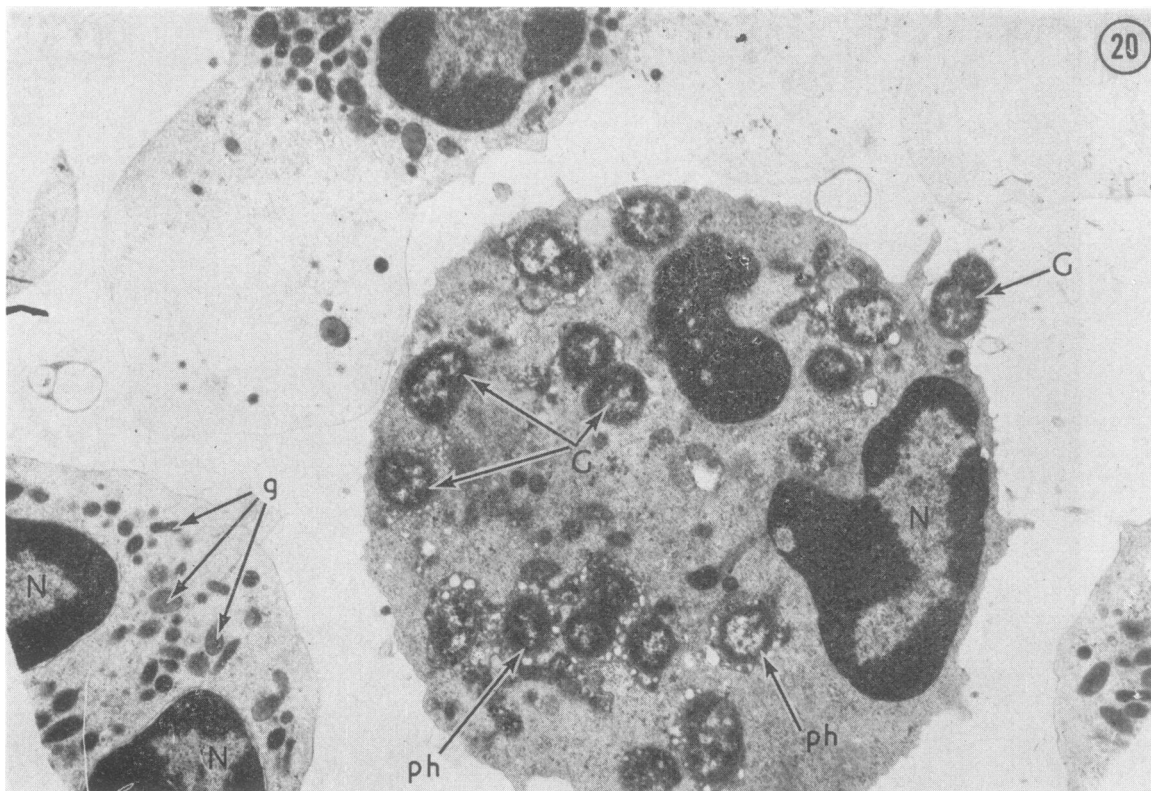


12



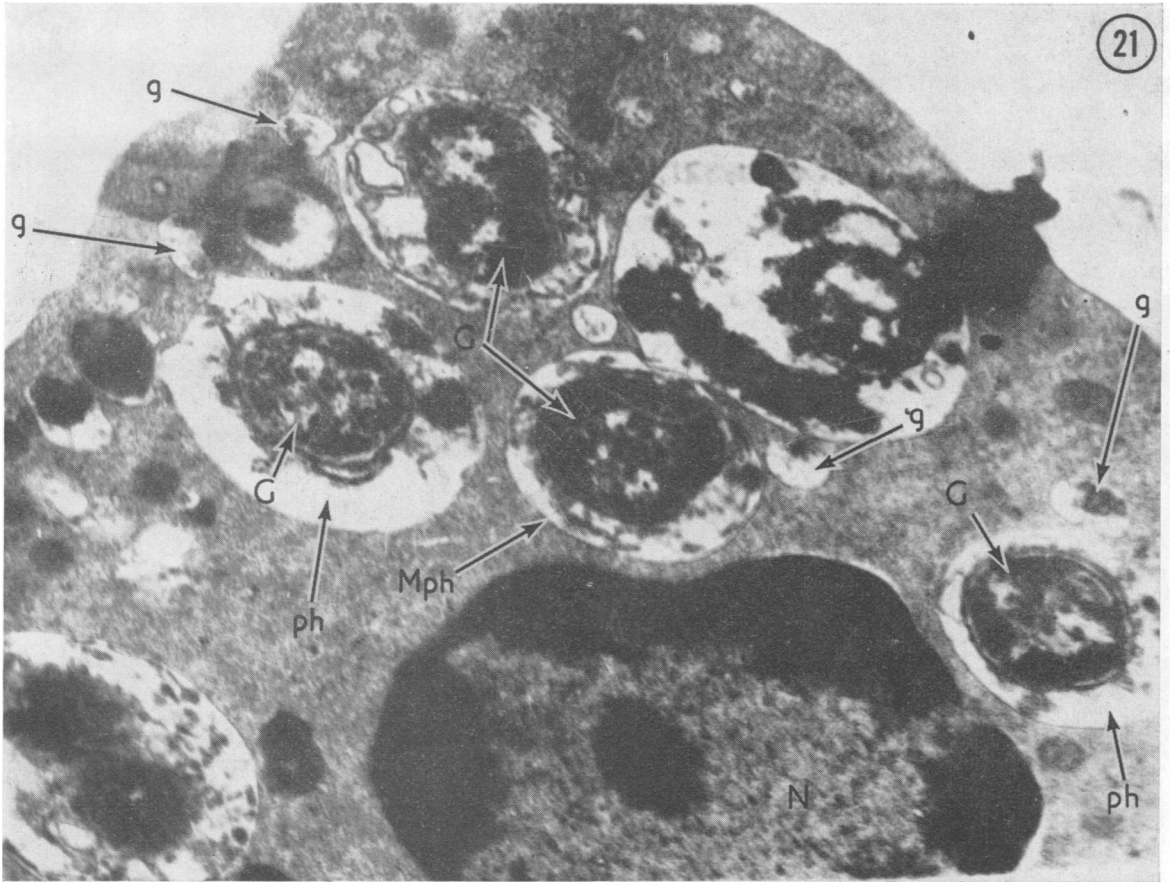






As early as 3 hours after penicillin administration only a few extracellular gonococci are observed, the bulk of the micro-organisms being already phagocytosed and lysed (Fig. 20).

FIG. 20 *Ultrathin section of material from a patient with acute gonorrhoea 3 hours after administration of penicillin. The bulk of the gonococci are inside a leucocyte. Phagosomes and phagolysosomes are formed. Active degranulation occurs in the cell that is usually observed during complete phagocytosis. It is indicated by disappearance of cytoplasmic granules from the leucocytes during phagocytosis of gonococci. An extracellular gonococcus is also present. An overwhelming majority of gonococci are intracellular at the very beginning of penicillin action. G—gonococcus; ph—phagosomes; g—specific granules. $\times 8,600$*



After 3 and 24 hours leucocytes are also encountered that contain gonococci in various stages of destruction (Figs 21 and 22), the structure of the leucocytes is intact, and there are granules streaming into the phagosome (Fig. 21).

FIG. 21 *Material from a patient with acute gonorrhoea 3 hours after administration of kanamycin showing gonococci (G) in different stages of lysis inside leucocytes. Specific granules (g) are streaming into the phagosomes (ph) and beginning enzymatic activity. $\times 25,000$*

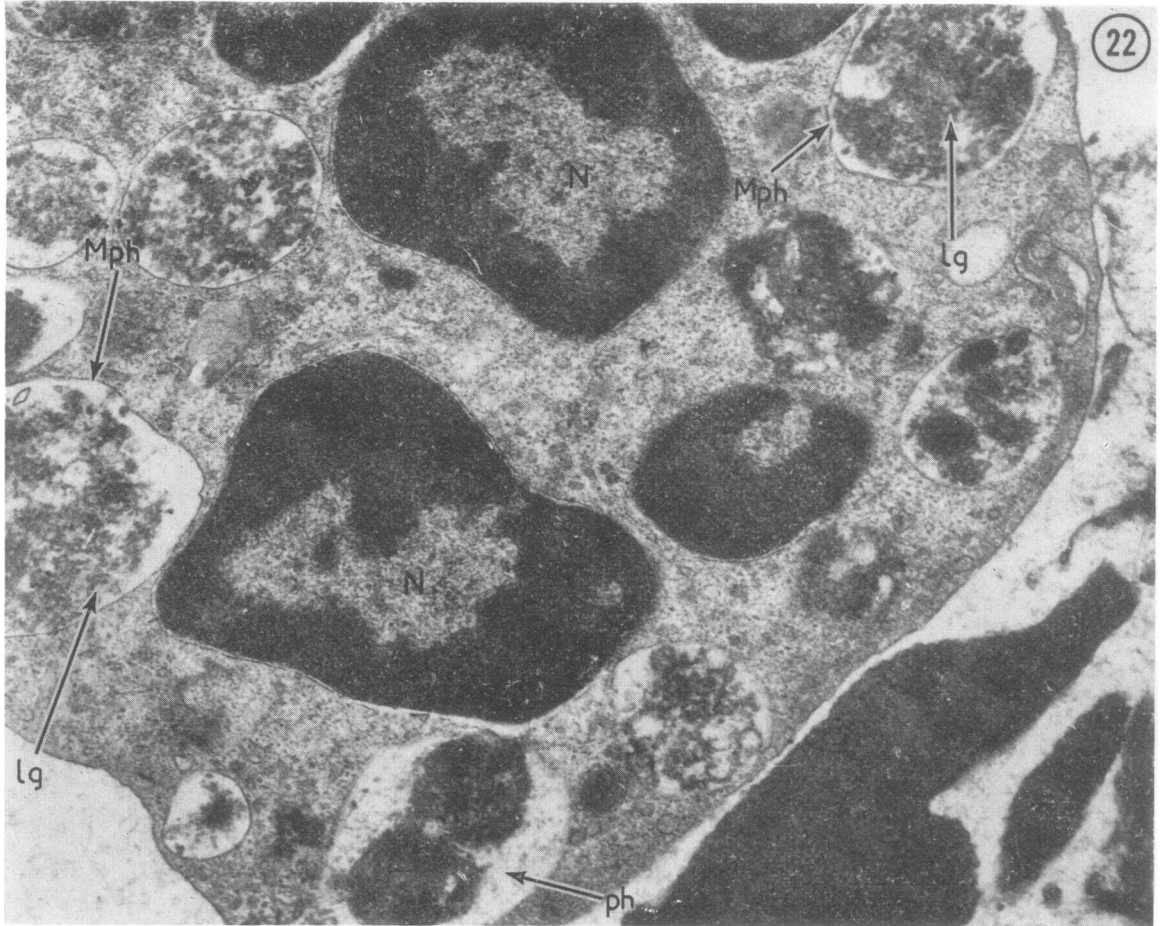


FIG. 22 24 hours after administration of kanamycin the gonococci inside phagosomes (ph, Mph) are in different stages of lysis (Lg). N—leucocyte nucleus. $\times 25,000$

Sometimes the cells that have contained the phagocytosed gonococci are destroyed and the phagosomes with their included gonococci are found as independent entities (Fig. 23) with a well-preserved structure. Apparently the effect of various preparations and antibodies on such gonococci will be slight.

It can be seen that in asymptomatic gonorrhoea destruction of the outer wall and cytoplasmic membrane commonly follows the administration of kanamycin. This suggests that kanamycin should be used when L-forms are present or when penicillin treatment is ineffective. However, in some cases, even after treatment with kanamycin, extracellular phagosomes are encountered with their membranes intact and the gonococci unchanged (Fig. 23), which means that kanamycin does not always destroy the membranes.

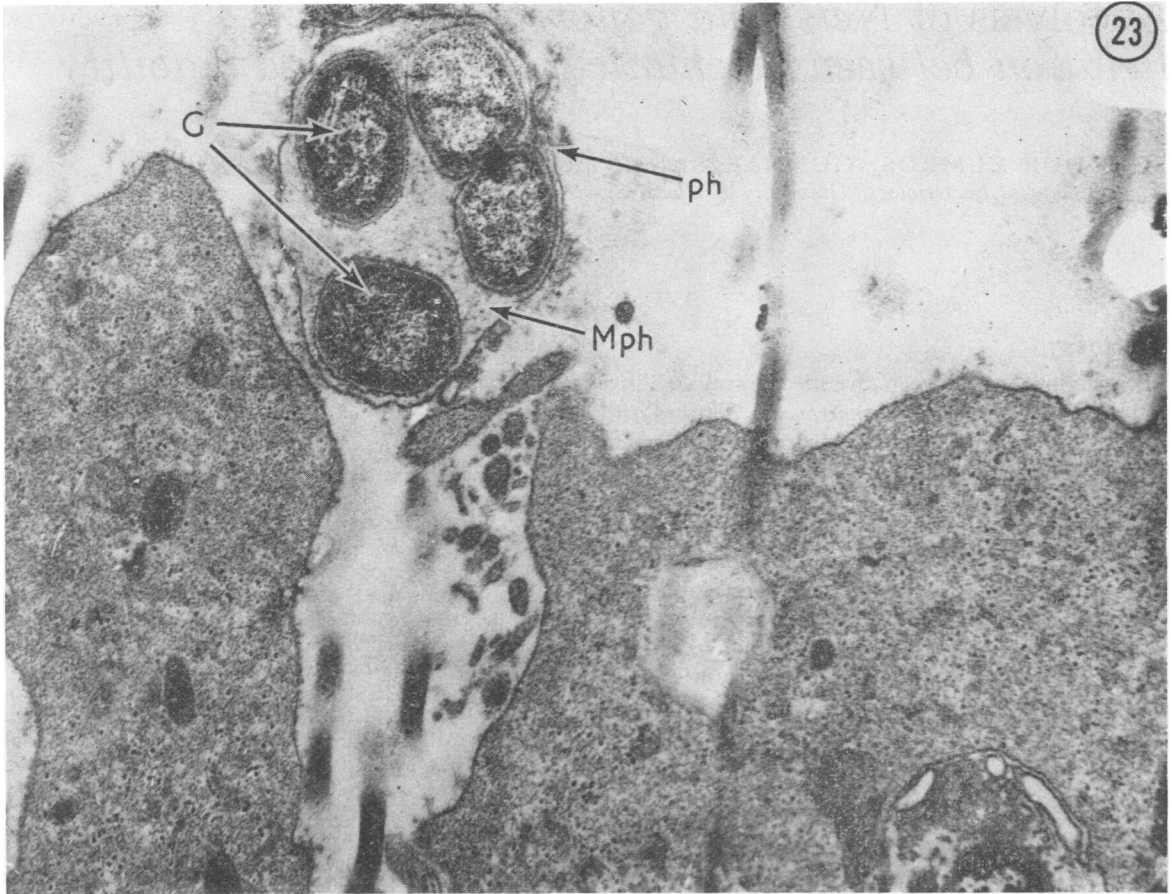


FIG. 23 Ultrathin section of material from a gonorrhoea patient 24 hours after administration of kanamycin. An extracellular phagosome (ph, Mph) is seen and unchanged gonococci (G) have accumulated inside it. $\times 20,000$

Conclusions

- (1) Ruthenium red staining reveals that the gonococcus possesses a six-layered cell wall.
- (2) Most of the gonococci in the urethral discharge are similar in structure in all clinical forms of gonorrhoea. Only a small number of gonococci have an atypical form that is more or less characteristic of, or is more frequently found in, a particular form of gonorrhoea. Thus, in exacerbations of chronic gonorrhoea, gonococci are observed that are similar in structure to the L-forms.
- (3) In asymptomatic gonorrhoea, gonococci may be found surrounded by numerous membranes. Gonococci surrounded by multilayered membranes may

be present; this is one of the factors that make for a protracted course and cause relapses.

(4) The existence of gonococci enclosed in a phagosome with multilayered membranes suggests that, in treating such cases, drugs which stimulate cellular protection or destroy the cell membrane should be used as well as antibiotics acting on the gonococci.

(5) A difference was noted between the action of penicillin and that of kanamycin. Kanamycin is effective both against typical forms of gonococci and against L-forms induced by penicillin.

References

- OVČINNIKOV, N. M. (1962) WHO Int./VDT/182 16 Nov.
and DELEKTORSKIJ, V. V. (1965) *Vestn. Derm. Vener.*,
No. 6, p.49
- (1966) WHO/VDT/RES/GON 1966, 16
— (1970a) *Vestn. Derm. Vener.*, No. 7, p.40
— (1970b) WHO/VDT/RES/GON 1970, 46
— (1971) *Brit. J. vener. Dis.*, **47**, 419
—, —, and AFANAS'EV, B. A. (1974) *Ibid.*, **50**, 179
- REYN, A., MURRAY, A. G., and BIRCH-ANDDERSEN, A. A.
(1963) WHO/VDT/RES/GON 1963, 1