

Genital chlamydial infections in patients attending a gynaecological outpatient clinic

J. PAAVONEN,* P. SAIKKU,† E. VESTERINEN,* B. MEYER,*
E. VARTIAINEN,* AND E. SAKSELA*

From the *I-II Departments of Obstetrics and Gynaecology, University Central Hospital, Helsinki, Finland, and †Department of Virology, University of Helsinki, Helsinki, Finland

SUMMARY Investigation for genital chlamydial infections was carried out on 160 patients of fertile age attending a gynaecological outpatient clinic. Thirteen (9%) of the 144 patients with valid specimens were found to be *Chlamydia*-positive. Seven (54%) of them had antichlamydial antibodies by the complement-fixation test, and 11 (85%) antichlamydial antibodies by a single-antigen immunofluorescence test compared with 21 (16%) and 70 (53%), respectively, of the 131 *Chlamydia*-negative patients. Patients with overt genital chlamydial infection often complained of ocular and urethral symptoms. Usually there was clinical evidence of cervical infection as well as of inflammation on cervicovaginal smears. Colposcopic and histological examinations did not show any specific alterations.

Introduction

Chlamydia trachomatis is an obligate, intracellular parasite causing trachoma, paratrachoma, lymphogranuloma venereum, and genitourinary infections in humans (Grayston and Wang, 1975; Schachter *et al.*, 1976). *C. trachomatis* is recognised as common in the genital tract of women attending clinics for venereal diseases as well as of the sexual partners of men with nongonococcal urethritis (NGU) (Richmond and Sparling, 1976; Schachter *et al.*, 1976; Alani *et al.*, 1977; Rees *et al.*, 1977).

Cervicitis and pelvic inflammatory disease in women may be aetiologically related to *Chlamydia* (Schachter *et al.*, 1967; Eschenbach *et al.*, 1975; Schachter *et al.*, 1975a; Mårdh *et al.*, 1977; Rees *et al.*, 1977). Because it may possibly be associated with cervical malignancy (Alexander, 1973; Schachter *et al.*, 1975b), this agent has also attracted attention as an important infective agent. Although chlamydial infections are not yet proved causes of cervical disease (Richmond and Sparling, 1976), it has been suggested that *Chlamydia* may make specific morphological alterations to cervical epithelial cells (Naib, 1970; Dunlop *et al.*, 1976). Women with genital chlamydial infection often show a serologically detectable immunological

response towards antigens of the organism (Richmond and Caul, 1975, 1977).

The aims of the present work were to study prospectively the incidence and nature of genital chlamydial infection in a sample population from a general gynaecological outpatient clinic and to evaluate the diagnostic value of the methods applied in the gynaecological routine.

Material and methods

PATIENTS

The sample population consisted of 160 patients of fertile age attending the gynaecological and obstetric outpatient clinics at Helsinki University Central Hospital in September and October 1976.

The patients did not have acute symptoms but were either being examined for gynaecological disease or were under observation for hormonal, fertility, or similar problems. Postmenopausal patients and those being treated with antibiotics or sulphonamides were excluded. The mean age of the patients was 29.5 years (range 17-49). Thirty-nine patients were fitted with intrauterine devices, 22 were taking oral contraceptives, and 81 used other methods or none at all, and 18 were pregnant.

CHLAMYDIAL ISOLATION AND SEROLOGY

Specimens for chlamydial isolation were collected with a sterile cottonwool swab from the endocervix

Address for reprints: J. Paavonen, MD, I Department of Obstetrics and Gynaecology, University Central Hospital, Haartmaninkatu 2, Helsinki, Finland 00290

Received for publication 3 January 1978

into two SP transport media (Dunlop *et al.*, 1972). Isolation attempts were done conventionally in irradiated McCoy cells (Darougar *et al.*, 1971). Gentamicin was used as antibiotic.

Serum antibodies were determined by complement-fixation (CF) and indirect immunofluorescence (IF) tests. CF group antigen was prepared by the acetone-ether method from *C. trachomatis* (kindly supplied by Dr C. Mordhorst, Statens Seruminstitut, Copenhagen, Denmark) and the test was done conventionally in a microsystem. For the IF test the following method modified from the original one (Dr P. Terho, Department of Virology, University of Turku) was used. The antigen slides were prepared by growing continuous untreated epithelioid dog kidney cells (kindly supplied by Dr N. Oker-Blom, Department of Virology, University of Helsinki) on slides in Petri dishes. The cells were infected with *C. trachomatis* serotype L2 to produce inclusions acting as the antigen in the test (Saikku and Paavonen, 1978).

CYTOLOGICAL AND HISTOLOGICAL TECHNIQUES

The cytological smears obtained from the posterior vaginal fornix, the ectocervix, and the endocervix were stained according to Papanicolaou's original method. Histological samples from *Chlamydia*-positive patients were obtained at colposcopy, fixed in formalin, and stained with van Gieson-haematoxylin or haematoxylin-eosin using routine methods.

Colposcopy was performed with a Zeiss-Oberkochen colposcope using magnification $\times 40$. Colposcopic classification of three grades was used as described in detail elsewhere (Timonen and Meyer, 1967).

VIROLOGICAL TEST AND ISOLATION OF OTHER MICRO-ORGANISMS

Herpes genitalis was diagnosed from virus isolation specimens obtained from the cervix (Leinikki and Salo, 1973), or from characteristic alterations

observed at the routine examination of the cytological smears, or from both (Naib *et al.*, 1966; Vesterinen *et al.*, 1977).

Genital condyloma accuminatum was diagnosed both clinically and cytologically (Purola and Savia, 1977). Cultivation of *Neisseria gonorrhoeae*, *Trichomonas vaginalis*, and yeast, as well as urine analysis for bacterial infection, was made by conventional methods (Lennette *et al.*, 1974).

Results

Thirteen (9%) of the 144 patients with valid isolation specimens harboured *Chlamydia*. In 16 patients the samples were contaminated by an overgrowth of mixed microbial flora.

Chlamydia group-specific antibodies determined by the CF test at a dilution of 1:8 or more were detected in seven (54%) of the 13 *Chlamydia*-positive patients and in 21 (16%) of the 131 *Chlamydia*-negative patients. *Chlamydia* group-specific antibodies at a level of 1:8 or more determined by a single-antigen IF test were detected in 11 (85%) of the *Chlamydia*-positive patients and in 70 (53%) of the *Chlamydia*-negative patients. IF test titres $\geq 1:64$ occurred in eight (62%) of *Chlamydia*-positive patients and in 25 (19%) of *Chlamydia*-negative patients (Table 1). The Figure compares antibodies detected by the CF and IF tests in sera from 13 *Chlamydia*-positive patients. Within two months one isolation-positive patient seroconverted (\geq fourfold rise in titre) by CF test and four patients by IF test.

Eight (62%) of the 13 *Chlamydia*-positive patients showed clinical cervicitis with or without cervical erosion (inflammation and hypertrophy of the cervix with mucopurulent discharge) compared with 43 (33%) of the 131 *Chlamydia*-negative patients. Thus, 16% of the 51 patients with cervical infection, 9% of the 22 patients with vaginitis only (inflamed vaginal mucosa and leucorrhoea without cervical infection), and 4% of the 71 patients with no cervicovaginal abnormalities harboured *Chlamydia*. How-

Table 1 *Chlamydia* antibody titres found in CF and IF tests of sera from patients attending a gynaecological outpatient clinic

No. of sera	<8	8	16	32	64	128	256	512	1024	Total	%	Total	%
										≥ 8 No.		≥ 64 No.	
<i>Chlamydia</i> -positive*													
CF 13	6	5	0	2	0	0	0	0	0	7	54	0	
IF 13	2	0	1	2	2	2	3	0	1	11	85	8	62
<i>Chlamydia</i> -negative													
CF 131	110	10	8	3	0	0	0	0	0	21	16	0	
IF 131	61	23	10	12	11	9	5	0	0	70	53	25	19

*Highest titre observed

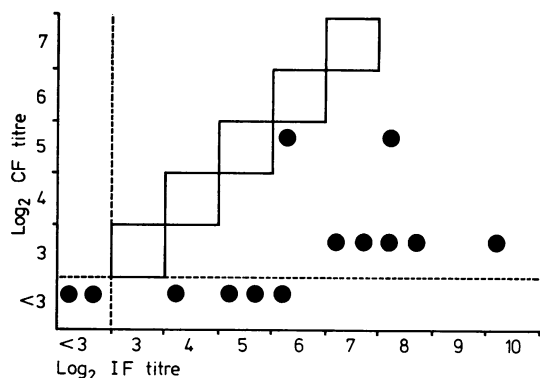


Figure Comparison of CF and IF test titres of sera from 13 *Chlamydia*-positive women

ever, *Chlamydia*-negative patients with cervicovaginal infection were significantly ($P < 0.005$) more often seropositive by IF test compared with patients with normal clinical findings (Table 2).

Four (31%) *Chlamydia*-positive patients and seven (5%) *Chlamydia*-negative patients complained of ocular and urethral symptoms. The sexual partners of three (23%) *Chlamydia*-positive women and four (3%) *Chlamydia*-negative women were known to have urethral symptoms (dysuria and urethral discharge). One of the *Chlamydia*-positive patients was using oral contraceptives, two had an IUD fitted, and two were pregnant, one in the first and the other in the second trimester.

Papanicolaou's cervicovaginal smears obtained from the *Chlamydia*-positive patients were classified as inflammatory (inflammatory cellular atypias with abundance of leucocytes) in 69% of patients compared with 42% of *Chlamydia*-negative patients. This difference was not however statistically significant ($P < 0.25$).

On colposcopy, grade I-II inflammation was observed in 11 of the *Chlamydia*-positive patients. The histological findings were: normal cervical epithelium in four patients, ectopy area with mild,

chronic infection in one, vaginitis with mild, ectocervical infection in two, and ectopy area with epidermisation in one. Colposcopic grade III inflammation was observed in two *Chlamydia*-positive patients. In the first instance the histological specimen showed a chronically infected ectopy area with squamous metaplasia and in the other a normal ectocervical epithelium with mild chronic and unspecific infection. Cytological and histological specimens were carefully screened for typical intracellular inclusions (Naib, 1970; Swanson *et al.*, 1975), but none was found.

Culture for yeast infection was positive in 14 patients, and for *N. gonorrhoeae* in five patients. Genital condylomata acuminata were diagnosed in eight patients. None of these patients had concomitant *Chlamydia*. One of the three patients with *T. vaginalis* infection and one of the four with herpes genitalis infection also excreted *Chlamydia*.

Discussion

The chlamydial isolation rate of 9% in 144 women from a general gynaecological outpatient population accords with the results of Schachter *et al.* (1975b), who found seven (8%) *Chlamydia*-positive patients out of 90 women attending a women's clinic for routine examination in San Francisco, but it is lower than the 12.7% isolation rate in women 'with symptoms' attending the same clinic (Schachter *et al.*, 1976). A higher incidence has been found in sexually more promiscuous groups, such as patients attending venereal disease clinics and contacts of men with NGU (Hobson *et al.*, 1974; Nayyar *et al.*, 1976; Richmond and Sparling, 1976; Alani *et al.*, 1977; Rees *et al.*, 1977).

The clinical picture of overt genital chlamydial infection was frequently non-specific cervicitis and cervical erosion. Similarly, Schachter *et al.* (1975a, 1976) have shown genital chlamydial infection to be associated with cervicitis and cervical erosion but not with vaginitis alone. Schachter *et al.* (1976) found an isolation rate of 34.7% among 170 women

Table 2 Comparison of clinical cervicovaginal findings and chlamydial isolation results with seropositivity

	No. of patients	Chlamydia-positive						Chlamydia-negative					
		No.		CF*		IF†		No.		CF*		IF†	
				No.	%	No.	%			No.	%	No.	%
Normal	71	3	4	1	33	1	33	68	96	6	9	6	9
Vaginitis only	22	2	9	2	100	2	100	20	91	5	25	8	40
Cervicitis/cervical erosion	51	8	16	4	50	5	67	43	84	10	23	11	26
	144	13						131					

*CF test titre $\geq 1:8$

†IF test titre $\geq 1:64$

D

with cervicitis. Hobson isolated *Chlamydia* in 63% of 35 women with hypertrophic cervical erosions (Hobson *et al.*, 1974). We found only 16% of the patients with cervical infection harboured *Chlamydia*, which may be because our patients were attending a gynaecological clinic rather than a clinic for the treatment of genital infections.

Ocular and urethral symptoms were significantly more common in patients with overt chlamydial infection (excretion from the cervix) than in *Chlamydia*-negative patients. Other micro-organisms examined in our study could not explain these symptoms, since yeast, condylooma accuminatum, and *N. gonorrhoeae* were not detected concomitantly with *Chlamydia*, and herpes genitalis and *T. vaginalis* were detected in only one case together with *Chlamydia*.

Much attention has recently been paid to cytology as a rapid method for diagnosing viral infections. The cytological diagnosis of herpes genitalis has been established (Naib *et al.*, 1966; Vesterinen *et al.*, 1977). Cytomegalovirus (Vesterinen *et al.*, 1975) and adenovirus (Vesterinen *et al.*, 1978) can also cause specific alterations in human cervical epithelial cells *in vitro*. Specific cytopathic alterations induced by *Chlamydia* in human cervical epithelium in clinical cases have been presented (Swanson *et al.*, 1975). In the present work special attention was paid to such alterations in cervicovaginal smear preparations and histological samples, but none was found. A non-specific inflammatory picture dominated in *Chlamydia*-positive cases indicating that cytomorphological methods are unrewarding in the diagnosis of genital chlamydial infections. Non-specific inflammatory changes have been regularly found in the cervical smears of female contacts of men with NGU (Simmons and Vosmik, 1974). Naib has recognised typical clusters of intracytoplasmic inclusions in epithelial parabasal cells in addition to an abundance of leucocytes and histiocytes in cervicovaginal smears of mothers of newborn infants with suspected chlamydial infection (Naib, 1970). However, no patient in the third trimester of pregnancy was included in our study.

Determining chlamydial group-specific antibodies by the CF test only is unrewarding in genital tract infections which tend to limit themselves to the epithelium (Grayston and Wang, 1975; Richmond and Caul, 1975). We found, however, that 54% of women with proved cervical chlamydial infection had CF antibodies, compared with 16% of *Chlamydia*-negative women. This is in accordance with the results of Schachter *et al.* (1975b), who observed that 57.5% of 40 women with overt chlamydial infection had CF antibodies.

The new modification of a single-antigen IF test applied in the present study appeared to be sensitive. *C. trachomatis* LGV-serotype L2 has been shown by IF tests to give crossreaction with antibodies to most important genital chlamydial serotypes (Orlén *et al.*, 1975). Reactive sera occurred to 85% of the *Chlamydia*-positive patients and in 53% of the *Chlamydia*-negative patients. However, only 19% of the *Chlamydia*-negative patients were seropositive at IF test titre $\geq 1:64$ as compared with 62% of the *Chlamydia*-positive patients. Similarly, Richmond and Caul (1975, 1977), using another single-antigen IF test, noted reactive sera in 88% of culture-positive and in 49% of culture-negative women attending a venereal disease clinic.

It was noteworthy that the seropositivity rate was high among *Chlamydia*-negative patients with signs of cervicovaginal infection (Table 2). This may be attributed to a past chlamydial infection or to the insensitivity of current isolation methods for *C. trachomatis*. Perhaps the serum antibodies even at high titres are not diagnostic for an active infection, since such antibody titres are also seen in isolation-negative patients (Table 1). More knowledge about the kinetics and duration of the serological response to chlamydial infection is needed.

Non-specific genital infection in women seems to be a major epidemiological problem as a reservoir of *Chlamydia*, particularly because of the difficulty in identifying chronic and latent infections.

Our study gives further evidence of the pathogenicity of *C. trachomatis* in the female genital tract. The non-specific clinical and cytomorphological picture of this infection requires that reliable isolation facilities are generally available in gynaecological practice.

We wish to express sincere thanks to Mrs Hellä Sarjakivi for her technical assistance in the CF and IF antibody assays, and to Mrs Tuula Nieminen for efficiently carrying out the secretarial work. We also thank Miss Marja-Leena Kauppinen, who kindly and reliably assisted in the collection of the specimens.

This study was aided by a grant from the Paulo Foundation and Finnish Cultural Foundation.

References

- Alani, M. D., Darougar, S., Burns, D. C. MacD., Thin, R. N., and Dunn, H. (1977). Isolation of *Chlamydia trachomatis* from the male urethra. *British Journal of Venereal Diseases*, 53, 88-92.
- Alexander, E. R. (1973). Possible etiologies of cancer of the cervix other than herpesvirus. *Cancer Research*, 2, 1485-1496.
- Darougar, S., Kinnison, J. R., and Jones, B. R. (1971). Simplified irradiated McCoy cell culture for isolation of Chlamydiae. In *Trachoma and Related Disorders*, p. 63. Edited by R. L. Nichols. Excerpta Medica: Amsterdam.

- Dunlop, E. M. C., Goldmeier, D., Darougar, S., and Jones, B. R. (1976). *Chlamydia* infection of the genital tract in the mothers and fathers of babies suffering from ophthalmia neonatorum due to TRIC agent. In *Sexually Transmitted Diseases*, p. 83. Edited by R. D. Catterall and C. S. Nicol. Academic Press: London.
- Dunlop, E. M. C., Vaughan-Jackson, J. D., and Darougar, S. (1972). Chlamydial infection. Improved methods of collection of material for culture from the urogenital tract and rectum. *British Journal of Venereal Diseases*, **48**, 421-424.
- Eschenbach, D. A., Buchanan, T. M., Pollock, H. M., Forsyth, P. S., Alexander, E. R., Lin, J.-S., Wang, S.-P., Wentworth, B. B., McCormack, W. M., and Holmes, K. K. (1975). Polymicrobial etiology of acute pelvic inflammatory disease. *New England Journal of Medicine*, **293**, 166-171.
- Grayston, J. T., and Wang, S.-P. (1975). New knowledge of chlamydiae and the diseases they cause. *Journal of Infectious Diseases*, **132**, 87-105.
- Hobson, D., Johnson, F. W. A., Rees, E., and Tait, I. A. (1974). Simplified method for diagnosis of genital and ocular infections with *Chlamydia*. *Lancet*, **2**, 555-556.
- Leinikki, P., and Salo, O. P. (1973). Genital herpes. Virological diagnosis and antibody response. *Acta dermato venerologica*, **53**, 65-70.
- Lennette, E. H., Spaulding, E. H., and Truant, J. P. (1974). *Manual of Clinical Microbiology*, second edition, pp. 124-129; 491-507; 582-601. American Society for Microbiology: Washington DC.
- Mårdh, P.-A., Ripa, T., Svensson, L., and Weström, L. (1977). Role of *Chlamydia trachomatis* infection in acute salpingitis. *New England Journal of Medicine*, **296**, 1377-1379.
- Naib, Z. M. (1970). Cytology of TRIC agent infection of the eye of newborn infants and their mothers' genital tracts. *Acta cytologica*, **14**, 390-395.
- Naib, Z. M., Nahmias, A. J., and Josey, W. E. (1966). Cytology and histopathology of cervical herpes simplex infection. *Cancer*, **19**, 1026-1031.
- Nayyar, K. C., O'Neill, J. J., Hambling, M. H., and Waugh, M. A. (1976). Isolation of *Chlamydia trachomatis* from women attending a clinic for sexually transmitted diseases. *British Journal of Venereal Diseases*, **52**, 396-398.
- Oriel, J. D., Reeve, P., Thomas, B. J., and Nicol, C. S. (1975). Infection with *Chlamydia* group A in men with urethritis due to *Neisseria gonorrhoeae*. *Journal of Infectious Diseases*, **131**, 376-382.
- Puroola, E., and Savia, E. (1977). Cytology of gynecologic condyloma acuminatum. *Acta cytologica*, **21**, 26-31.
- Rees, E., Tait, A., Hobson, D., and Johnson, F. W. A. (1977). *Chlamydia* in relation to cervical infection and pelvic inflammatory disease. In *Non-gonococcal Urethritis and Related Infections*, p. 67. Edited by D. Hobson and K. K. Holmes. American Society for Microbiology; Washington DC.
- Richmond, S. J., and Caul, E. O. (1975). Fluorescent antibody studies in chlamydial infections. *Journal of Clinical Microbiology*, **1**, 345-352.
- Richmond, S. J., and Caul, E. O. (1977). Single-antigen indirect immunofluorescence test for screening venereal disease populations for chlamydial antibodies. In *Non-gonococcal Urethritis and Related Infections*, p. 259. Edited by D. Hobson and K. K. Holmes. American Society for Microbiology: Washington DC.
- Richmond, S. J., and Sparling, P. F. (1976). Genital chlamydial infections. *American Journal of Epidemiology*, **103**, 428-435.
- Saikku, P., and Paavonen, J. (1978). Single-antigen immunofluorescent test for Chlamydial antibodies. *Journal of Clinical Microbiology*, in press.
- Schachter, J., Causse, G., and Tarizzo, M. L. (1976). Chlamydiae as agents of sexually transmitted diseases. *Bulletin of the World Health Organisation*, **54**, 245-254.
- Schachter, J., Hanna, L., Hill, E. C., Massad, S., Sheppard, C. W., Conte, J. E., Jr, Cohen, S. N., and Meyer, K. F. (1975a). Are chlamydial infections the most prevalent venereal disease? *Journal of the American Medical Association*, **231**, 1252-1255.
- Schachter, J., Hill, E. C., King, E. B., Coleman, V. R., Jones, P., and Meyer, K. F. (1975b). Chlamydial infection in women with cervical dysplasia. *American Journal of Obstetrics and Gynecology*, **123**, 753-757.
- Schachter, J., Rose, L., and Meyer, K. F. (1967). The venereal nature of inclusion conjunctivitis. *American Journal of Epidemiology*, **85**, 445-452.
- Simmons, P. D., and Vosmik, F. (1974). Cervical cytology in non-specific genital infection. An aid to diagnosis. *British Journal of Venereal Diseases*, **50**, 313-314.
- Swanson, J., Eschenbach, D. A., Alexander, E. R., and Holmes, K. K. (1975). Light and electron microscopic study of *Chlamydia trachomatis* infection of the uterine cervix. *Journal of Infectious Diseases*, **131**, 678-687.
- Timonen, S., and Meyer, B. (1967). Colposcopic and cytological diagnosis of cervical cancer and premalignant lesions. *Annales chirurgiae et gynaecologiae Fenniae*, **56**, Supplement 158, 3-17.
- Vesterinen, E., Leinikki, P., and Saksela, E. (1975). Cytopathogenicity of cytomegalovirus to human ecto- and endo-cervical epithelial cells *in vitro*. *Acta cytologica* **19**, 473-481.
- Vesterinen, E., Puroola, E., Saksela, E., and Leinikki, P. (1977). Clinical and virological findings in patients with cytologically diagnosed gynecologic herpes simplex infections. *Acta cytologica*, **21**, 199-205.
- Vesterinen, E., Vahevi, A., Paavonen, J., and Saksela, E. (1978). Adenovirus infection and cytopathic alterations of the human cervical epithelial cells *in vitro*. *Acta cytologica*, in press.