

A Comprehensive Narrative Review of Ixekizumab Efficacy in Nail Psoriasis from Clinical Trials for Moderate-to-Severe Psoriasis and Psoriatic Arthritis

Authors

Bruce W Kirkham¹, Alexander Egeberg^{2,3}, Frank Behrens⁴, Andreas Pinter⁵, Joseph F Merola⁶, Thorsten Holzkämper⁷, Gaia Gallo⁷, Khai Jing Ng⁷, Rebecca Bolce⁷, Christopher Schuster^{7,8}, Peter Nash⁹, Luis Puig¹⁰.

Author Affiliations

¹ Guy's and St Thomas' NHS Foundation Trust, London, UK

² Department of Dermatology, Bispebjerg Hospital, Copenhagen, Denmark

³ Department of Clinical Medicine, University of Copenhagen, Copenhagen, Denmark

⁴ Rheumatology Department University Hospital and Fraunhofer Institute for Translational Medicine & Pharmacology ITMP, Fraunhofer Cluster of Excellence Immune-Mediated Diseases, Goethe University Frankfurt, Frankfurt am Main, Germany

⁵ Department of Dermatology, Venereology and Allergology, University Hospital Frankfurt, Frankfurt am Main, Germany

⁶ Dermatology and Medicine, Division of Rheumatology and Immunology, Brigham and Women's Hospital, Harvard Medical School, Boston, Massachusetts, USA

⁷ Eli Lilly and Company, Indianapolis, Indiana, USA

⁸ Department of Dermatology, Medical University of Vienna, Vienna, Austria

⁹ Department of Medicine, University of Queensland, Rheumatology Research Unit, Sunshine Coast, Queensland, Australia

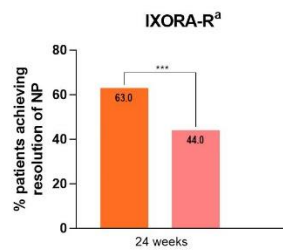
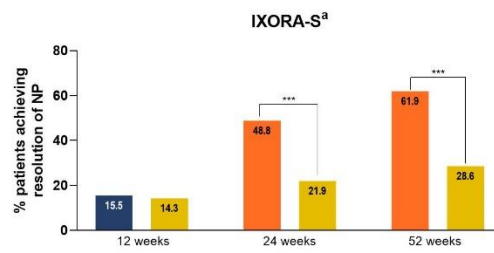
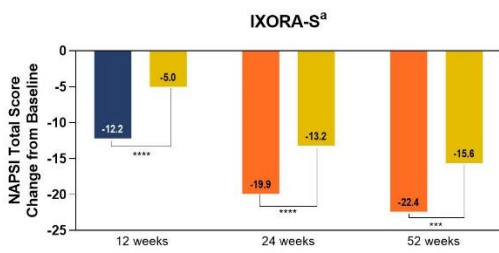
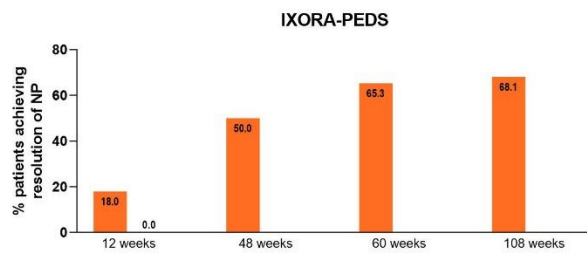
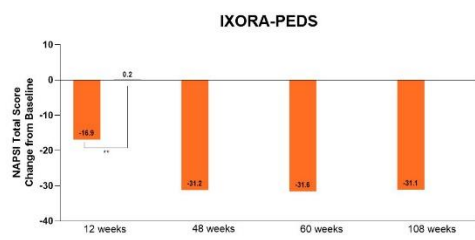
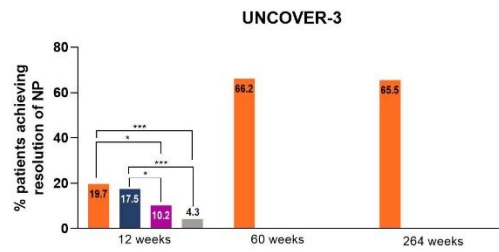
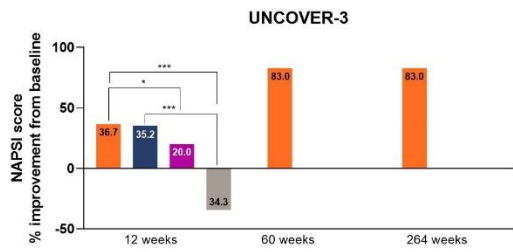
¹⁰ Department of Dermatology, Hospital de la Santa Creu i Sant Pau, Universitat Autònoma de Barcelona, Barcelona, Spain

Corresponding Author: Bruce W Kirkham (bruce.kirkham@gstt.nhs.uk)

Address: Guy's and St Thomas' NHS Foundation Trust, London, UK

Email: bruce.kirkham@gstt.nhs.uk

Supplemental Figure 1: Summary of nail psoriasis data across IXE trials in patients with PsO with concomitant nail psoriasis at baseline



■ IXE Q4W ■ IXE Q2W ■ UST
■ ETN ■ GUS ■ PBO

Supplemental Figure 2: Summary of nail psoriasis data across IXE trials in patients with PsA with concomitant nail psoriasis at baseline

