

Transfontanelle Photoacoustic Imaging of Intraventricular Brain Hemorrhages in Live Sheep

Juliana Bnevaides-Lara¹, Rayyan Manwar¹, Laura S McGuire², Md. Tarikul Islam¹, Anthony Shoo³, Fady T Charbel², Martha G Menchaca³, Amanda P Siegel¹, De-Ann M Pillers³, Juri Gelovani^{4,5,6}, Kamran Avanaki^{1,3,7,*}

¹ *Richard and Loan Hill Department of Bioengineering, University of Illinois at Chicago, Chicago, Illinois, United States*

² *Department of Neurological Surgery, University of Illinois at Chicago – College of Medicine, Chicago, Illinois, United States*

³ *Section of Neonatology, Department of Pediatrics, UIHealth Children’s Hospital of the University of Illinois at Chicago, Chicago, Illinois, United States*

⁴ *College of Medicine and Health Sciences, United Arab Emirates University, Al Ain, Abu Dhabi, UAE*

⁵ *Department of Biomedical Engineering, College of Engineering and School of Medicine, Wayne State University, Detroit, MI 48201, USA*

⁶ *Dept. Radiology, Siriraj Hospital, Mahidol University, Bangkok, 10700, Thailand*

⁷ *Department of Dermatology, University of Illinois at Chicago, Chicago, Illinois, United States*

***Corresponding Author: Kamran Avanaki**

Phone: +1 (312) 413-5528

E-mail: avanaki@uic.edu

Supplementary Material

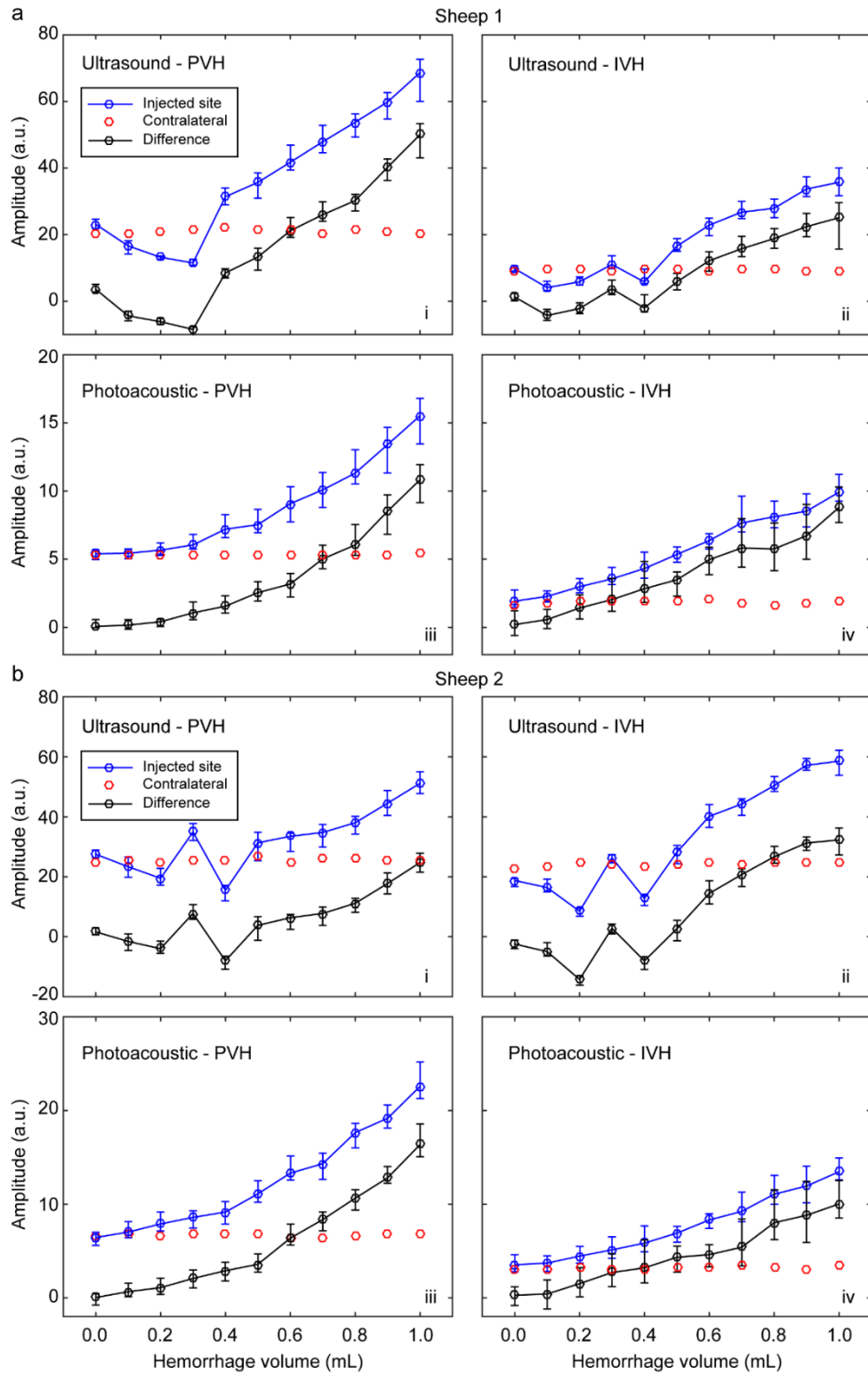


Figure S1. Pixel values of the injected ROI_i in Sheep #1 (a) and Sheep #2 (b) for different injection volumes are shown in blue (mean and range). Median results for contralateral region (ROI_c) are shown in red. Difference between ROI_i and median ROI_c are shown for the injection volumes in black (mean and range). Results are shown for ultrasound and photoacoustic analyses for both PVH and IVH models. ROI: region of interest; IVH: intraventricular hemorrhage; PVH: periventricular hemorrhage.