

NON-VEREAL LESIONS OF THE ANAL REGION*

BY

H. E. LOCKHART-MUMMERY

St. Thomas' and St. Mark's Hospitals, London

The subject of non-venereal lesions of the anus is such an extensive one that it would not be possible for me to cover this subject in the time available. I therefore propose to discuss some of the lesions of the anus and anal canal that lead to ulceration. It is these lesions that may be more difficult to distinguish from venereal conditions and are therefore more likely to be found in special clinics.

Speaking from the point of view of the rectal surgeon, I should start by reminding you that nearly every lesion around the anus is liable to be called "piles" by the patient and not infrequently by the referring doctor also. This word is likely to be used by the patient to cover almost all symptoms arising from the anal region and therefore nearly every lesion which may be seen in that situation. It is therefore important to go into the patient's history in rather more detail than the patient usually offers in order to find out the real symptoms from which he is suffering. This diagnosis is sometimes made by doctors also without adequate evidence, and it is perhaps worth noting again a remark by Hollings (1961) that few of the anal chancres which were found at St. Mark's Hospital had been correctly diagnosed by their referring practitioners.

Anal Fissure.—It is not proposed to discuss in detail the various manifestations of haemorrhoids, but I should like to devote some space to the anal fissure which is one of the most common conditions seen in any rectal clinic (Fig. 1). Nearly always these patients have a classical story of pain on and after bowel action; at times this may be very severe, and not infrequently there is some bleeding. However, in some of the anal fissures that we see, pain is not a marked feature, and in my experience it is particularly in young people with a fissure associated with

and probably due to chronic constipation that the condition tends to be relatively painless. Another frequent finding in cases of anal fissure is that the patient has had symptoms on and off for some years, frequently with attacks of pain that last a week or two, followed by long intervals of comfort. Most anal fissures are dorsal in position but a few are anterior; it is rare to see a lateral fissure unless there is some other associated lesion in the anal canal such as a fibrous polyp, prolapsing haemorrhoid, etc. The finding of a lateral fissure should therefore arouse clinical suspicion that the lesion may be something more than a simple fissure-in-ano. Often there is a little oedematous fold of skin at the distal periphery of the fissure, the so-called "sentinel tag," and in some of the more severe and chronic fissures this tag may be undermined with a little discharge of pus, either from the surface or from a fistulous opening at the edge of the tag itself. Careful inspection of the anal region with gentle eversion of the anal canal is the best way to diagnose an anal fissure. If digital examination is attempted before proper inspection the patient frequently experiences so much pain that intense spasm results and the fissure can never again be seen, and often they are impalpable anyway. However, inspection in a good light with gentle eversion of the anal canal will nearly always disclose a fissure, even in a nervous patient with intense spasm.

Tuberculous ulcers and fissures of the anal canal are now rare, as they are usually associated with open pulmonary tuberculosis. They are rather painful and often have an indolent dirty appearance which suggests their specific origin. More common nowadays in my experience is the anal lesion associated with Crohn's disease, of which Fig. 2 is a good example. It is not sufficiently known that Crohn's disease, particularly when it affects the large bowel, may result in extensive undermining

* Based on an address to the M.S.S.V.D., March 30, 1962.

ulceration of the anus and anal region, with considerable oedema and often deep destructive ulceration. Such extensive undermining ulceration with oedematous tags and a generally indolent appearance is nowadays practically characteristic of Crohn's disease in our experience. A biopsy will usually show the typical granulomatous histology, frequently with multinuclear giant cells. In recent years I have seen numerous lesions of this sort and it appears that this disease is on the increase. Many patients have extensive disease of the bowel with diarrhoea and weight loss and are frequently diagnosed as having ulcerative colitis. In fact, however, anal ulceration in ulcerative colitis is surprisingly uncommon, though in severe cases anal fissures may form and lead to a very sore anal region; however, such cases never show the oedema and undermining ulceration that one sees in Crohn's disease. I have also seen ulceration of this sort, though not to the same degree, in cases of severe diverticulitis of the colon when a lot of pus was passing into the rectum and being passed per anum. I have seen these ulcers heal after successful resection of the area of diverticulitis, and our experience with the ulcers of Crohn's disease also is that they cannot be induced to heal by diversion operations but only respond to excision of the diseased area of bowel.

Rather curiously, none of the ulcerating lesions of the anal region mentioned above seems to lead to clinical enlargement of glands in the groin. I find this a little difficult to understand, particularly in cases of Crohn's disease, for this disease within the abdomen nearly always leads to considerable enlargement of the regional lymph nodes. In my experience the only lesion that commonly leads to enlarged glands in the groin is the anal chancre, and as a rectal surgeon I have found this one of the most valuable guides to the diagnosis of these lesions when they appear in a rectal clinic, though I realize that groin gland enlargement is not an invariable sign in such cases.

Anal Pruritus.—This is one of the more common conditions in any rectal clinic and the skin changes vary very much from case to case. The peri-anal region may be moist and inflamed with superficial splits and fissures and sometimes little flat ulcers and excoriations, or the skin may be dry and scaly and either pale or reddened. In many cases the cause of anal pruritus is not known and does not become apparent but I am sure that in some of the cases that we see now the cause is some alteration of bacterial flora within the bowel or an overgrowth of yeasts, since many of them seem to start after a course of oral broad-spectrum antibiotics given for some in-

fection. Another potent cause of trouble is, I am sure, the local use of anaesthetic ointments which seem to have a particularly high index of sensitization and often lead to a quite severe acute dermatitis. In the more chronic cases gradual thickening of the skin may take place over some years and lead to a condition of leucoplakia (Fig. 3). The presence of leucoplakia in the peri-anal skin does not seem to have the same sinister significance that it has in certain other situations. Indeed my senior colleague, Mr. W. B. Gabriel, once told me that he had never seen a case of anal leucoplakia become malignant unless the patient had received radiation. I myself, however, have seen one case in which this change did occur without the patient's ever having received radiation but this certainly seems to be rare. However, if there is any doubt about an area of leucoplakia, or an indurated fissure in such an area, then biopsy should certainly be done or the whole area should be excised and submitted for careful microscopic section.

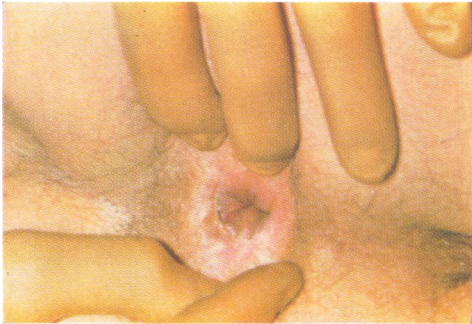
Anal Warts.—Of the protuberant lesions that one sees in the anal region I suppose the most common is the ordinary case of anal warts, and this varies from a few scattered warts around the anal region to a whole crop of them close together, resembling a sort of cauliflower lesion. These are frequently seen in a rectal clinic, whereas condylomata lata have been in my experience very rare indeed. We nearly always try to treat anal warts in the first instance with Podophyllin of 15 or 25 per cent. strength and most cases seem to respond very well.

Rodent Ulcer.—A rare lesion of the anus, illustrated in Fig. 4 is this rodent ulcer (basal cell carcinoma), which can be diagnosed with certainty only by biopsy. I have recently seen another lesion of this nature which clinically closely resembled an epithelioma but which was shown on biopsy to be a rodent ulcer. The distinction is important, as a purely local operation, preserving the sphincter mechanism intact, will almost certainly be perfectly adequate for the rodent ulcer, while it may not suffice for the more malignant epithelioma.

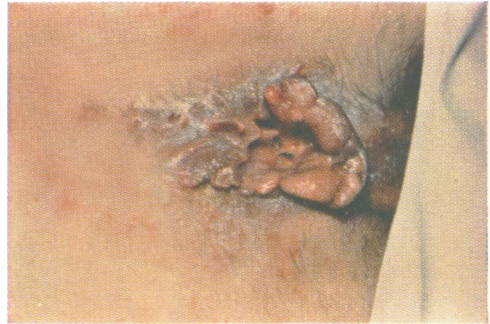Epithelioma.—These occur both in the anal canal and at the anal verge and vary from a small indurated fissure to a large protuberant mass which may fungate. The diagnosis of the large lesion is seldom in doubt and surprisingly these very large lesions often are not particularly invasive and provided that the sphincters have not been extensively involved may well be amenable to treatment by purely local surgery. More difficult are the small

NON-VENEREAL LESIONS OF THE ANAL REGION

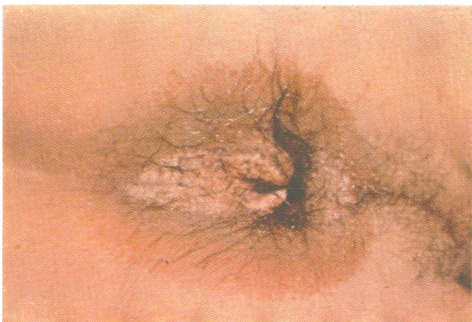1



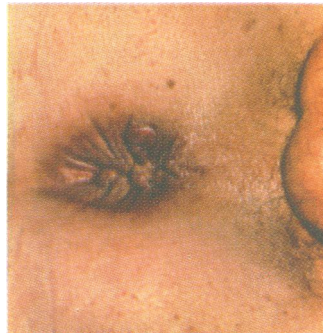2



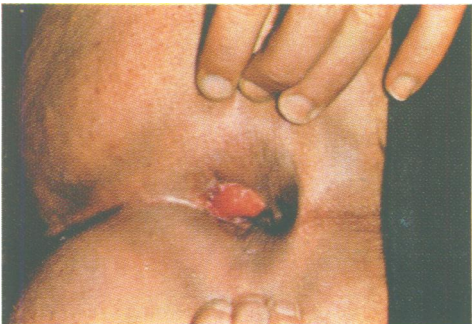3



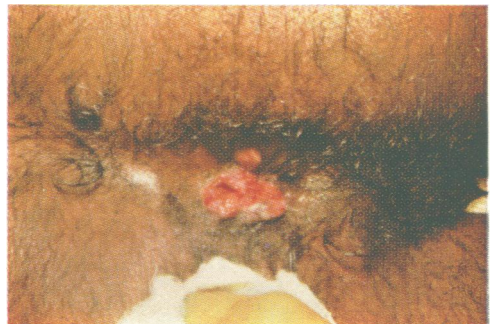4



5



6



ulcerating lesions of the anal canal, as these are liable to present with anal pain and a little bleeding and may well be diagnosed as simple fissures and treated conservatively for some time. The small lesions that arise in the anal canal are often of higher malignancy and of worse prognosis than the large protuberant lesions at the anal verge, and it is important to try to make an early diagnosis so that vigorous treatment can be given at an early stage. The lesion illustrated in Fig. 5 is a small and early epithelioma of the anal verge and this type of case can often be treated by local removal. However, a careful watch must be kept on the glands in the groin in every case of malignant disease around the anal canal.

Melanoma.—Another rare but dangerous lesion of this region is the malignant melanoma which is of particularly bad prognosis.

Behçet's Syndrome.—Another rather rare form of anal ulceration was recently seen by my colleague, Mr. Henry Thompson. The patient was a young girl who presented with small painful shallow ulcers at the anal verge; further examination showed that she had similar ulcers on the lips and on the tongue and the diagnosis of Behçet's syndrome was established. I do not recall seeing any such case myself and they do appear to be very rare.

Trauma.—Another rare form of anal ulceration occasionally seen is that due to self-inflicted trauma. This must be suspected in any case of a curious indolent ulcer at the anus, particularly if the patient is mentally defective, but the diagnosis is very difficult to prove and should only be suspected when all other possible causes have been excluded by investigation.

Donovaniasis.—Lastly, Fig. 6 shows a proliferating lesion of the anus that presented in my clinic a few weeks ago in a patient recently arrived from British Guiana. The lesion was proliferative and on inspection rather resembled an epithelioma but was quite soft. Smears and serological tests were negative and I therefore admitted the patient to hospital and excised the lesion for biopsy, but even this failed to give us a definite diagnosis. The possibility of granuloma venereum was then suggested to me by a venereologist, and further search of the biopsy material confirmed the presence of Donovan bodies and thus established the correct diagnosis. This patient has now been referred to a special centre for appropriate treatment.

REFERENCE

Hollings, R. M. (1961). *Proc. roy. Soc. Med.*, **54**, 730.