

GENITAL INFECTION IN ASSOCIATION WITH TRIC VIRUS INFECTION OF THE EYE

II. CYTOLOGY.* PRELIMINARY REPORT

BY

M. KHALAF AL-HUSSAINI AND BARRIE R. JONES

The Institute of Ophthalmology, London

AND

ERIC M. C. DUNLOP

Whitechapel Clinic, The London Hospital

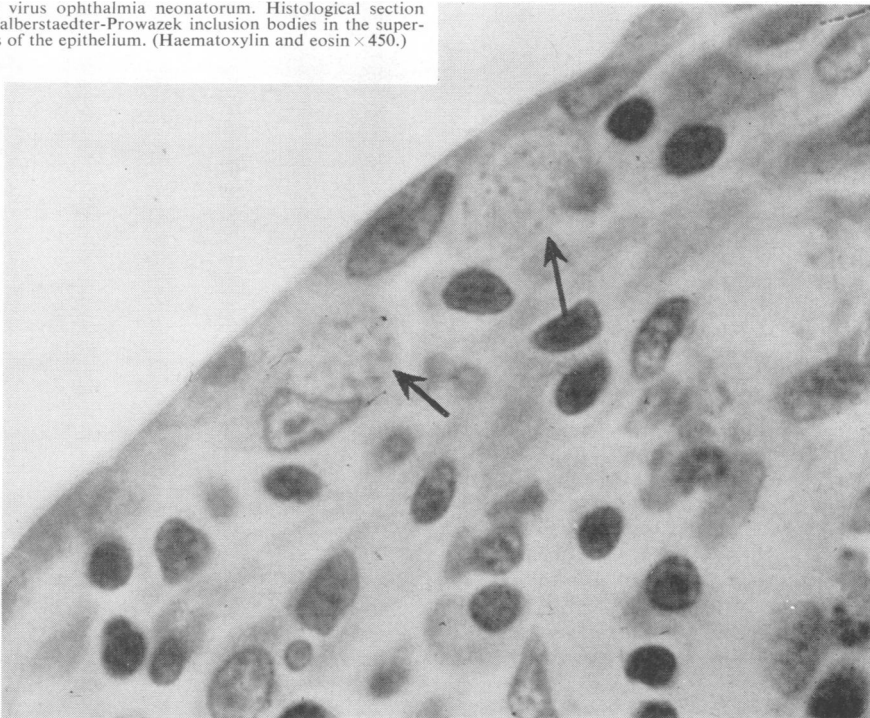
The aim of this investigation was to study the cellular changes occurring in TRIC virus infection of the genital tract, and to compare them with the changes occurring in infection of the eye by this agent.

* Read at the Meeting of the M.S.S.V.D. in Copenhagen, June 7, 1963.

Method

Scrapings of the epithelium of urethra and cervix were taken gently (Dunlop, Jones and Al-Hussaini, 1964). Only gentle scraping is required because the inclusion bodies occur in the superficial layers of the epithelium, as can be seen in the section of the conjunctiva shown in Fig. 1.

FIG. 1.—TRIC virus ophthalmia neonatorum. Histological section showing Halberstaedter-Prowazek inclusion bodies in the superficial layers of the epithelium. (Haematoxylin and eosin $\times 450$.)



After smears had been made on slides and dried, they were fixed in methyl alcohol, and stained by Giemsa's method. Macchiavello's and Castañeda's stains, whilst satisfactory for demonstrating inclusion bodies, do not reveal the cellular pattern. Iodine staining (Rice, 1936; Gilkes, Smith, and Sowa, 1958), which is invaluable for the rapid demonstration of inclusions in conjunctival scrapings (Fig. 2*a*), cannot be used on genital material, because many cells, in the urethral and cervical epithelium contain glycogen and therefore stain so intensely with iodine (Jones, Collier, and Smith, 1959) that the recognition of inclusions is impossible (Fig. 2*b*).

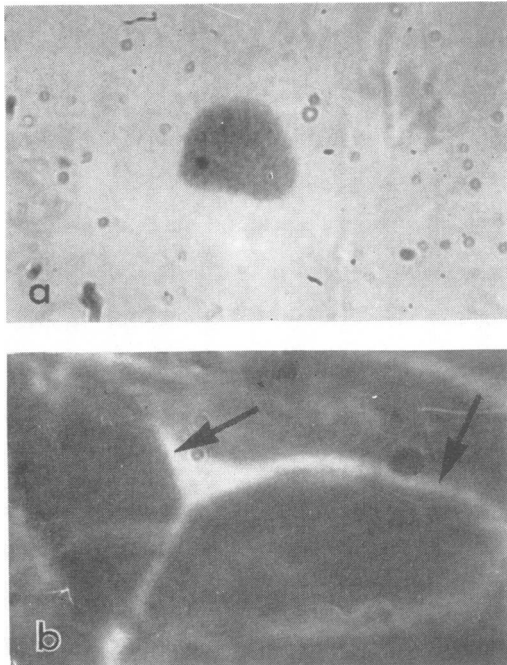


FIG. 2.—(a) Conjunctival scrapings stained with iodine, showing carbohydrate matrix of inclusion body ($\times 1,000$).
(b) Cervical scrapings stained with iodine, showing staining of cytoplasm of epithelial cells ($\times 1,000$).

TYPES OF CELL FOUND

(A) Epithelial Cells

(1) *Normal Epithelial Cells*.—Normal urethral epithelial cells (Fig. 3*b*) resemble conjunctival epithelial cells (Fig. 3*a*) very closely. Each has a round nucleus 10 to 12 μ in diameter. The purple-staining chromatin has a regular, finely granular pattern. The cytoplasm is faintly blue and slightly granular in appearance; the cell is usually between 20 and 25 μ in diameter.

Two types of normal epithelial cells are commonly seen in cervical scrapings: transitional cells (Fig. 3*c*), which are very similar to conjunctival epithelial cells, and squamous epithelial cells which may become keratinized (Fig. 3*d*).

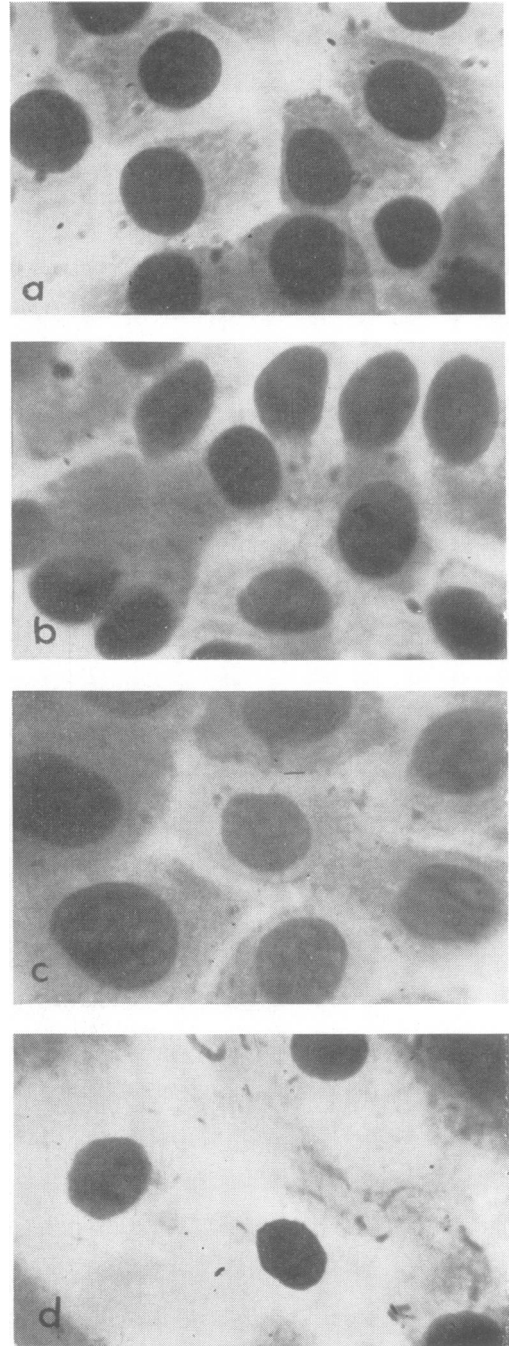


FIG. 3.—Normal epithelial cells (Giemsa $\times 1,000$).

- (a) Conjunctiva.
- (b) Urethra.
- (c) Cervix, transitional cells.
- (d) Cervix, keratinized squamous cells.

The latter are large cells with small, dense blue nuclei which become more purple as they age; the abundant cytoplasm may be pale blue or colourless and often contains some purple keratin granules; virus inclusion bodies are not found in these cells (Thygeson and Stone, 1942).

(2) *Abnormal Epithelial Cells.*—As a result of local TRIC virus infection, many of the epithelial cells of the cervix, urethra, and conjunctiva show characteristic toxic or degenerative changes (Fig. 4). The cells become enlarged up to $30\ \mu$ in diameter. The nucleus becomes swollen, commonly reaching $15\ \mu$ in diameter, but the cytoplasm becomes vacuolated as the process continues, and then disintegrates so that

swollen nuclei are left bare. In the early stages, the nuclear chromatin loses its uniformly fine granular appearance. Its affinity for dyes lessens so that it appears blurred and pale. Spaces develop between the pale chromatin masses and enlarge to form multiple vacuoles or ramifying clefts. The nucleoli also become swollen and paler. The enlarged nucleus with its expanded chromatin pattern often elongates and becomes indented or kidney-shaped, so that the cell may easily be confused with a monocyte, especially as some of them are phagocytic. Epithelial cells, can however, be identified by the presence of nucleoli. These progressive changes, with loss of cytoplasm, lead to the appearance of many pale, swollen, and blurred nuclear ghosts.

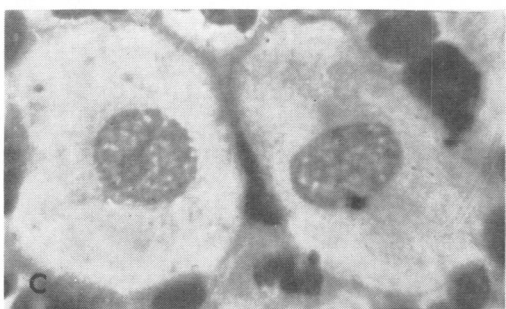
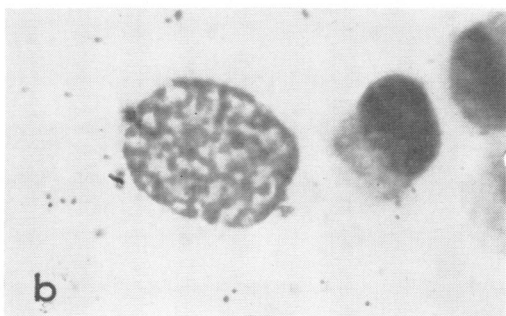
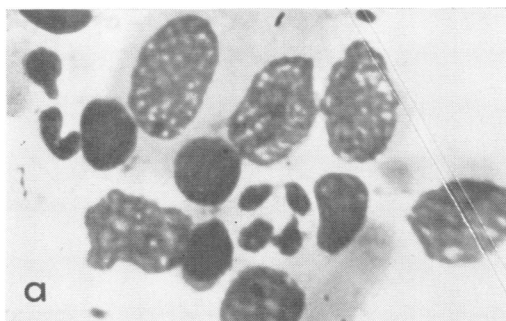


FIG. 4.—Epithelial cells showing degenerative changes (Giemsa $\times 1,000$).
(a) Conjunctiva. (b) Urethra. (c) Cervix.

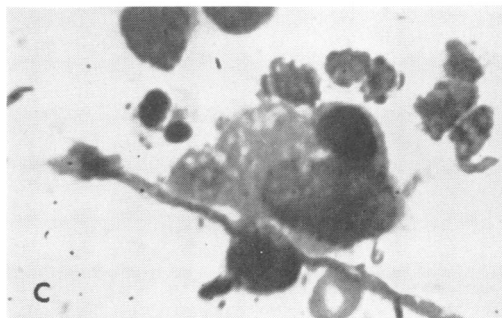
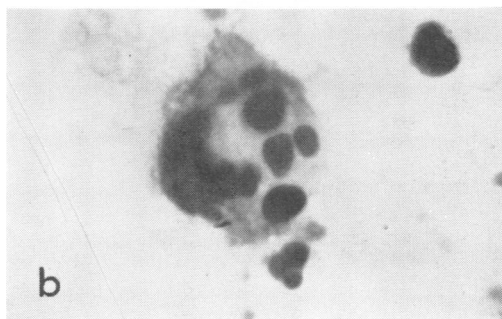
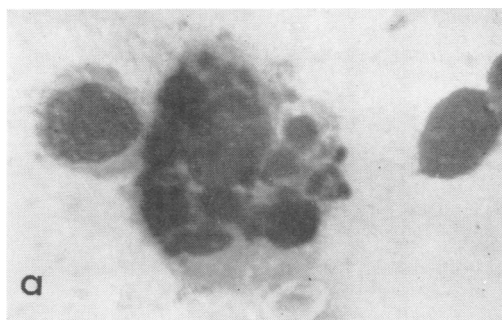
FIG. 5.—Phagocytic cells (Giemsa $\times 1,000$).
(a) Conjunctiva. (b) Urethra. (c) Cervix.

(3) *Phagocytic Epithelial Cells*.—Phagocytic cells similar to the Leber cells of trachoma (Duke-Elder, 1938) are found in most of the scrapings from both urethra and cervix when these sites are infected by TRIC virus (Fig. 5, previous page). Their nuclear pattern and the presence of nucleoli frequently indicate an epithelial origin.

(4) *Epithelial Cells with Inclusions*.—The developmental cycle of Halberstaedter-Prowazek inclusion

bodies (Halberstaedter and Prowazek, 1907) starts with the entry of an elementary body (0.25 to 0.5μ in diameter) into an epithelial cell. The particle swells to become a relatively large blue-staining initial body (0.3 to 1.5μ in diameter) which then divides successively to form a cluster of smaller initial bodies (Fig. 6*a*). This cluster is referred to as a round basophil inclusion body (Fig. 6*b*). As the inclusion enlarges, increasing numbers of purple-staining elementary bodies appear within it (Fig. 6*c*).

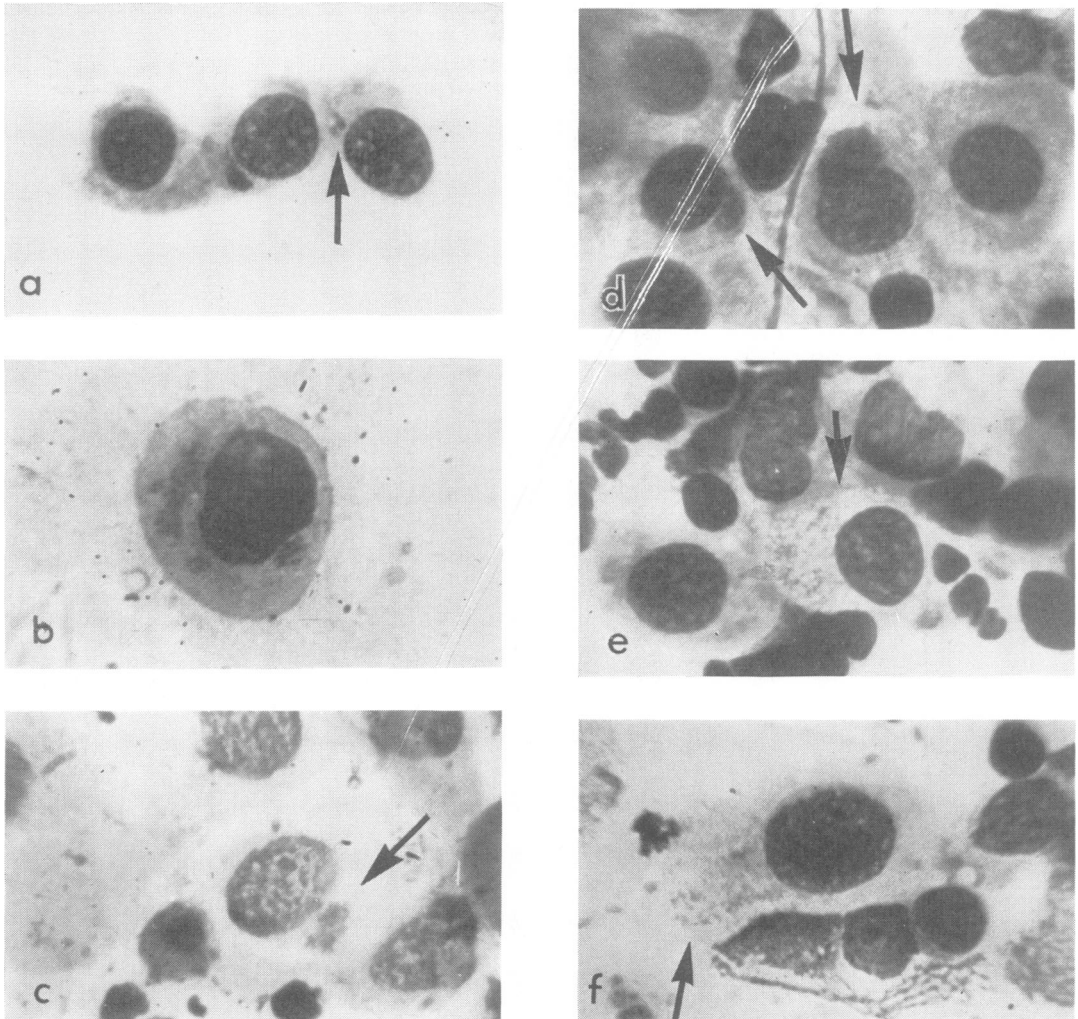


FIG. 6.—Stages in development of TRIC virus inclusion bodies (Giemsa $\times 1,000$).

- (a) Initial bodies (arrow) and a small basophil inclusion body in the adjacent cell (conjunctiva of Baby D).
 (b) Multiple basophil inclusions; two small round inclusions, one cap-shaped inclusion indenting the nucleus, and one larger inclusion body of irregular shape (cervix of Mrs D).
 (c) Inclusion body in urethral cell from Mr C (arrow).

- (d) Crescentic inclusion bodies forming caps to the nuclei (conjunctiva).
 (e) Mature eosinophil inclusion body (conjunctiva).
 (f) Ruptured epithelial cell liberating free elementary bodies (conjunctiva).

At this stage, the inclusion body is often crescent-shaped and forms a cap on the nucleus (Fig. 6*d*). The mature inclusion (Fig. 6*e*) fills the cytoplasm and ruptures, liberating free elementary bodies (Fig. 6*f*) to repeat the cycle in other cells.

In differentiating inclusions from other structures it should be realized that more than one inclusion body may be found in a single cell (Figs. 6*b* and 7). In conjunctival scrapings, the demonstration by iodine-staining of glycogen in the matrix of the inclusion leaves no doubt about its nature (Fig. 7*a*). This is not practicable with genital scrapings, but

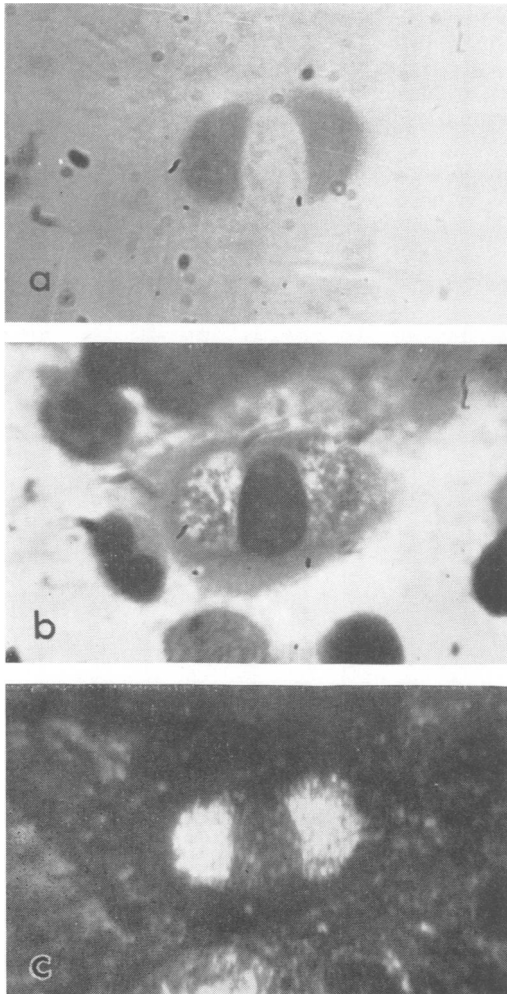


FIG. 7.—Conjunctival epithelial cell from Mr L, with two Halberstaedter-Prowazek inclusion bodies ($\times 1,000$).

- (a) Stained with iodine.
- (b) Same field decolourised and stained with Giemsa.
- (c) Same field stained with Giemsa as seen with dark-ground illumination.

examination of the Giemsa-stained scrapings by dark-ground illumination reveals a striking golden fluorescence of the virus particles within the inclusion body (Figs 7*c* and 8*b*).

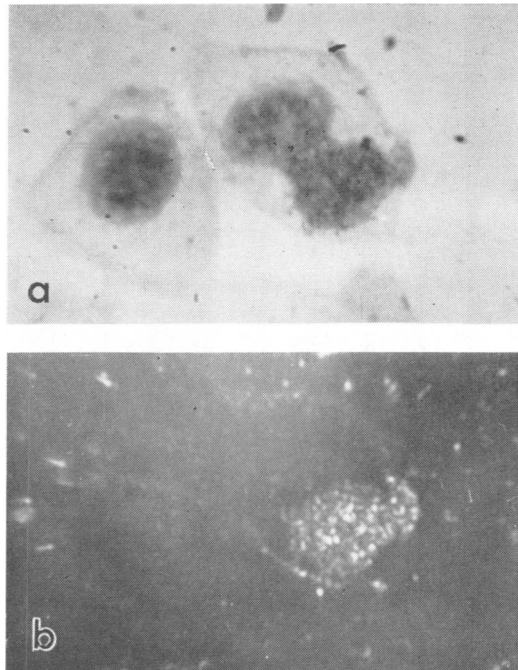


FIG. 8.—Cervical epithelial cell from Mrs D showing an inclusion body (Giemsa $\times 1,000$).

- (a) Ordinary illumination.
- (b) Dark-ground illumination

A nuclear protrusion (Fig. 9*a*, overleaf) can be identified because the colour and pattern of the extruded material are identical with those of nuclear chromatin. Furthermore, a break in the nuclear membrane can sometimes be seen.

Occasionally a deep blue-staining granulation of the cytoplasm occurs (Fig. 9*b*). This may assume a shape resembling that of an inclusion body, but the remaining cytoplasm often shows similar granulation. This "psuedo-inclusion" is a pure blue, unlike initial bodies which are navy blue and elementary bodies which are purple; furthermore, it is not composed of the sharply-defined particles which constitute the virus inclusion.

The cytoplasm of cervical epithelial cells sometimes has a pink granulation which is probably due to keratin (Fig. 9*c*). The granules, which are scattered throughout the cytoplasm, are irregular in shape and size and are often larger than elementary bodies.

Bacterial aggregates (Fig. 9*d*) sometimes occur in or on the cytoplasm of urethral or cervical cells. The

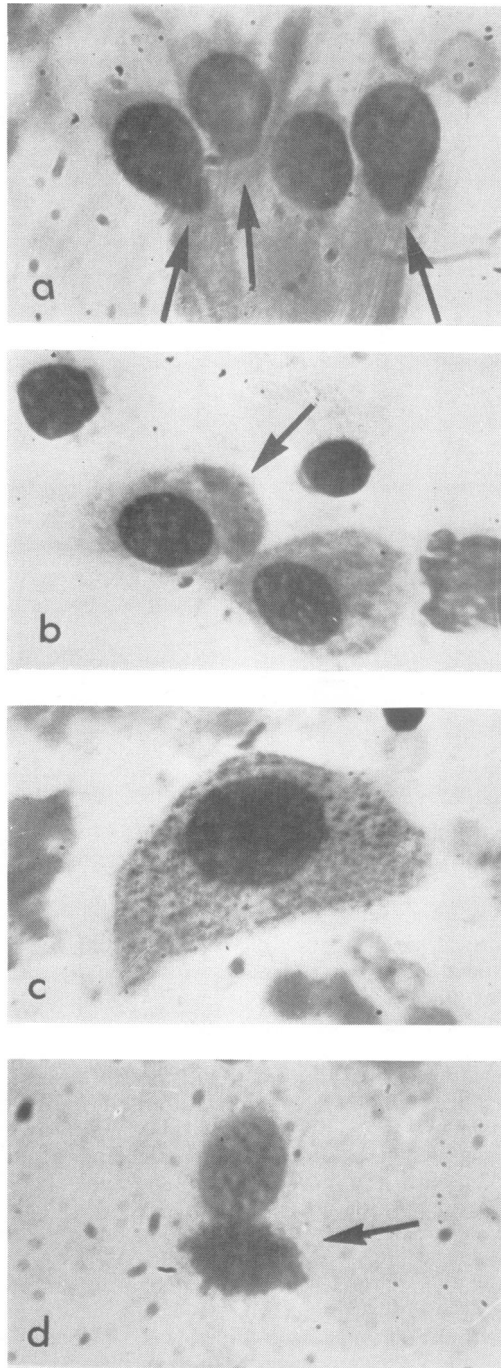


FIG. 9.—Pseudo-inclusions (Giemsa $\times 1,000$).
 (a) Nuclear protrusion (conjunctiva).
 (b) Granular cytoplasm (conjunctiva).
 (c) Keratin granules (cervix).
 (d) Bacterial aggregate (urethra).

individual particles are larger in size and more blue-staining than those of virus inclusions. Similar aggregates may be found outside the cell and they do not fluoresce like TRIC virus elementary bodies when examined by dark-ground illumination.

(B) Inflammatory Cells

Neutrophil polymorphonuclear leucocytes are constantly present in the inflammatory response to TRIC virus infection of the eye. They are the predominant cells in the early stages and continue to be found so long as virus persists. They were present also in all the genital scrapings in which the characteristic degenerative changes were recognized in epithelial cells. An occasional eosinophil may be seen in these scrapings from both eye and genital tract. Lymphocytes are numerous, plasma cells and large primitive mononuclear cells are less commonly seen. As noted above, phagocytic cells occur in these scrapings (Fig. 5*b* and *c*); they usually appear to be epithelial cells, rather than monocytes or tissue macrophages.

Discussion

In TRIC virus infection of the eye, the diagnostic features in descending order of sensitivity are:

- (1) Characteristic clinical findings.
- (2) Characteristic cellular changes in scrapings.
- (3) Presence of inclusions.
- (4) Isolation of virus.

The precise significance of a positive complement-fixation test with the psittacosis-lymphogranuloma-TRIC virus (PLT) group antigen and that of intradermal tests remain to be assessed in relation to TRIC virus infections (Dunlop and others, 1964).

Clinical examination by an experienced observer will frequently establish an unequivocal diagnosis of one or other of the TRIC virus syndromes. Sometimes the findings are equivocal. Cellular changes consistent with a clinical diagnosis of TRIC virus infection, but without virus inclusions, make the diagnosis likely but do not prove it. The finding of inclusions or the isolation of virus leaves no doubt, but this proof becomes increasingly difficult to obtain with the passage of time after infection.

For all the patients presenting with eye disease, with the exception of one who had already received treatment (Mrs O), an unequivocal diagnosis of ocular TRIC virus infection was established by finding inclusions in conjunctival scrapings.

In conjunctival scrapings the finding of many epithelial cells which show the typical sequence of "toxic" or degenerative changes, together with a mixed inflammatory exudate of polymorphs, lymphocytes, occasional plasma cells, large mono-

nuclears, and phagocytic cells, is compatible with a diagnosis of TRIC virus infection. If the changes are pronounced, they suggest this diagnosis. It seems likely that these findings have a similar significance when observed in genital scrapings. However, the only cytological proof of TRIC virus infection is the finding of Halberstaedter-Prowazek inclusion bodies. It may reasonably be assumed that the mothers (Mrs D, E, I, C, H) of the five babies suffering from neonatal TRIC virus ophthalmia had TRIC virus infection of the genital tract, sufficiently active to infect the babies at birth. In all five cases (Table I), the cellular changes in the cervical scrapings were consistent with a diagnosis of TRIC virus cervicitis; in one (Mrs D) inclusions were found in the scrapings and virus (IOL-4/GCx) was isolated from them (Jones, Al-Hussaini, and Dunlop, 1964). Similarly, the cellular changes in the urethral scrapings were consistent with a diagnosis of TRIC virus urethritis in all three of the fathers examined; inclusions were found in urethral scrapings from all of them and virus (IOL-9/GU) was isolated from the urethra of Mr H (Table I). Had these parents been examined earlier in the course of their genital infections, it is likely that inclusions would have been found (Lindner, 1910) and virus isolated from a higher proportion.

In the case of eight adult patients suffering from

TRIC virus infection of the eye and four of their consorts, no inclusions were found in genital scrapings, nor was virus isolated from them (Table II). However, cellular changes consistent with the diagnosis of TRIC virus infection of the genital tract were present in nine of the patients tested. These changes, the clinical findings, and the serological results (Dunlop and others, 1964) suggest that genital TRIC virus infection was present in some cases at least. Further work in progress confirms this association.

Although, under ideal conditions, the finding of inclusions is easier than isolation of virus, it is still a procedure that is practicable only in a research study. It demands the expenditure of a great deal of time by a trained observer; even then, failure to find inclusions does not exclude the diagnosis. If inadequately-trained observers are employed, if hurried examinations are made, or if the method of collection of material is inadequate, the results will almost certainly be negative. We are investigating and comparing the relative sensitivity of immunofluorescent techniques. Although there are considerable difficulties, it is possible that a fluorescent-antibody method may ultimately provide the best diagnostic procedure for TRIC virus infection of the genital tract (Nichols, McComb, Haddad, and Murray, 1963).

TABLE I
CYTOLOGICAL FINDINGS IN GENITAL SCRAPINGS FROM EIGHT PARENTS OF FIVE BABIES WITH TRIC VIRUS OPHTHALMIA NEONATORUM

Parents	No. of Parents	Cytology Compatible with TRIC Virus Infection	No. with Inclusions	No. of Virus Isolates
Mothers	5 (D, E, I, C, H)	5	1 (Mrs D)	1 (Mrs D)
Fathers	3 (D, C, H)	3	3 (Mr D, C, H)	1 (Mr H)

TABLE II
CYTOLOGICAL FINDINGS IN GENITAL SCRAPINGS FROM EIGHT ADULT PATIENTS WITH TRIC VIRUS EYE INFECTION AND FOUR OF THEIR CONSORTS

Ocular Syndrome	Number of Cases	Cytology Compatible with TRIC Virus Infection	No. with Inclusions	No. of Virus Isolates
Inclusion Conjunctivitis	3 patients + 2 consorts	3	0	0
Punctate Kerato-conjunctivitis	2 patients + 1 consort	3	0	0
Trachoma	3 patients + 1 consort	3	0	0
Total	12	9	0	0

Summary

The findings in scrapings from the genital tract affected by TRIC virus are described and compared with those in scrapings from the conjunctiva in TRIC virus infection of the eye. The changes were identical. The methods for demonstrating TRIC virus inclusions are discussed and the differential diagnosis of these inclusions is considered.

A typical picture of degenerative cellular changes and inflammatory exudate was found in cervical scrapings from the mothers of five babies suffering from TRIC virus neonatal conjunctivitis. In one mother TRIC virus was isolated from cervical scrapings and inclusions were present. The same cellular changes were present in urethral scrapings from the three fathers who were examined; all were found to have "non-specific" urethritis. Inclusions were present in the urethral scrapings obtained from all three and TRIC virus was isolated from one.

Scrapings from the genital tract were also examined in the case of eight adults suffering from TRIC virus infection of the eye, and four of their consorts. The characteristic cellular changes suggesting TRIC virus infection were found in nine of the twelve subjects; although inclusions were not found and virus was not isolated, it seems likely that at least some of these patients had genital infection with TRIC virus.

REFERENCES

- Duke-Elder, S. (1938). "Text-book of Ophthalmology", vol. 3, p. 1519. Kimpton, London.
- Dunlop, E. M. C., Jones, B. R., and Al-Hussaini, M. K. (1964). *Brit. J. vener. Dis.*, **40**, 33.
- Gilkes, M. J., Smith C. H., and Sowa, J. (1958). *Brit. J. Ophthal.*, **42**, 473.
- Halberstaedter, L., and von Prowazek, S. (1907). *Arb. Gesundheits.-Amte (Berl.)*, **26**, 44.
- Jones, B. R., Al-Hussaini, M. K., and Dunlop, E. M. C. (1964). *Brit. J. vener. Dis.*, **40**, 19.
- , Collier, L. H., and Smith, C. H. (1959). *Lancet*, **1**, 902.
- Lindner, K. (1910). *Wien. klin. Wschr.*, **23**, 283.
- Nichols, R. L., McComb, O. E., Haddad, N., and Murray, E. S. (1963). *Amer. J. trop. Med.*, **12**, 233.
- Rice, C. E. (1936). *Amer. J. Ophthal.*, **19**, 1.
- Thygeson, P., and Stone, W. (1942). *Arch. Ophthal. (Chicago)*, **27**, 91.

Infection génitale avec infection oculaire due au virus TRIC

II. Cytologie

RÉSUMÉ

On décrit les frottis génitaux de malades infectés par le virus TRIC et on les compare aux frottis conjonctivaux de malades atteints d'infection oculaire par le virus TRIC. On discute la démonstration des inclusions du virus TRIC et le diagnostic différentiel.

On trouva une dégénération cellulaire à exudat inflammatoire dans les frottis du col de l'utérus chez les mères de 5 enfants atteints de conjonctivite néonatale due au virus TRIC. On isola ce virus des frottis du col de l'utérus d'une des mères, et on y trouva des inclusions. La même dégénération fut présente dans les frottis urétraux de 3 pères examinés; tous étaient atteints d'urétrite non-spécifique. On trouva des inclusions dans les frottis de tous les trois et on isola le virus TRIC d'un père.

On examina les frottis génitaux de 8 adultes atteints de virus TRIC oculaire et de 4 de leurs partenaires sexuels. On trouva la dégénération classique de l'infection par le virus TRIC dans 9 cas sur 12; on ne trouva pas d'inclusions et on n'isola pas de virus, mais il se peut que quelques malades fussent atteints d'infection génitale due au virus TRIC.