

HERPES GENITALIS*†‡

BY

DAVID C. HUTFIELD

Department of Venereal Diseases, The Royal Infirmary, Manchester

Herpes genitalis is commonly seen in departments for venereal diseases, but venereologists have recorded little about its clinical aspects and treatment (Hutfield, 1963a). Slavin and Gavett (1946) stated that herpes genitalis is essentially a venereal disease, but the condition has attracted little attention in recent years. Duxbury and Lawrence (1959) suggested that this might be due to the fact that, since 10 per cent. of the population have been reported to be without neutralizing antibodies to the herpes virus, then only this proportion will be subject to contagion, so that relatively few cases will be seen to act as a basis for reports in the literature. De Glanville (1963) stressed the need for the publication of more information, since it was seldom mentioned in articles or textbooks on venereal disease and could so easily be confused with chancroid. It is curious that more attention has not been paid to this disease recently, since in the department of venereal diseases at St. Mary's Hospital, which has the largest attendance of new cases per annum of all clinics in the United Kingdom, as many as five to six cases are seen for every one of primary syphilis (Hutfield, 1963b). One reason is that a curative treatment is available for patients with primary syphilis, whereas there is none for patients with herpes genitalis, who form a larger residue. Another reason is that because 81 per cent. of patients with venereal diseases have been found to possess neutralizing antibodies, the majority of herpes cases are probably due to recurrent attacks since only 19 per cent. of patients are prone to primary infection (Hutfield, Wasley, and Gray, 1967). However, it is of considerable importance that herpes should be differentiated from syphilis, because the lesions

in the ulcerative stage are similar and in some cases identical.

Clinical Features

Herpes simplex infection manifests itself clinically in two main groups, primary and recurrent infections. The commonest primary illness is gingivostomatitis. Occasionally it presents as keratoconjunctivitis with dendritic ulceration. It may also present as a skin lesion, a whitlow or as an eczema herpeticum, otherwise known as Kaposi's varicelliform eruption, or more rarely meningoencephalitis, or in neonatal infections as generalized visceral disease. It may also present as a genital infection. The majority of primary infections usually occur in infancy and early childhood. Recurrent attacks may occur at irregular intervals for months or years throughout life and usually in response to various non-specific "trigger" mechanisms such as a febrile illness, toxæmia, menstruation, anxiety states, injury, exposure to sunlight or cold, gastrointestinal upset, prolonged cortisone treatment, and pre-ganglionic section of sensory nerves.

In the eruptive phase herpes simplex appears as grouped vesicles or as large bullae on an inflamed base, the sites of predilection being the skin and mucous membranes or mucocutaneous junctions. The eruption is usually preceded by local irritation or pain and once the vesicles have formed they soon rupture to form ulcers, which persist for several days and then heal spontaneously. The ulcers may, however, become secondarily infected, particularly in children who may develop a secondary impetigo which can mask the herpetic nature of the eruption and prolong its course.

In primary infections the lesions are usually more scattered than in recurrent attacks, in which they tend to be more closely arranged in groups. This pattern associated with recurrent attacks is probably

*Part of a thesis accepted for the M.D. degree of the University of London.

†Received for publication February 22, 1968.

‡Address for reprints: 7 Clysbarnton Court, Bramhall Park Road, Bramhall, Cheshire.

due to migration of virus particles along axons of nerve terminals that supply a small segment of skin or mucous membrane. Infected areas of skin are, however, apparently normal between attacks and little scarring occurs.

The eruption of herpes genitalis is similar to that occurring in other parts of the body and manifests itself clinically as a primary or recurrent infection.

In the male, the lesions usually appear on the glans penis, prepuce, or balano-preputial sulcus. They may occur on the shaft of the penis and rarely on the scrotum or thigh (Fig. 1). The urethra or bladder may also be involved, giving rise to a urethritis (Harkness, 1950) or a cystitis (Schiffmann, 1926) respectively.

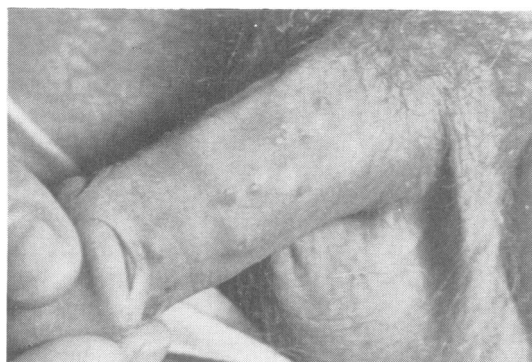

FIG. 1.—Vesicular eruption of herpes genitalis on the glans and shaft of the penis.

In the female, the lesions appear on the hood of the clitoris, labia minora, labia majora, introitus vaginae, vagina, cervix, perineum, and cruro-genital fold, and may occasionally extend to the buttocks and thighs (Fig. 2).

The perianal region, anus, and anal canal may be involved in both males and females, and in the former may be the result of homosexual contact (Hutfield, 1963a). The eruptive phase is usually preceded by irritation, burning, or pain. This is followed by the appearance of one or several groups of vesicles arising from an inflamed base; if the lesions are multiple they may coalesce to form bullae, which are more common in females. The vesicles soon rupture to form soft non-indurated ulcers, but secondary infection of these may lead to balanoposthitis in the male or vulvo-vaginitis in the female. Secondary infection may also result in persistence of irritation, burning, or pain until the lesions have healed. It is not usual, however, for herpes ulcers to become infected with secondary organisms until they have persisted for at least 5 days. Once infected the ulcers discharge pus or blood and eventually dry and become crust-coated. In the course of a few days, the crusts fall off and the underlying tissue heals. Successive crops, however, may prolong the disease for several weeks. Tender enlargement of the regional lymph glands may occur, especially in the presence of secondary infection, which is probably more common in the genital region than in other parts of the body owing

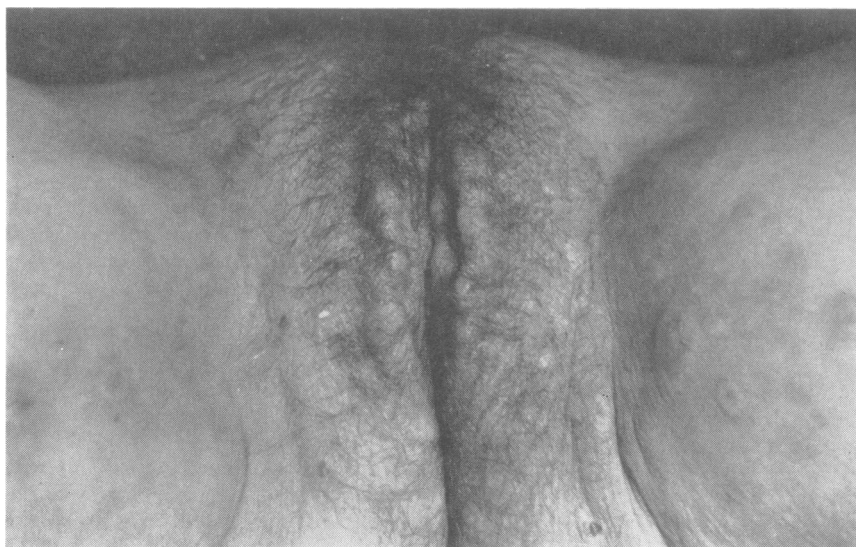

FIG. 2.—Symmetrical distribution of ulcerated lesions of herpes genitalis on the vulva extending into the groins and on to the thighs.

to contamination with infected discharges that are found more frequently in patients with venereal diseases.

Once acquired, the disorder tends to be recurrent and often breaks out with each successive intercourse as a result of reactivation of virus latent in cells at or near the site of primary infection. This may be related to the trauma of intercourse, or may possibly have a psychosomatic basis, since there is often an associated syphilophobia (Hutfield, 1963a). The eruption will also appear in response to other stimuli, such as local irritation associated with a genital discharge and menstruation. Recurrent attacks can be diagnosed from the history, except in those cases in which a previous infection may have been subclinical and passed unnoticed. Recurrent infections are less severe than primary infections and the lesions are usually more closely arranged in groups.

Clinical Manifestations of Herpes Genitalis

(1) Balanoposthitis

This is of fairly common occurrence in the uncircumcised male and often the patient presents himself primarily with a purulent discharge due to secondary infection. It is not until the prepuce is retracted that the lesions of herpes are revealed (Fig. 3).

(2) Vulvo-vaginitis

This usually presents as a vaginal discharge and may be due to secondary infection of herpetic lesions which are to be found on the vulva, vaginal wall, and occasionally the cervix (Rollet, 1869). In some cases, herpetic bullae appear on the vulva, while in others the disease extends to the perineum, anus, anal canal, buttocks, and thighs. Herpetic vulvo-vaginitis can be an extremely painful condition simulating the neuralgic form described by Mauriac (1876).

Slavin and Gavett (1946) were the first to report cases of vulvo-vaginitis with laboratory evidence of causation by herpes simplex virus. They described three women who presented with superficial erosions on the labia minora, the labia majora, and vaginal mucosa. Some of the ulcers were paired and it was thought this was due to autoinoculation. The presence of virus was demonstrated by inoculation of the rabbit cornea with material from the ulcers, resulting in the development of keratitis. These were probably cases of primary infection, since a rise in antibody titre occurred in each case. The husband of one of the patients gave a history of recurrent genital herpes, and at the time of exami-

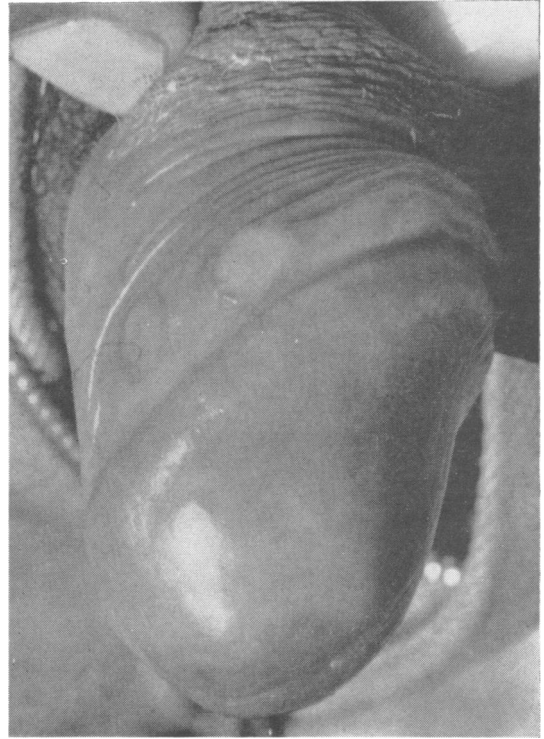


FIG. 3.—Herpes ulcers in balano-preputial sulcus with prepuce retracted.

nation was found to have a penile sore. This was associated with an unvarying antibody level.

Lazar (1955) described three cases of primary herpetic vulvo-vaginitis, two being in women aged 22 and 23 years respectively and the third in a 4-year-old girl. The presence of virus was demonstrated by inoculation of scarified rabbit cornea with material from fresh vulvo-vaginal lesions; intranuclear inclusion bodies were demonstrable in the keratitic lesions after 72 hours. A 10 per cent. aqueous suspension of the nictitating membrane from these animals was inoculated on to the chorio-allantoic membrane of chick embryos, and herpes pocks appeared after 48 hours.

Brain (1956) described acute herpetic vulvo-vaginitis in infant girls, and stated that isolated vesicles or small groups of vesicles which sometimes became confluent were to be found on the inflamed and oedematous vulva. The labia were often stuck together by a viscid serous discharge and herpetic lesions were usually present on the labia minora and lower part of the vaginal wall. He thought that napkin rashes in infants could act as a portal of entry for the virus, as also might wounds, burns, or abrasions.

(3) Urethritis

The patient may present with urethral discharge and burning on micturition. Herpetic urethritis is undoubtedly one of the many causes of non-gonococcal urethritis. Diday and Doyon (1876) were the earliest to describe urethritis resulting from endo-urethral herpes; the lesions may or may not be accompanied by lesions elsewhere on the genitalia. There is usually severe burning on micturition but only a slight mucoid discharge. Urethral smears show a large number of epithelial cells with only a few polymorphonuclear leucocytes, and bacterial cultures are usually sterile. There may be an associated swelling of the dorsal lymphatics of the penis and a slight tender inguinal adenopathy (Harkness, 1950). Cases of endo-urethral herpes, occurring alone or in association with lesions of the genitalia, with scattered vesicles and ulcers visible on urethroscopy, have been reported by Bettman (1902) and Klotz (1914). Nicolas, Gaté, and Papacostas (1923) described six cases in detail; in all, cure of the urethritis coincided with the disappearance of the skin lesions. Coutts (1948) described two cases of urethritis due to herpes virus in which endo-urethral lesions accompanied others on the lips of an oedematous meatus, and were thought to have been contracted as a result of buccal coitus since the virus has been demonstrated in the mouths of healthy persons. Esteves and Pinto (1952) described a case of herpetic urethritis of sexual origin in a 27-year-old man who presented with bacterial urethritis which had persisted in a recurrent form for 2 months and which had not responded to chemotherapy or antibiotics. Typical painful lesions appeared near the urethral meatus and the virus was isolated from them by chick-embryo inoculation. Eventually the condition cleared spontaneously and did not relapse.

Nasemann and Nagai (1960) described three cases of intra-urethral herpes, confirmed virologically by chick-embryo inoculation with urethral secretion. Lesions were present on the glans penis and floor of the meatus. Giemsa-stained urethral smears demonstrated intranuclear eosinophilic inclusion bodies and multinucleate epithelial giant cells.

(4) Cystitis

Herpetic cystitis is a rare condition but two cases have been reported. Patients present with increased frequency, difficulty or burning on micturition, haematuria, abdominal pain and, on some occasions, retention of urine. Schiffmann (1926) described what he believed to be a case of herpes of the bladder in a woman aged 31 years who presented with pain and

herpetic eruptions on the genitalia associated with labial oedema. There was urinary retention, and catheterization produced a blood-stained urine showing sterile pyuria. A cystoscopy was not performed but nevertheless the diagnosis was considered to be genital herpes with bladder involvement. Gremme (1931) also described the findings in a woman aged 31 years who presented as a case of right-sided pyelitis with fever; herpetic eruptions were present on the vulva and cystoscopy revealed a group of twenty vesicles, each about the size of a pin's head, situated on the bladder mucosa near the right ureter.

(5) Perianal and Anal Herpes

That genital herpes in the female can spread to involve the perineum, anus, and anal canal was reported by Unna (1883). It is often a painful condition, associated with discharge and tenesmus. The same area may be infected in males in the absence of genital involvement, when it is usually the result of homosexual contact (Hutfield, 1963a). Astruc (1736) first described this condition in "catamites and pathics who by the unnatural use of venery, were tormented with a grievous inflammation, as a result of these ulcers in the extremity of the rectum." Other sources of infection have been described. Thus, Sheward (1961) reported two cases of perianal herpes in identical male twins of 2 years, in whom the disease was thought to have developed after transmission of the virus through the alimentary tract from the mouth. Other workers have suggested that the virus is not passed in a simple manner through the alimentary tract from the mouth. In cases of gingivostomatitis the virus can be isolated from the faeces shortly after the onset of symptoms and is detectable both in the saliva and the faeces for as long as 3 months after clinical recovery. Probably the virus infects and grows in the lymphoid tissue of the small bowel. On rare occasions this may cause intussusception in infants and small children (Gardner, Knox, Court, and Green, 1962).

(6) Formes Frustes

Bolgert (1949) described a *forme fruste* of herpes genitalis, which appeared as an erythema only without a vesicular stage. Messner (1948) described three cases of a "varicelliform" variety; two of these were in females aged 24, and the other in a male aged 30 who was the husband of one of the women but had also had intercourse with the other. All three patients developed vesicular genital lesions which were full of pus and dimpled in a varicelliform pattern.

(7) Neuralgic Herpes of Mauriac

This condition, first described by Mauriac (1876) as *l'herpès névralgique des organes génitaux*, is a severe form of herpes with a nerve-root distribution involving the genito-anal area. Unna (1883) thought that some were true cases of herpes zoster, and that others were a type halfway between herpes zoster and genital herpes, the former usually being differentiated by its unilateral distribution and its limitation to the terminal distribution points of nerves.

A further case of neuralgic herpes genitalis was described by Daggett (1888/9); and Bolgert (1949), in a discussion on the subject, stated that in this condition the genito-anal region was the seat of violent paroxysmal pains which radiated from the back along the sciatic nerves to the lower limbs, and was associated with hyperaesthesia, and tenesmus and burning on micturition. Slavin and Ferguson (1950) stated that lesions of the thigh and face may sometimes appear as a zosteriform-like eruption in association with deep-seated pain and regional nerve involvement. The eruption usually follows a peripheral nerve distribution, although this is probably the result of lymphatic permeation. They suggested that recurrent "herpes zoster" is in all probability recurrent herpes simplex infection.

Painful genital herpes of the type described by Mauriac is at the present time more often seen in females, in association with herpetic vulvo-vaginitis which has spread to involve the perineum, anus, and anal canal. The lesions are usually extremely painful to touch and may be associated with dyspareunia or in some cases a disability in walking. In males, the neuralgic form is not so common, but may be associated with perianal herpes.

(8) In Relation to Menstruation

Unna (1883) stated that herpetic eruptions frequently coincided with the "menstrual epoch" and proposed the name *bouton de règle*. Diday and Doyon (1886) described 56 cases of genital herpes that recurred with menstruation: 25 (29 per cent.) were found in 86 confirmed prostitutes with genital herpes; 26 (58 per cent.) were found in patients attending the venereal diseases department with genital herpes; and five (9 per cent.) were found in 55 patients attending the dermatological department with genital herpes.

Levin (1900) also described genital herpes associated with menstruation and quoted figures from the venereal diseases clinic in Berlin in which he noted that 83 of 112 cases were associated with menstruation. Bergh (1890) stated that herpes lesions either preceded or followed menstruation, but more often preceded it. In 26.6 per cent. of a series of 877 cases

of herpes genitalis observed by him the disease was unrelated to menstruation.

Since the turn of the century little has been recorded about recurrent, menstrual genital herpes; most recent publications have been concerned with the influence of menstruation on extra-genital lesions. Niedermeyer (1925) and Anderson and Hamilton (1949) have both suggested that herpetic infection reactivated by menstruation is due to hormonal factors; the former saw two cases associated with genital hypoplasia due to hypofunction of the ovaries, and the latter described three patients in whom the eruption occurred 3 to 4 days before menstruation and was thought to be hormonal or ovarian in origin, as it occurred at the end of the menstrual cycle. Scott (1957), however, considered that recurrent menstrual herpes might be related to a rise in body temperature which is often a feature of this physiological cycle. Ottolenghi (1950) emphasized that recurrence of genital herpes in the female could be dependent or independent of the menstrual cycle, and observed that relapses were more common in those with blood group O.

Recurrent genital herpes coinciding with menstruation was seen in only one of fourteen female cases in a survey of 140 patients with herpes genitalis attending the venereal diseases department of St. Mary's Hospital. In other cases the eruption did not appear to be related to the menstrual cycle.

(9) In Relation to Trauma

Cases of recurrent herpes affecting an area of skin previously traumatized have been described by Findlay and MacCallum (1940). Trauma associated with sexual intercourse may also be a factor in the aetiology of recurrent genital herpes (Hutfield, 1963a). Boret (1838) described a case of recurrent herpes in a man aged 25 years who developed the eruption 36 hours after every intercourse. Unna (1883) and Fournier (1896) reported a case of vulval herpes in a 16-year-old girl which occurred 11 days after defloration.

(10) Psychosomatic Factors

Herpetic eruptions may also follow stress and anxiety states. Syphilophobia may be a feature of genital herpes (Hutfield, 1963a); in fact, this rather than the genital eruption often brings the patient to the venereal diseases department. In the majority of cases the phobia develops after the eruption has occurred; in some, however, it is present beforehand. Cooper (1900) stated that there appeared to be a psychosomatic cause for some eruptions of genital herpes, particularly in the case of a married man who had had illicit intercourse and then developed a guilt complex. Weichselbaum (1956), a psychiatrist,

described a case of recurrent herpes in a male, who was immature and highly suggestible, and in whom the eruptions were believed to be a response to shame and guilt feelings. These were thought to be associated with the identification of his wife with his mother after the birth of his son, and strengthened by a strong aversion and fear of infection originating from the demonstration to him by his doctor of his wife's vaginal secretions under the microscope.

A case seen at St. Mary's Hospital had a possible psychosomatic basis; a 43-year-old medical practitioner had suffered in his youth from recurrent genital herpes which disappeared after marriage. Several years later the marriage ended in divorce and then, perhaps as a result of subsequent illicit intercourse, he again experienced recurrent attacks. He emphasized that these were associated with a deep-seated syphilophobia. The latter was relieved only after repeated serological tests for syphilis.

Complications

Complications following an attack of genital herpes are rare, but two cases have been seen at St. Mary's Hospital. The first was that of a female patient who developed an herpetic paronychia of the right middle finger 3 days after scratching herpetic vesicles on the right labium majus. This patient was being treated with Idoxuridine and had been instructed to rupture the genital herpetic vesicles before applying the unction. The second was that of a male patient treated with a placebo who developed a thrombosis of the dorsal vein of the penis and a suppurating bubo in the left groin, as a result of secondary infection, and eventually required treatment by aspiration. A subsequent Frei test proved to be negative.

Other complications are reviewed below:

(1) *Urethral Stricture*.—This condition, consequent upon repeated attacks of urethral herpes, was described by Ortells (1921) in a man aged 33 with a 2-year history of intermittent "dysuria". Urethroscopic examination revealed small vesicles and superficial erosions in the region of a hard cartilaginous stricture of the bulb, with an adherent whitish-glossy fur. No abnormality was detected in the first 5 cm. Klausner (1924) also reported a case in a man aged 35 presenting with a serous urethral discharge; when he was first seen in 1916, the urethral mucous membrane in the meatal region was indurated and oedematous, the inguinal glands were enlarged and tender, and there was thickening of the dorsal lymphatics of the penis. The clinical picture was that of a meatal chancre, but scrapings did not reveal the *Treponema pallidum* and the

Wassermann reaction was negative. The patient consulted another venereologist at this time and was given 4.8 g. novarsenobillon. He suffered recurrent attacks of herpes in 1920, 1921, and 1922, all in the region of the original meatal lesion. The last attack was associated with difficulty in micturition as a result of meatal stricture which necessitated surgical treatment.

(2) *Aseptic Meningitis*.—Ravaut and Darré (1904) reported 21 cases of this complication out of a total of 26 cases of genital herpes (seven male and nineteen female). They described it as a "biological meningitis", by which they most probably meant an aseptic meningitis; examination of the cerebrospinal fluid showed a lymphocytosis with normal or slightly raised albumin; the fluid was sterile and polymorphs were absent. The condition was rarely associated with clinical meningitis and had a good prognosis. Léri and Lièvre (1930) described a case of acute lymphocytic non-tuberculous meningitis with fever and associated genital herpes. The serum and cerebrospinal fluid Wassermann reactions became positive but reverted to negative after 6 days and remained so without any specific treatment. Afzelius-Alm (1951) described a large number of cases of aseptic meningitis, of which six were shown to be due to the herpes simplex virus; one of these patients had a penile eruption 3 weeks before developing headache. Duxbury and Lawrence (1959) also reported a case in a male aged 23 who, 7 days after intercourse, developed a blister on the penis followed by occasional frontal headaches, which after a further 7 days became worse and were associated with vomiting. On admission to hospital his temperature was raised to 102°F. and there was neck stiffness; later he developed rigors. A lumbar puncture was performed and the cerebrospinal fluid showed a lymphocytosis and no other abnormality. The Wassermann reaction and Kahn test of the serum and cerebrospinal fluid were negative. The herpes simplex virus was isolated from the penile lesion but not from the cerebrospinal fluid. After several days the patient recovered, but he later suffered from recurrent penile eruptions.

(3) *Bubonulus*.—This is a focal suppurative lymphangitis which occurs on the dorsum of the penis and is often a complication of lymphogranuloma venereum and chancroid. Tottie (1942), however, described such a case in a previously healthy man, who developed herpes genitalis after having had typical prodromal symptoms. The penile lesion closely resembled *ulcus molle*, although tests for this condition proved to be negative. It was

complicated by a typical bubonulus of the penis which healed rapidly after it had been incised.

(4) *Genital Oedema*.—Kaufmann (1932) described the complication of vulval elephantiasis in a woman aged 38 who suffered from recurrent genital herpes. Coricciati (1952) reported a case of genital herpes in a male who treated himself with penicillin and sulphonamide powder and developed preputial oedema. Initially this was thought to be due to an allergic reaction to penicillin, but since there was no improvement on cessation of the treatment it was later thought to be a personal idiosyncrasy to the virus itself. Later the condition rapidly improved when treated with Aureomycin.

(5) *Phimosis*.—Astruc (1736) appears to have seen genital herpes in association with phimosis and paraphimosis, but it has never been described since. Phimosis was seen in association with genital herpes in some cases in this series, but it was doubtful whether the condition was caused by the disease.

(6) *Fusion of the Labia Minora* (synechia vulvae).—Astruc (1736) also appears to have seen genital herpes in association with what he described as "stricture or phimosis of the vagina". Brain (1956) described how the labia are often stuck together by a viscid serous discharge in association with vesicles on the labia minora and lower vaginal walls. A case of fusion of the labia minora as a result of infection and discharge, which may have been due to herpes, has been described by Hutfield (1961b).

(7) *Foetal Contagion*.—Ottolenghi (1950) stated that infants born of mothers with genital herpes have a high incidence of herpetic keratitis. Genital herpes in the mother may be the cause of generalized herpes simplex infection in the newborn infant. Mitchell and McCall (1963) described a case of herpes simplex infection in a newborn infant which was thought to be transplacental in origin. The lesion was noticed on the right forearm one hour after delivery and proven virologically to be herpes simplex. The mother had no history of herpetic infection but had a raised antibody titre. They stated that this was a case of transplacental infection of herpes, although the more common mode of infection is from active lesions in the birth canal. Schaffer (1960), summarizing the impression he gained from a review of the literature, stated that "transmission from mother to infant is never transplacental, the infant apparently acquiring his infection during the passage through the birth canal or by contact after birth". Sources of infection after birth may be a mother or midwife suffering from primary stomatitis, "cold sores", or herpetic whitlow. Symptom-

less salivary carriers may also infect a newborn infant as a result of kissing.

Herpes simplex infection in the newborn, occurring as a result of contagion with herpes genitalis in the mother, may be a fatal disease. Zuelzer and Stulberg (1952) described eight fatal cases of generalized herpes simplex in the newborn, one of which was infected as a result of contact with vulval herpes in the mother, which had been recurrent for 2 years. In all cases symptoms and signs occurred 5 to 7 days after delivery and took the form of either fever or hypothermia, increasing icterus, lethargy, vomiting, dyspnoea, cyanosis, and circulatory collapse. In five cases there was herpes viraemia associated with metastatic lesions in the liver, from which the virus was isolated in one case. In three others microscopic appearances of specific herpetic hepatitis were demonstrated. The authors stated that the virus of herpes simplex can cause a fatal disease in newborn infants in the absence of significant cutaneous lesions, by invading the blood stream as a result of herpetic gingivostomatitis acquired during passage through an infected birth canal. The conjunctivae and skin could also act as portals of entry and the possibility of placental transmission existed in one case in which it was demonstrated that the presence of maternal antibodies was not adequate for the protection of a premature infant. It was thought that their findings in these cases were sufficient evidence for the occurrence of herpes viraemia in the human subject and to which the premature infant was especially susceptible.

A further fatal case of generalized herpes simplex in the newborn baby, occurring as the result of contagion with herpes genitalis in the mother, was seen recently at the London Hospital (Hutfield, 1966).

Differential Diagnosis

(1) *Syphilis*.—From the venereologist's point of view, the most important disease that must be differentiated from herpes genitalis is syphilis. Syphilis is the "great mimic" and nothing could be more demonstrative of this than the primary chancre which in many cases closely resembles an herpetic lesion in the ulcerative stage; it is, however, often indurated and characterized by its comparative absence of pain and its indolent nature. *Treponema pallidum* can be demonstrated by dark-ground examinations in a majority of cases, whilst serological tests for syphilis may or may not be positive, depending on the length of time the lesion has been present. Secondary syphilis may also need exclusion if condylomata or mucous patches, which may resemble herpes, appear about the genitalia or anal

region. These are usually associated with a generalized rash or other secondary manifestations. Again *Treponema pallidum* can be demonstrated by dark-ground examinations in most cases and serological tests for syphilis are nearly always positive at this stage. Patients with anal and perianal herpes must have exhaustive tests to exclude the presence of syphilis, because of the high incidence of this disease in homosexuals. Bateman (1813) described how herpes preputialis could easily be confused with a syphilitic chancre. Fournier (1896) discussed this difficulty in differentiating herpes from a chancre. He described the papular type of herpetic lesion, which dries in the centre and thus simulates a chancre or a mucous patch. Similarly, he said that there were condylomatous types of herpes, which could easily be confused with syphilis.

In some cases the two diseases may coincide. Cooper (1900), in a discussion on herpes genitalis from a diagnostic point of view, pointed out this danger of a concomitant syphilitic infection. Touraine and Golé (1935) stated that the idea that herpes could precede or accompany a syphilitic chancre was time-honoured, and that herpes could be the portal of entry for *Treponema pallidum*. The fact that a syphilitic chancre could precede herpes was seldom reported, but they had seen such a case in a 31-year-old male who presented with a circle of five ulcers in the balano-preputial sulcus, which surrounded an indurated lesion that had appeared 4 to 5 days earlier and from which *Treponema pallidum* had been isolated. The organism was not isolated from the outer lesions, which healed after 4 days without treatment. This was followed by an increase in size of the chancre and the patient was then given antisyphilitic treatment. Blum and Leca (1940) also talked of the "dwarf chancre", which is surrounded by a ring of herpetic lesions, and how on several occasions they had noted the existence of what was thought to be true herpes, but the patient had later returned with a secondary rash and the Wasserman reaction was positive. They stressed that no patient should be sent away with a diagnosis of herpes who had had no previous attack, because the lesion might well be syphilitic. They thought that the cause of a concomitant syphilitic and herpetic infection was the fact that herpes was often related to other infections, and they submitted as evidence the fact that an eruption occurs with a pneumococcal or meningococcal infection, or at the beginning or end of other infectious diseases. Syphilis might well be an infection in which this occurs. They also stated that herpes being a virus infection might cause hormonal changes in the body leading to a greater susceptibility to a syphilitic infection; this

was described as a "state of anergy". Finally Prof. Fournier's classification of the three types of herpes in association with syphilis was quoted as follows:

- (i) Local, with herpes on the same spot as a chancre.
- (ii) Regional, with herpes in the "metameric"* region of a chancre;
- (iii) Herpes at a distance, with herpes on the vulva associated with a chancre on the cervix.

Koch (1936) also reported that syphilis was often found together with genital herpes, he described three cases in women with scattered genital ulceration associated with a painful inguinal adenopathy; as it had not been possible to isolate *Treponema pallidum* from any of the lesions they were diagnosed as cases of herpes. All three patients, however, later developed positive Kahn reactions which spontaneously reverted to negative, and in none was the Wassermann reaction ever positive. He thought that the possible explanation for this was the presence of a congenital syphilitic infection in all cases.

It is essential, therefore, for every case of herpes genitalis to be subjected initially to repeated dark-ground examinations and to serological tests for syphilis. Serological tests must also be performed at regular intervals for 3 months after the lesions have healed.

(2) *Chancroid* (soft sore, *ulcus molle*).—The initial lesion of this disease also commences as a vesicle, which rapidly becomes a pustule and then breaks down to form a non-indurated ulcer with a ragged undermined edge. Diagnosis is confirmed by obtaining Ducrey's bacillus from scrapings of the ulcer or by culture. Fournier (1896) stated that herpes could be confused with soft sore, but that the latter could also be diagnosed by the use of a spatula, which will adhere to its edges as it is drawn over it, and by demonstrating "elastic fibres" in smears from the ulcer on a glass slide. Gaté (1928) stated that he had observed several cases of herpeticiform chancroid in men, in which he had been able to isolate Ducrey's bacillus from pus collected from the borders of the lesions. Diagnosis was also confirmed by intradermal tests and by autoinoculation from similar lesions. The erosions were found in the balano-preputial sulcus; they were the size of a head of a hat-pin and were often single. Willbrand (1931) described what he thought to be a case of recurrent herpes on the site of an earlier soft sore in a man aged 24. He had suffered with recurrent genital herpes from puberty until the age of 24, when he developed a soft sore. This was diagnosed as such by the fact that a similar lesion was produced on the lower abdominal wall

*Metameric—pertaining to a metamer or a segment of a crustacean fish.

within 2 days by experimental autoinoculation; 8 months later this was followed by a vesicular eruption on the site of the original lesion, which lasted 3 weeks and then healed. After an interval of a year the eruption recurred and histological examination proved it to be herpetic.

(3) *Behçet's Syndrome*.—Described by Behçet in 1937, this is a disease entity of unknown aetiology consisting of recurrent painful ulcerations of the mouth and genitalia occurring singly or in crops and associated with relapsing iridocyclitis. The syndrome can occur in either males or females, and in the latter it is often noticed to have a periodicity coincident with the menstrual cycle. Since Behçet's original description, other features have been recognized, such as erythema nodosum, arthralgia, retinitis, central nervous system involvement, pyoderma, epididymitis, thrombophlebitis, and urethritis (Hutfield, 1961a). Scarring of the genitalia may result from repeated attacks. The disease is more common in females, and in the early stages may present a problem in the differential diagnosis of genital herpes, particularly recurrent menstrual herpes.

(4) *Lipschütz Ulceration* (ulcus vulvae acutum).—This can present as a single ulcer or as multiple ulcerations which are painful, indolent, and deep with serpiginous edges. They are soft and are usually found around the introitus or in the vagina and ultimately heal by extensive scarring. The cause is unknown, but a recent theory is that the condition is probably a localized form of Behçet's syndrome.

Kumer (1932) described an atypical form of herpes genitalis in which the ulcers frequently merged to form large ones and by becoming secondarily infected, penetrated deeply. They could then be confused with ulcus vulvae acutum, or the disease described by Lipschütz, but were finally diagnosed as herpes by animal experiments.

(5) *Lymphogranuloma Venereum*.—This virus disease presents as an herpetiform lesion on the external genitalia or as a proctitis, and is often followed by a typical bubo of the groin glands. Diagnosis is confirmed by a positive Frei intradermal test and a positive serological complement-fixation test with a rising titre (> 1 in 16). Ottolenghi (1950) stated that herpetic lesions about the genitalia often act as a portal of entry for syphilis and lymphogranuloma venereum.

(6) *Simple Abrasion*.—A traumatic lesion on the genitalia as a result of intercourse may require differentiation in some cases.

(7) *Herpes zoster*.—The causative virus of this condition differs from that of herpes simplex in that it attacks the posterior root ganglia of cranial and spinal nerves resulting in a painful vesicular cutaneous eruption in the root area of the affected nerve, which is usually unilateral in distribution. Such a unilateral eruption may appear on the genitalia; it is characterized by pain, preceding and accompanying the eruption, which is more severe than that which occurs in herpes simplex infection and is often associated with a raised temperature. Herpes zoster more often occurs at a later age than herpes simplex infection and there may be a history of contact with chicken pox. Diagnosis is confirmed by isolating herpes zoster virus from vesicular fluid.

Discussion

Up to the present there has been no systematic study of this common disease in its genital manifestations. By collecting information from the majority of published papers and observing a considerable number of cases, it has been possible to provide a detailed clinical description of herpes genitalis together with recent illustrations. Published and unpublished works have been incorporated to give a clear picture of all aspects of the disease, many of which have been previously described in isolated studies but are now presented as a uniform syndrome. Because of a dearth of recent studies in the current literature it has sometimes been necessary to work in the distant past, since support for some generally recognized features of this disease could be found only in publications which are now considered to be historical.

A review of the literature has shown that most of the descriptive studies on herpes genitalis were made in the 18th and 19th centuries mainly by French and German workers and that the chief contributions to the subject in the 20th century have been in the fields of virology and treatment. It is noted that, of all the authors who have published work dealing particularly with this subject up to the time of writing this thesis in 1963, only the following four have been traced to be British: Sir Jonathan Hutchinson (1890), Cooper (1900), Avit-Scott (1931), and Hutfield (1963a).

Summary and Conclusions

In response to recent statements that little has been written on the subject of herpes genitalis, a detailed description of the general clinical features, genital manifestations, complications, and differential diagnosis has been given. It has been noted that

of all the authors who published work dealing particularly with this subject up to the time of writing this thesis in 1963, only four were British.

The work on which this thesis was based was done during the tenure of appointments at St. Mary's, The London, and St. Thomas' Hospitals.

I am indebted to Mr Ambrose King, F.R.C.S., and Dr E. M. C. Dunlop, M.D., M.R.C.P., Consultant Venereologists, The London Hospital, London, E.1., and to Dr R. R. Willcox, M.D., Consultant Venereologist, St. Mary's Hospital, London, W.2., for their criticism and advice on the final preparation of the script; to The Wellcome Historical Museum and Library for historical works provided; to Mr Thomas Cassidy of the National Library of Medicine, Washington, D.C., for photocopies of papers otherwise unavailable in this country, and to the Royal Society of Medicine for translations.

REFERENCES

- Afzelius-Alm, L. (1951). *Acta med. scand.*, **140**, Suppl. 263.
- Astruc, J. (1736). "De morbis veneris", Liber III, Caput VIII, p. 254. Paris. (By courtesy of the 'Wellcome Trustees'.)
- Anderson, S. G., and Hamilton, J. (1949). *Med. J. Aust.*, **1**, 308.
- Avit-Scott, J. (1931). *Lancet*, **1**, 972.
- Bateman, T. (1813). "A Practical Synopsis of Cutaneous Diseases", p. 234. Longman, Hurst, Rees, Orme, and Brown, London. (By courtesy of the 'Wellcome Trustees'.)
- Behçet, H. (1937). *Derm. Wschr.*, **105**, 1152.
- Bergh, R. (1890). *Mscr. prakt. Derm.*, **10**, 1.
- Bettman, S. (1902). *Münch. med. Wschr.*, **49**, 692.
- Blum, P., and Leca, J. (1940). *Ann. Mal. vénér.*, **35**, 1.
- Bolgert, M. (1949). *Presse méd.*, **57**, 598A (Supplement to No. 41—June 22).
- Boret, de (1838). *J. Méd. Chir. prat. (Paris)*, **9**, 344.
- Brain, R. T. (1956). *Brit. med. J.*, **1**, 1061.
- Cooper, A. (1900). *Ibid.*, **1**, 1219.
- Coricciati, L. (1952). *Minerva dermat.*, **27**, 183.
- Coutts, W. E. (1948). *Brit. J. vener. Dis.*, **24**, 109.
- Daggett, W. G. (1889). *Univ. med. Mag. (Philad.)*, **1**, 417.
- Diday, P., and Doyon, A. (1876). "Thérapeutique des maladies vénériennes et des maladies cutanées", p. 58. Masson, Paris.
- (1886). "Les herpès génitaux," p. 122. Masson, Paris. (By courtesy of the University of Lyons Library.)
- Duxbury, A. E., and Lawrence, J. R. (1959). *Med. J. Aust.*, **2**, 250.
- Esteves, J., and Pinto, M. R. (1952). *Brit. J. vener. Dis.*, **28**, 205.
- Findlay, G. M., and MacCallum, F. O. (1940). *Lancet*, **1**, 259.
- Fournier, J. A. (1896). *Rev. gén. Clin. théor. (Paris)*, **10**, 177. (By courtesy of the National Library of Medicine, Washington, D.C.)
- Gardner, P. S., Knox, E. G., Court, S. D. M., and Green, C. A. (1962). *Brit. med. J.*, **2**, 697.
- Gaté, J. (1928). *Bull. Soc. franç. Derm. Syph.*, **35**, 739.
- Glanville, H. de (1963). *Lancet*, **2**, 462.
- Gremme, A. (1931). *Zbl. Gynäk.*, **55**, 1558.
- Harkness, A. H. (1950). "Non-gonococcal Urethritis", p. 196. Livingstone, Edinburgh.
- Hutchinson, J. (1890). *Arch. Surg. (Lond.)*, **1**, 351.
- Hutfield, D. C. (1961a). *Brit. med. J.*, **1**, 906.
- (1961b). *Ibid.*, **2**, 454.
- (1963a). *Brit. J. vener. Dis.*, **39**, 181.
- (1963b). *Lancet*, **2**, 639.
- (1966). *J. Obstet. Gynaec. Brit. Cwltth*, **73**, 1020.
- , Wasley, G., and Gray, E. (1967). *Brit. J. vener. Dis.*, **43**, 48.
- Kaufmann, C. (1932). *Z. Geburtsh. Gynäk.*, **104**, 188.
- Klausner, E. (1924). *Derm. Wschr.*, **78**, 342.
- Klotz, H. G. (1914). *Ibid.*, **58**, 649.
- Koch, F. (1936). *Münch. med. Wschr.*, **83**, 1744.
- Kumer, L. (1932). *Arch. Derm. Syph. (Berl.)*, **166**, 41.
- Lazar, M. P. (1955). *A.M.A. Arch. Derm.*, **72**, 272.
- Léri, A., and Lièvre, J. A. (1930). *Bull. Soc. méd. Hôp. Paris*, p. 1256.
- Levin, E. (1900). *Dtsch. med. Wschr.*, **26**, 277, 293.
- Mauriac, M. (1876). *Gaz. Hôp. (Paris)*, **49**, 83. (By courtesy of the 'Wellcome Trustees'.)
- Messner, F. (1948). *Wien. med. Wschr.*, **98**, 103.
- Mitchell, J. E., and McCall, F. C. (1963). *Amer. J. Dis. Child.*, **106**, 207.
- Nasemann, T., and Nagai, R. (1960). *Münch. med. Wschr.*, **102**, 475.
- Nicolas, J., Gaté, J., and Papacostas, G. (1923). *J. Méd. Lyon*, **4**, 291.
- Niedermeyer, A. (1925). *Zbl. Gynäk.*, **49**, 2694.
- Ortells, C. (1921). *Progr. Clin.*, **18**, 478. (Spanish) (*Abstr. Zbl. Haut-u. Geschl.-Kr.* (1921). **2**, 122.)
- Ottolenghi Szlezzynger, M. (1950). *Minerva Ginec.*, **2**, 195.
- Ravaut, P., and Darré. (1904). *Ann. Derm. Syph. (Paris)*, **4** sér., **5**, 481.
- Rollet, J. (1869). *Ibid.*, **1**, 33, 100.
- Schaffer, A. J. (1960). "Diseases of the Newborn", p. 662. Saunders, Philadelphia.
- Schiffmann, J. (1926). *Z. urol. Chir.*, **19**, 342.
- Scott, T. F. McNair (1957). *Amer. J. Ophthal.*, **43**, no. 4, pt 2, p. 134 (Suppl.)
- Sheward, J. D. (1961). *Lancet*, **1**, 315.
- Slavin, H. B., and Ferguson, J. J. (1950). *Amer. J. Med.*, **8**, 456.
- and Gavett, E. (1946). *Proc. Soc. exp. Biol. (N.Y.)*, **63**, 343.
- Tottie, M. (1942). *Acta dermat.-venereol. (Stockh.)*, **23**, 306.
- Touraine, A., and Golé, L. (1935). *Bull. Soc. franç. Derm. Syph.*, **42**, 782.
- Unna, P. G. (1883). *J. cutan. vener. Dis.*, **1**, 321.
- Weichselbaum, P. (1956). *Psychosomat. Med.*, **18**, 81.
- Willbrand, L. (1931). *Derm. Wschr.*, **93**, 1219.
- Zuelzer, W. W., and Stulberg, C. S. (1952). *Amer. J. Dis. Child.*, **83**, 421.

L'herpès génital

RÉSUMÉ

En réponse à des déclarations faites récemment que très peu a été écrit au sujet de l'herpès génital, une description détaillée des signes cliniques en général, des manifestations génitales, des complications et du diagnostic différentiel a été donnée. Il a été noté que de tous les auteurs qui ont publié leurs travaux portant principalement sur ce sujet jusqu'au moment où cette thèse a été écrite en 1963, seulement quatre étaient des Britanniques.