

only one functional centromere. This implies some mechanism for centromere inactivation in such chromosomes.

The locus for SOD-1 has been assigned to 21q22.1.⁸ These investigators suggested that trisomy for 21q22.1 is necessary to produce Down's syndrome and that excess SOD-1 is pathogenic for the syndrome. In the context of these observations, the increased activity of SOD-1 in our proband provides additional evidence that band 21q22.1 is trisomic in her case.

Of interest also in the family described here is the presence of an unusually long secondary constriction extending into both arms of a chromosome 9 in the phenotypically normal mother and brother of the proband. Somewhat similar 'inversions' of chromosome 9 are relatively common⁹ and there has been considerable debate about their possible deleterious consequences. Frequently, there have been no recognisably adverse phenotypic features in persons carrying such an 'inversion', as was the case in the present instance, though the mother concerned produced a child with a tandem (21;21) chromosome. We have been unable to find any record of a similar association, which suggests that it was coincidental in our family. Whether in fact this is so cannot be established with certainty on the evidence available.

We are grateful to D Chiu, M Frecker, C Ho, C Jones, K Kaleta, and M Wood for technical assistance.

J M BERG, H A GARDNER,
R J M GARDNER, E G GOH,
V D MARKOVIĆ, N E SIMPSON, AND
R G WORTON

*Departments of Genetics, Hospital for Sick
Children and Surrey Place Centre, Toronto;
Division of Cytogenetics, Department of
Pathology, Toronto General Hospital; and
Division of Medical Genetics, Queen's University,
Kingston, Ontario, Canada*

References

- Hall B. Mongolism in newborns: a clinical and cytogenetic study. *Acta Paediatr Scand (Suppl)* 1964;154:1-95.
- Walker NF. The use of dermal configurations in the diagnosis of mongolism. *Pediatr Clin North Am* 1958; 5: 531-43.
- Reed TE, Borgaonkar DS, Conneally PM, Yu P, Nance WE, Christian JC. Dermatoglyphic nomogram for the diagnosis of Down's syndrome. *J Pediatr* 1970;77: 1024-32.
- Bloom SE, Goodpasture C. An improved technique for selective silver staining of nucleolar organizer regions in mammalian chromosomes. *Hum Genet* 1976; 34:199-206.
- de Chatelet LR, McCall CE, McPhail LC, Johnston RB Jr. Superoxide dismutase activity in leucocytes. *J Clin Invest* 1974;53:1197-201.
- Simpson NE, Frecker M. The dosage effects of superoxide dismutase in trisomy 21 and nucleosidephosphorylase (NP) in trisomy 14. *Abst V Int Cong Hum Genet* 1976:153.
- Hagemeyer A, Smit EME. Partial trisomy 21—further evidence that trisomy of band 21q22.1 is essential for Down's phenotype. *Hum Genet* 1977;38:15-23.
- Sinet PM, Couturier J, Dutrillaux B, Possonnier M, Raoul O, Rethoré MO, Allard D, Lejeune J, Jerome H. Trisomie 21 et superoxyde dismutase-1 (IPO-A). Tentative localisation sur la sous bande 21q22.1. *Exp Cell Res* 1976;97:47-55.
- de la Chapelle A, Schröder J, Stenstrand K, Fellman J, Herva R, Saarni M, Anttolainen I, Tallila I, Tervila L, Husa L, Tallqvist G, Robson EB, Cook PJL, Sanger R. Pericentric inversions of human chromosomes 9 and 10. *Am J Hum Genet* 1974;26:746-66.

Requests for reprints to Dr J M Berg, Surrey Place Centre, 2 Surrey Place, Toronto M5S 2C2, Canada.

Ring chromosome 10: 46,XX,r(10)(p15→q26)

SUMMARY Cytogenetic analysis of an 8-month-old Japanese girl with moderate retardation of physical development was performed and a ring chromosome 10, 46,XX,r(10)(p15→q26), was found. She had short stature, mildly stubby nose, antimongoloid slants, and moderately protruding ears. The extremities showed erythrocyanosis, oedema, and pigmentation. Lansky *et al*¹ was the first to describe ring chromosome 10 with a Turner-like phenotype. Only two other cases^{2,3} have been reported so far and little is known about this syndrome. This is the report of a fourth case.

Case report

The proband, an 8-month-old Japanese girl, was born on 26.6.75 to a 23-year-old, gravida 1, para 1 mother and a 27-year-old father. The parents were unrelated, healthy, and of normal height and intelligence. At 3 months' gestation, her mother showed signs of threatened abortion and was injected with HCG five times. After 42 weeks of gestation, the patient was delivered spontaneously in breech position. Birthweight was 2500 g and Apgar score was 8 at 5 minutes. The newborn baby appeared normal but had feeding difficulties. At 6 months, she was sent to us because of retarded growth. At that time, her weight, length, head and chest circumference were 5300 g (-2.4 SD), 60.3 cm (-2.4 SD), 38.8 cm (-2.6 SD), and 37 cm, respectively. Her face had a mildly stubby nose, antimongoloid slants, strabismus, and moderately protruding ears (fig 1). Erythrocyanosis, oedema, and pigmentation of both feet, as seen in incontinentia

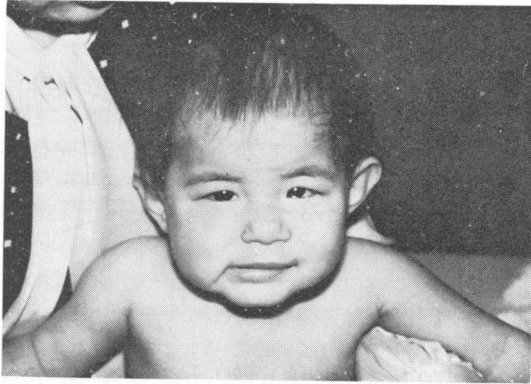


FIG 1 Front view of patient.

pigmenti, were found. The large fontanelle was still slightly open and many atrophic areas in both choroids were shown by fundoscopy, but electroencephalogram, echoencephalography, and skull x-rays showed no abnormalities. The liver could be felt 1 cm below the rib cage. No significant heart murmur was heard. Laboratory and physical examinations, including radiography, routine blood examinations, liver function, thyroid function, DNA and microsome tests, and immunoglobulins, were all within normal limits. IVP showed non-obstructive dilatation of the right pelvis and calices.

Developmental milestones were mildly delayed; she had head control at 8 months and walked with and without support at 12 and 27 months, respectively. At the age of 1 year 4 months febrile convulsions appeared. She now speaks a few words at the age of 3.

Dermatoglyphs showed no specific pattern.

CHROMOSOME STUDIES

Cytogenetic studies were carried out on peripheral blood cultures using four analytical methods. Conventional methods showed that there were 46 chromosomes. In the place of one missing C group chromosome a ring chromosome was found. Trypsin-Giemsa banding identified the ring chromosome as a ring 10 (fig 2). Autoradiographic studies showed that this ring chromosome was not late-replicating like an abnormal X.

The karyotype was 46,XX,r(10)(p15→q26). Most cells contained one monocentric ring and one normal chromosome 10, but others had either no ring or two. In addition, a large ring was occasionally found, which seemed to be a dicentric ring with two C bands (fig 3).

To ascertain the relationship between the occurrence of these variations and the culture length, cultures were carried out on peripheral blood for 2 to 7 days and 100 metaphases were analysed daily. In the second day's sample, 96 cells had 46 chromosomes with one ring, one had no rings, and three had large rings. Thereafter, aneuploid cells rapidly increased reaching 21% after 6 days, two thirds (15%) of which had 45 chromosomes without a ring. The dicentric ring was observed in all cultures but day 4's culture (table). Positive sex chromatin rate

TABLE Variation in karyotype with length of time in culture

	Period of culture (days)					
	2	3	4	5	6	7
No ring	% 1	14	17	13	15	6
Two rings	0	1	1	2	1	3
Large ring	3	1	0	1	2	2
Total aneuploid cells	4	17	19	17	21	15

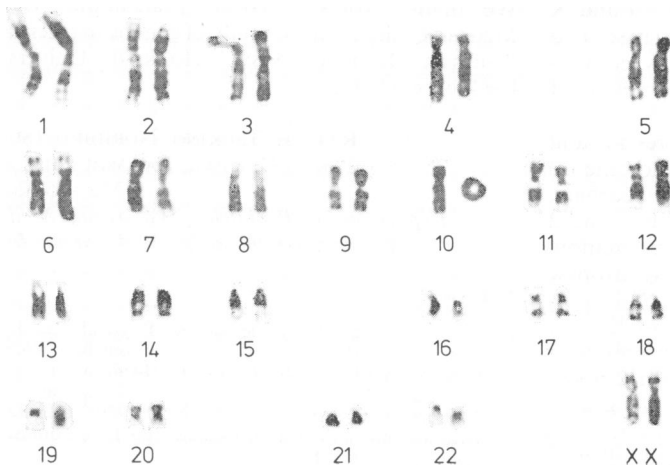


FIG 2 Trypsin-Giemsa banded karyotype of patient.

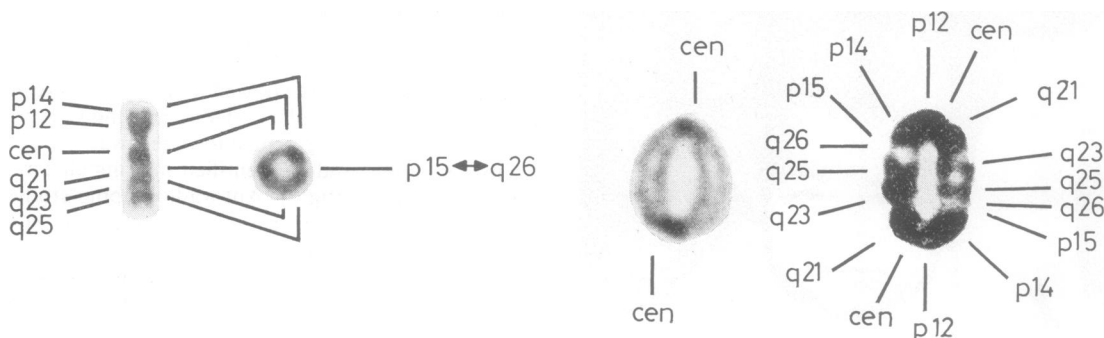


FIG 3 G band patterns of monocentric ring (left) and C and G band patterns of dicentric (right). The breakpoints are located at p15 and q26.

was 15% by buccal smear stained with acetic orcein. Both parents had a normal karyotype.

STUDY OF GENETIC MARKERS

A study of 26 genetic markers, including GPT and GOT, showed that there was no locus on the deleted chromosome.

Discussion

Until now, two female cases,^{1,3} besides our own, and a male case² of ring chromosome 10 have been reported.

Initially, all female cases were erroneously considered to be Turner's syndrome. The reasons were as follows: in the cases of Lansky *et al*,¹ short stature, small head circumference, widely spaced nipples, and pectus excavatum; in the case of Sparkes *et al*,³ early childhood short stature and late onset and irregularity of spontaneous menses; and in our case, short stature and pedal oedema. The difficulty in distinguishing chromosomes 10 and X has also led to inconsistent results. These two chromosomes cannot be distinguished by conventional methods and show a certain amount of similarity on G banding.

Common clinical features in the present and previously reported cases of ring chromosome 10 are: short stature, pectus excavatum, microcephaly, stubby nose (during infancy?), widely spaced nipples, and mild mental and physical retardation. Other notable clinical findings were: many atrophic areas in both choroids in our case and that of Fryns *et al*,² cardiac anomaly with mitral valve insufficiency in the case of Sparkes *et al*,³ supraventricular tachycardia in the case of Fryns *et al*,² a 2/6 systolic murmur in the case of Lansky *et al*,¹ genitourinary anomaly with urinary bladder obstruction of unknown cause and a well-differentiated follicular

adenocarcinoma of the thyroid in the case of Sparkes *et al*,³ and non-obstructive dilatation of right pelvis and calyces in our case.

Dermatoglyphs showed no specific pattern except for the case of Sparkes *et al*³ which had an ulnar loop on the fingers.

Chromosome analysis of three cases including ours showed that most cells had one monocentric ring, although Lansky *et al*¹ reported a mosaic case. The decreasing incidence of the ring chromosome with prolonged culture time may reflect the *in vivo* instability of the ring chromosome. We could not distinguish the distal part of both the arms which were deleted during ring formation, but Fryns *et al*² found these on the short arm of a chromosome 19.

Nine genetic markers are known to be located on chromosome 10: GPT-1, ADK, PP, HK-1, EBS-130, GOT-S and FUSE.⁴ We examined 26 genetic markers, including GPT and GOT, but no evidence was found for a monosomic value for these.

We thank Professor Hideo Matsumoto, Osaka Medical College, for the study of genetic markers and Professor Motomichi Sasaki, Hokkaido University, for kind guidance.

RYUICHI TSUKINO, NORIHIKO TSUDA,
TOHRU DEZAWA, TADASHI ISHII, AND
MICHIO KOIKE

Department of Pediatrics, Wakayama Medical
College, 9-Kyubancho, Wakayama, Japan

References

- Lansky S, Daniel W, Fleiszar K. Physical retardation associated with ring chromosome mosaicism: 46,XX,r(10)/45,XX,10-. *J Med Genet* 1977;14:61-3.
- Fryns JP, De Boeck K, Jaeken J, van den Berghe H. Malformative syndrome associated with a ring 10 chromosome and a translocated 10p/19 chromosome. *Hum Genet* 1978;43:239-44.

³ Sparkes RS, Ling SM, Muller H. Ring 10 chromosome: 46,XX,r(10)(p15q26). *Hum Genet* 1978;43:341-5.

⁴ McKusick VA. In: *Mendelian inheritance in man*. 5th ed. Baltimore: Johns Hopkins University Press, 1978.

Requests for reprints to Dr R Tsukino, Department of Pediatrics, Wakayama Medical College, 9-Kyubancho, Wakayama, Japan.

Hypomelanosis of Ito with triphalangeal thumbs

SUMMARY A black female with abnormal skin pigmentation, similar to that seen in hypomelanosis of Ito, and triphalangeal thumbs is presented. This association has not previously been reported.

Incontinentia pigmenti achromians, or hypomelanosis of Ito, a neurocutaneous syndrome which includes hypopigmented areas of the skin in whorls, streaks, and patches, occurring either bilaterally or unilaterally, was first described in 1952 by Ito.¹

This syndrome has been associated with several other abnormalities including mental retardation and epilepsy.² Ocular and musculoskeletal anomalies have also been reported.³ A black girl with the typical skin lesions of hypomelanosis of Ito and triphalangeal thumbs, a previously unreported finding, is presented here.

Case report

A 10½-year-old black girl was referred to the Genetics Screening and Counseling Service with a diagnosis of the Holt-Oram syndrome. She was the product of a normal term pregnancy and spontaneous vaginal delivery. Birthweight was 2640 g, and length was 47 cm. The mother states that the patient had the depigmented areas at birth but that there were no other abnormalities of the skin, such as bullae. She had poor weight gain in the first few months and was admitted to hospital for evaluation of failure to thrive. The diagnosis of the Holt-Oram syndrome was suggested after a grade 2/6 murmur was noted. She also showed significant developmental delay at that time. She continued to develop slowly and started walking between 5 and 6 years of age. At 10 years 4 months, she was estimated to be functioning at the 2-year-old level. The family history was negative for any similar findings, skin lesions, or mental retardation.

Physical examination at 10½ years (fig 1) showed a very small, unusual-looking black girl with severe mental retardation. The height was 108 cm, less than the 3rd centile for age. The weight was 17.7 kg, less than the 3rd centile for age. Head circumference was 49 cm, below the 2nd centile for age. Other abnormal findings included ocular hypertelorism with an intercanthal distance of 3.9 cm and an outer orbital distance of 10 cm, a small pit in the superior helical region of the right ear, and a small ear tag on the left. The neck appeared short with limitation of rotation. There was kyphosis and scoliosis. The

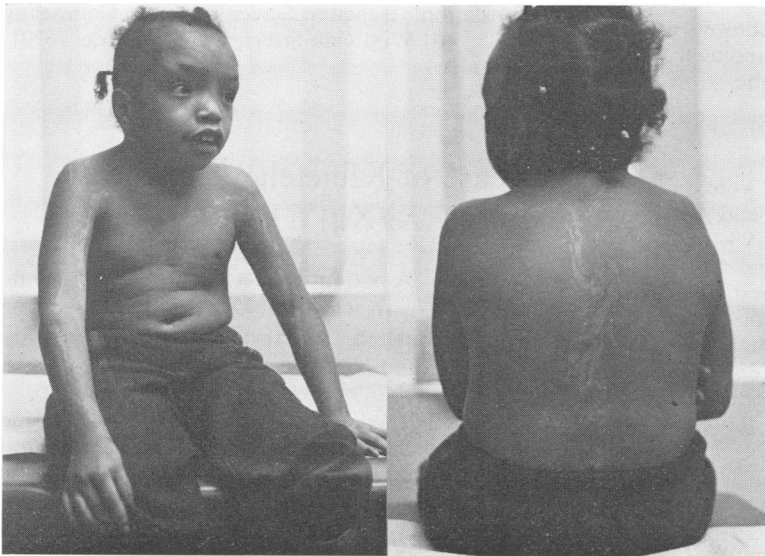

FIG 1 Proband at age 10½.