

complete 5p trisomy cases. The main features are normal weight and length at birth, macrocephaly, psychomotor retardation, hypotonia, postnatal growth failure, and facial dysmorphism involving mongoloid eye slant, epicanthus, hypertelorism, low set and dysplastic ears, and flat bridge of the nose. The lower extremities show short first toes and club feet.

The three reported cases with complete 5p trisomy had seizures. In our patient most of the main features mentioned were present but, in addition, he had a congenital heart defect, not seen in the three cases reported. However, seizures were not noted in our patient.

Tetrasomy 9p confirmed by GALT

P BALESTRAZZI, G CROCI*, C FRASSI, F FRANCHI*, AND G GIOVANNELLI

Department of Paediatrics, University of Parma, 43100 Parma; and

**Genetic Laboratory USL 9, 42100 Reggio Emilia, Italy.*

SUMMARY We report a boy aged 12 years 7 months with mental retardation, hydrocephalus, dysmorphic facial features, congenital heart disease, and skeletal and renal anomalies. The karyotype showed a mosaic tetrasomy 9p involving the secondary constriction. This result was confirmed by tetraplex gene dosage effect for galactose-1-P-uridyltransferase (GALT). Comparing the clinical features of our case with those of previously reported patients, tetrasomy 9p appears to be a distinctive and clinically recognisable malformation syndrome.

Tetrasomy for the short arm of chromosome 9 is a very rare condition, first described by Ghymers *et al.*¹ Since then, tetrasomy 9p has been found in eight additional patients with variable phenotypic expression and cytogenetic findings. This report concerns a new case of tetrasomy 9p in a male aged 12 years 7 months.

Case report

The proband is the second child of healthy, unrelated parents. The mother was 38 and the father 36 years old at the time of his birth. The family history is

References

- 1 Khodr GS, Cadena G, Le Loan K, Kagan-Hallet S. Duplication (5p13→pter): prenatal diagnosis and review of the literature. *Am J Med Genet* 1982;12:43-9.
- 2 Leschot NJ, Lim KS. 'Complete' trisomy 5p, de novo translocation t(2;5) (q36;p11) with isochromosome 5p. *Hum Genet* 1979;46:271-8.
- 3 Cordero JF, Miller WA, Liberfarb RM, Atkins L, Holmes LB. Trisomy 5p: a variable phenotype. *Pediatr Res* 1977;11:535.

Correspondence and requests for reprints to Dr E Orye, Laboratory of Cytogenetics, Department of Pediatrics, Akademisch Ziekenhuis, Rijksuniversiteit Gent, De Pintelaan 185, B-9000 Gent, Belgium.

unremarkable and the couple's first child is in good health.

The proband was born at term by normal delivery after a normal pregnancy. Birth weight was 3200 g. Asphyxia and skull asymmetry owing to a left parietal cephalohaematoma were noted at birth. At the age of 12 years 7 months he was admitted to hospital because of mental retardation and dysmorphic features.

PHYSICAL EXAMINATION

The following findings were present (fig 1): normal growth with a height of 157 cm (75th to 90th centile) and weight 39 kg (50th to 75th centile). He had a macrocephalic and asymmetrical skull, head circumference 58 cm (>97th centile), a low anterior hairline, multiple hair whorls, flat forehead, sunken eyes, moderate hypertelorism, antimongoloid slants, broad nasal root, high nasal bridge and bulbous nasal tip, short philtrum, down-turned corners of the mouth, retrognathia, cup-shaped, anteriorly rotated, and protruding ears, and a short neck. There was marked thoracic kyphosis and lumbar scoliosis with hyperlordosis, narrow chest widely spaced nipples, protruding abdomen, mild truncal obesity, and narrow pelvis. There was also an incurved radius and ulna, limited joint movements of the elbows, knees, and ankles, coxa and genu valga, narrow hands and feet, bilateral pes planovarus, and dysplasia of the

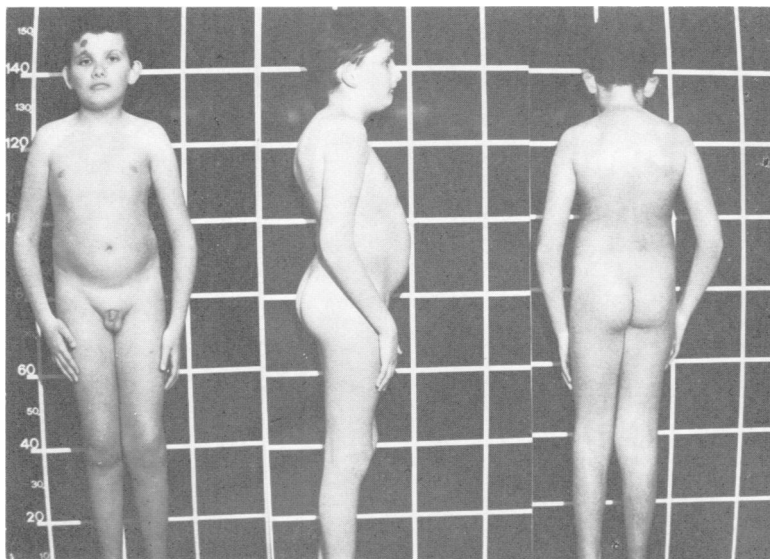


FIG 1 The proband aged 12 years 7 months.

finger and toenails. The penis was small (3.2 cm in length) and he had palmed penoscrotal skin folds, testes 8 ml in volume, and no pubic or axillary hair. There was moderate generalised muscle hypertonia, ataxia of gait, and severe mental retardation (VIS was 48 and PIQ was too low to be informative at WISC test). The dermatoglyphic formula was:

Right hand W, UL, UL, W, UL, r' 9. 7. 5. 4.
Ac. O.O.L.O.

Left hand W, UL, RL, RL, UL, r' 11. 9. 7. 5.
Ac. W.O.L.O.

RADIOLOGICAL AND LABORATORY FINDINGS

X-rays of the skeleton showed an asymmetrical and dolichocephalic skull, enlarged sella, thoracolumbar kyphoscoliosis, cleft of the posterior arc of D12-L1-L2, incurved radius and ulna, coxa and genu valga, narrow iliac wings, wide interpubic distance, osteoporosis of the metacarpal and metatarsal bones, bilateral pes planus, clinodactyly of the big toes, slender metatarsals 2 to 5, and delayed bone age (11 years according to Greulich and Pyle²).

Intravenous pyelography and renal echotomography showed both kidneys located on the right side and fused together.

In the heart there was an ejection systolic click and mild diastolic murmur (1-2/6) in the aortic area suggestive of aortic insufficiency. The EKG showed mild left axis deviation (AQRS = -30°).

The eyes showed marked myopia at $\overline{00}$, nystagmus,

chorioretinal dystrophy, papillastaphyloma, and refraction disorders.

CNS studies showed maturation delay of alpha waves with generalised slow paroxysms on the EEG, moderate ventricular enlargement consistent with an established hydrocephalus, and severe cerebellar and cerebral atrophy especially of the right frontal lobe on CT scan.

Routine blood and urine analysis were normal. GnRh and HCG tests were within normal limits for the start of puberty.

CHROMOSOME ANALYSIS

Chromosome analysis (fig 2) was performed on peripheral blood lymphocytes. Of 200 mitoses examined, 194 metaphases showed 47 chromosomes and six had a normal 46,XY karyotype. Using standard staining (R, G, and C banding methods) the additional chromosome was interpreted as an isodicentric chromosome 9 with a breakpoint at band 9p12. Cd banding showed that one centromere was inactive. The proband's karyotype was therefore 46,XY/47,XY,+idic(9)(pter \rightarrow q12::q12 \rightarrow pter). Both parents had normal chromosomes.

ENZYME ANALYSIS

The red cell activities of glucose-6-P-dehydrogenase, hexokinase, and glutathion reductase, assayed for the purpose of comparative measurements, were within the normal ranges. The galactose-1-P-uridyl-transferase (GALT) assay was carried out using

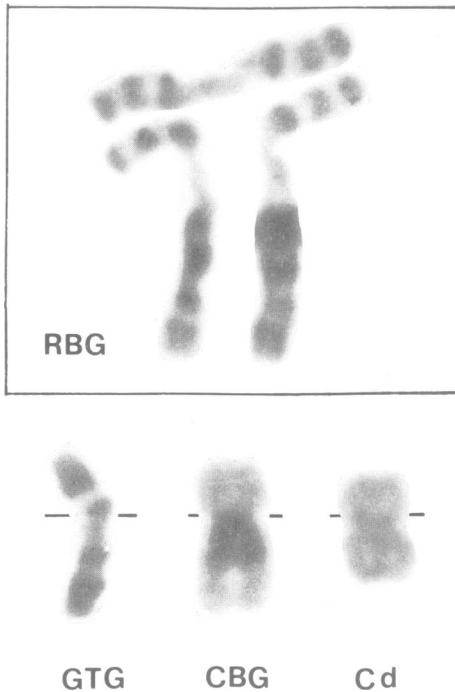

FIG 2 (Top) Two normal and one abnormal chromosomes 9 (RBG banding). (Bottom) Cytogenetic details of abnormal chromosome 9 (GTG, CBG, and Cd banding).

Beutler's method³ and showed a GALT excess (35.18 IU/g Hb at 37°) which, compared with the midparent value (16.78 IU/g Hb), demonstrated in the patient a tetraplex gene dosage effect (2.09).

Discussion

Tetrasomy 9p has been previously reported in nine patients.¹⁻¹¹ Table 1 shows the general data and cytogenetic findings of all subjects reported so far.

The most common clinical features described in eight out of the nine previously published papers are summarised and compared with those of our patient in table 2. The case of Eydoux *et al*⁹ has been excluded because the phenotype was not described. From this comparison it appears that tetrasomy 9p syndrome is a severe malformation syndrome generally showing the following: moderate to severe psychomotor retardation, normal to mildly deficient growth, wide open sutures and fontanelles, hydrocephalus, moderate hypertelorism, epicanthic folds, strabismus, enophthalmos, bulbous nose, protruding and malformed ears, high arched palate or cleft lip

TABLE 1 General data and cytogenetic findings in tetrasomy 9p.

Present patient	Ghymers <i>et al</i> ¹	Rutten <i>et al</i> ²	Oryx <i>et al</i> ⁵	Abe <i>et al</i> ⁶	Wisniewski <i>et al</i> ⁷	Moediono <i>et al</i> ⁸	Eydoux <i>et al</i> ⁹	Ciocco <i>et al</i> ¹⁰	Garcia-Cruz <i>et al</i> ¹¹
Parental age (M/F)	38/36	31/32	25/25	35/38	33/35	19/24	30/31	32/34	
Duration of pregnancy	Term	Term	Term	Term	Term	Term	Term		Term
Delivery	Normal	F	F	M	Normal	Normal	M	F	Normal
Sex	M	F	F	M	M	M	M	F	F
Birth weight (g)	3200	3400	2290	2900	1600	2600	2800	2500	2600
Length (cm)			46.5		43	33.5	35		30
Head circumference (cm)			30.5		27	+	+	+	+
Neonatal asphyxia			+	3 yr	+	+	At birth	+	+
Age at examination	12 yr 7 mth	6 yr	16 mth	+	At birth	4 d	At birth	1 yr	13 yr 9 mth
Survival	+	+	+	+	Few hours	2 mth	+	+	+
Karyotype*	46,XY/47,XY,+i(9)(pter→q12→pter)	46,XX/47,XX,+i(9)	47,XX,+i(9)(pter→cen→pter)	47,XX,+dic(q2101)	47,XY,+t(dic(9;9)(q22;q22))	47,XY,+i(9p)	47,XY,(9p)	47,XX,+i(9p)	47,XX,+i(9p)
Lymphocytes	46,XY	46,XX	46,XX/47,XX,+i(9)(pter→cen→pter)	46,XX/47,XX,+i(9)(pter→cen→pter)	46,XX/47,XX,+i(9)(pter→cen→pter)	46,XX	46,XX	46,XX	46,XX
Skin									

*As described by the authors.

TABLE 2 Comparison of clinical findings.

Clinical findings	Tetrasomy 9p*		Trisomy 9p
	Present patient	All cases	Review of 90 cases†
Psychomotor retardation	+	9/9	
Wide open sutures and fontanelles	+	5/9	
Hydrocephalus	+	5/9	1/90
Microcephaly	+	3/9	
Antimongoloid slants	+	2/9	
Moderate hypertelorism	-	7/9	
Strabismus	-	4/9	
Enophthalmos	+	4/9	
Epicanthic folds	+	5/9	
Bulbous/beaked nose	+	7/9	
Protruding and malformed ears	-	4/9	
Cleft lip/palate	-	3/9	5/90
Downward slanting mouth	+	4/9	
Microretrognathia	+	4/9	
Short neck	-	6/9	
Widely spaced nipples	-	3/9	
Cryptorchidism	-	2/5	
Dysplastic fingernails	+	4/9	
Single palmar crease	-	4/9	
Absence of fusion of C triradius	-	3/9	
Clinodactyly of fifth finger	-	4/9	
Congenital heart disease	+	6/9	
Skeletal anomalies	+	8/9	3/90
Renal anomalies	+	2/9	1/90

*Reported in at least two cases.

†From Baccichetti *et al.*¹²

or palate, downward slanting mouth, microretrognathia, short neck, single palmar crease, clinodactyly of the fifth finger, dysplastic fingernails, congenital heart disease, and skeletal and urogenital anomalies. Several anomalies of the face, hands and skeleton¹¹ are common to both tetrasomy and trisomy 9p and these findings substantiate their phenotypical resemblance. Nevertheless, tetrasomy 9p can easily be differentiated because it is most frequently associated with severe congenital defects (hydrocephalus, cleft lip/palate, congenital heart disease, renal anomalies) which are very rare in the trisomic state (see table 2).

The clinical differences among tetrasomic patients may be the result of a different genetic background and chromosomal involvement (including a small euchromatic segment of the long arm of chromosome 9 in two cases^{6,7}) as well as a variable occurrence of mosaicism.

The mortality rate is high in the first year of life (33% of the cases) and most probably this syndrome is viable only in the mosaic state. In fact mosaicism was present in the peripheral blood in two instances (our case and that of Rutten *et al.*⁴) and it was found in three additional patients in which two different tissues had been examined.^{1,5,10}

For this reason exhaustive cytogenetic analysis

including skin fibroblasts should be performed in all patients with an apparently lymphocytic homogeneous tetrasomy 9p.

Our patient showed a tetraplex gene dosage effect for galactose-1-P-uridylyltransferase (GALT). This result confirms the GALT locus assignment on the short arm of chromosome 9. It also shows that the GALT assay can be very helpful in supporting the cytogenetic diagnosis of 9p aneuploidy. However, the GALT excess does not seem to be responsible for the phenotype in this syndrome.

We are grateful to Dr G Novelli, Department of Human Genetics, University of Urbino, Italy, for the enzyme assay and to Mr A Schianchi for his valuable technical assistance.

References

- Ghymers D, Hermann B, Distèche C, Fredric J. Tétrasyomie partielle du chromosome 9, à l'état de mosaïque, chez un enfant porteur de malformations multiples. *Humangenetik* 1973;**20**:273-82.
- Greulich WW, Pyle SI. *Radiographic atlas of skeletal development of the hand and wrist*. Stanford: Stanford University Press, 1970.
- Beutler E. *Red cell metabolism. Manual of biochemical methods*. New York: Grune and Stratton, 1975:411-4.
- Rutten FJ, Scheres JMJC, Hustinx TWJ, ter Haar BGA. A presumptive tetrasomy for the short arm of chromosome 9. *Hum Genet* 1974;**25**:163-70.
- Orye E, Verhaaren H, van Egmond H, Devloob-Blancquaert A. A new case of the trisomy 9p syndrome. *Clin Genet* 1975;**7**:134-43.
- Abe T, Morita M, Kawai K, *et al.* Partial tetrasomy 9 (9pter 9p2101) due to extra isodicentric chromosome. *Ann Genet (Paris)* 1977;**20**:111-4.
- Wisniewski L, Politis GD, Higgins JV. Partial tetrasomy 9p in a liveborn infant. *Clin Genet* 1978;**14**:147-53.
- Moedjono SJ, Crandall BF, Sparkes RS. Tetrasomy 9p: confirmation by enzyme analysis. *J Med Genet* 1980;**17**:227-30.
- Eydoux P, Junien C, Despoisse S, Chasserot J, Bibring C, Gregori G. Gene dosage effect for GALT in 9p trisomy and in 9p tetrasomy with an improved technique for GALT determination. *Hum Genet* 1981;**57**:142-4.
- Cuoco C, Gimelli G, Pasquali F, *et al.* Duplication of the short arm of chromosome 9. Analysis of five cases. *Hum Genet* 1982;**61**:3-7.
- Garcia-Cruz D, Vaca G, Ibarra B, *et al.* Tetrasomy 9p: clinical aspects and enzymatic gene dosage expression. *Ann Genet (Paris)* 1982;**25**:237-42.
- Baccichetti C, Lenzi E, Temperani P, *et al.* Partial trisomy 9: clinical and cytogenetic correlations. *Ann Genet (Paris)* 1979;**22**:199-204.

Correspondence and requests for reprints to Dr P Balestrazzi, Istituto di Clinica Pediatrica, Università degli Studi di Parma, Via A Gramsci 14, 43100 Parma, Italy.