

Monosomy 8p: an easily overlooked syndrome

A H J T BRÖCKER-VRIENDS*§, P D MOOIJ*†, F VAN BEL‡, G C BEVERSTOCK§, AND J J P VAN DE KAMP*†

From the Departments of Clinical Genetics, Pediatrics†, Neonatology‡, and Human Genetics§, University of Leiden, The Netherlands.*

SUMMARY Two patients with partial monosomy of the short arm of chromosome 8 are described. Their clinical features were very similar. Comparison with previously reported patients confirms the existence of an 8p- syndrome. The importance of cytogenetic investigations in all infants with major congenital heart defect and facial dysmorphism or microcephaly or both is stressed.

Since the publication of the first case report of partial monosomy of the short arm of chromosome 8 by Lubs and Lubs in 1973,¹ eight more patients have been described.¹⁻⁹ There are many common features, particularly in younger patients, indicating the existence of an 8p- syndrome. We describe two more patients with partial monosomy of 8p in whom at first a chromosomal abnormality was not considered.

Case reports

CASE 1

A girl was born at term after an uneventful pregnancy to a 38 year old gravida 2, para 1 mother; birth weight 2600 g, length 47 cm, head circumference 30 cm (all <10th centile). Soon after birth she became cyanotic and a systolic murmur was noticed. Cardiac catheterisation revealed tetralogy of Fallot with double outlet right ventricle and a left sided superior vena cava.

At the age of 3 years she was referred for chromosome studies because of craniofacial dysmorphism and psychomotor retardation. Physical examination revealed length, weight, and head circumference to be well below the 10th centile. There was a prominent occiput, small facies with narrow prominent forehead, hypertelorism, narrow upward slanting palpebral fissures, short stubby nose, thin mouth, ogival palate, and irregularly implanted teeth. Ears were low set and malformed. Nipples were wide set and hypoplastic. Bilateral inguinal herniae were present. Extremities showed cubitus valgus, long small fingers, irregularly placed

toes with the second overriding the third, and hypoplasia of the fifth toe. The child died of cardiac failure at the age of 5 years.

CASE 2

A girl was born at term after a normal pregnancy to a 31 year old gravida 2, para 0 mother; birth weight 1930 g, length 45 cm (<10th centile). After three days her condition deteriorated and she was transferred to our neonatal intensive care unit for evaluation and treatment. Physical examination revealed a slightly dysmorphic facies with narrow, upward slanting palpebral fissures, short stubby nose, retrognathia, low set ears with sparsely curved helix, and a head circumference of 31 cm (<10th centile). Both hands had a low inserted thumb with overlap of the first finger over the second and of the fifth over the fourth. She had rocker bottom feet with a sandal gap, short first toes, and hypoplastic toenails. A loud, rough systolic murmur was heard. Echocardiography indicated a persistent ductus arteriosus and a large ventricular defect. Because of these multiple defects a chromosomal analysis was performed. An *E coli* sepsis was treated with antibiotics. However, her condition deteriorated rapidly and she died on the tenth day. At necropsy hypoplasia of the brain was found. The heart defect consisted of a complete AV canal with a monoatrium and double outlet right ventricle, persistent ductus arteriosus, and left superior vena cava.

CYTOGENETIC INVESTIGATIONS

Orcein stained chromosome preparations of case 1 revealed a partial monosomy of the short arm of chromosome 8. Although the chromosomes were unbanded, it was clear that approximately half of the short arm was missing. G banded chromosomes

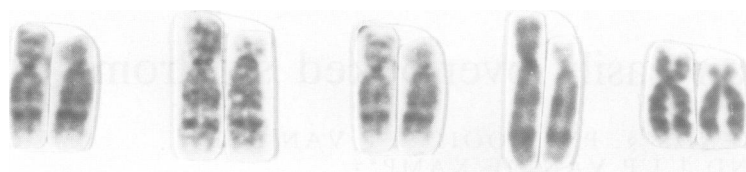


FIGURE G banded chromosomes 8 of patient 2.

of case 2 revealed partial monosomy of the short arm of chromosome 8, defined as 46,XX,del(8)(pter→p21) (figure). The parents of both patients had a normal karyotype.

Discussion

The phenotypic abnormalities of case 1 are strikingly similar to those of the patients described by Leisti and Aula² and Reiss *et al.*³ In particular, the similarity of the facies is remarkable including delicate features with narrow forehead, narrow palpebral fissures, short stubby nose, and thin lips. These facial abnormalities seem to become less evident with age, as demonstrated by the patient of Orye and Craen,⁴ explaining why older patients have a less characteristic facies.⁵⁻⁷ Only the patient described by Beighle *et al.*⁸ is dissimilar, probably because a different segment of the short arm of chromosome 8 was involved.

The clinical findings in our patients and in the previously reported patients are summarised in the table. Since the phenotypic expression of monosomy 8p might be influenced by a simultaneous imbalance of another chromosome segment, the patients in whom the monosomy 8p was due to an unbalanced translocation^{1,9} are excluded. Apart from the facial features, the most common clinical findings were

postnatal growth retardation, moderate or severe mental retardation, microcephaly, dysplastic ears, widely set nipples, and major cardiac defect. Although most of these features are non-specific, the combination of microcephaly, congenital heart defect, and delicate facies indicates a distinctive phenotype associated with monosomy 8p. As demonstrated in our two patients, facial dysmorphism and microcephaly can easily be overlooked in infants with a severe congenital cardiac defect. We regard the combination of these defects as a strong indication for chromosome analysis. Although in most of the patients monosomy 8p resulted from a de novo deletion, cytogenetic investigation in the parents is recommended to exclude a familial translocation with a higher risk for unbalanced progeny.

References

- Lubs HA, Lubs ML. New cytogenetic technics applied to a series of children with mental retardation. In: Casperson T, Zech L, eds. *Chromosome identification technique and application in biology and medicine*. Nobel Symposia 23. New York, London: Academic Press, 1973:241-50.
- Leisti J, Aula P. A case of deletion of the short arm of chromosome 8. *Birth Defects* 1977;XIII(3b):187-94.
- Reiss JA, Brenes PM, Chamberlin J, Magenis RE, Lovrien EW. The 8p- syndrome. *Hum Genet* 1979;47:135-40.
- Orye E, Craen M. A new chromosome deletion syndrome. Report of a patient with 46,XY, 8p- chromosome constitution. *Clin Genet* 1976;9:289-301.
- Bresson JL, Noir A, Scherrer M. Délétion partielle du bras court du chromosome 8. *Ann Genet (Paris)* 1977;20:70-2.
- Rodewald A, Stengel-Rutkowski S, Schulz P, Cleve H. New chromosomal malformation syndromes. I. Partial monosomy 8p. An attempt to establish a new chromosome deletion syndrome. *Eur J Pediatr* 1977;125:45-85.
- Taillemite JL, Channaronod J, Tinel H, Mulliez N, Roux C. Délétion partielle du bras court du chromosome 8. *Ann Genet (Paris)* 1975;18:251-5.
- Beighle C, Karp LE, Hanson JW, Hall JG, Hoehn H. Small structural changes of chromosome 8. *Hum Genet* 1977;38:113-21.
- Guanti G, Mollica G, Polimeno L, Maritato F. rDNA and acrocentric chromosomes in man. I. rDNA levels in a subject carrier of a 8p/13p balanced translocation and his unbalanced son. *Hum Genet* 1976;33:103-7.

TABLE Clinical findings in patients with partial monosomy 8p.

Clinical findings	Reported patients	Case 1	Case 2	All patients
Antenatal growth defect	3/7	-	+	4/9
Postnatal growth defect	5/7	+		6/8
Mental retardation	7/7	+		8/8
Microcephaly	5/7	+	+	7/9
Narrow forehead	6/7	+	-	7/9
Prominent occiput	2/4	+	-	3/6
Narrow palpebral fissures	5/7	+	+	7/9
Epicanthus	5/7	-	-	5/7
Short stubby nose	3/7	+	+	5/7
Thin mouth	4/7	+	-	5/9
Ogival palate	3/4	+	-	4/6
Retrogathia	4/7	-	+	5/9
Dysplastic ears	5/7	+	+	7/9
Widely set nipples	5/5	+	-	6/7
Cardiac defect	4/7	+	+	6/9

Correspondence and requests for reprints to Dr A H J T Bröcker-Vriends, Centre for Clinical Genetics, University Hospital of Leiden, Rijnsburgerweg 10, 2333 AA Leiden, The Netherlands.